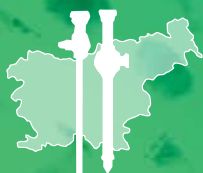

# **SURGERY** **and** **SURGICAL** **ENDOSCOPY**

Vol. 3, No. 1, Jan. 2021

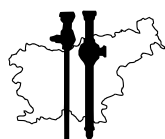
Official Journal of the Slovenian Society for Endoscopic Surgery





# Surgery and Surgical Endoscopy

Official Journal of the Slovenian Society for Endoscopic Surgery



Slovenian Society  
for Endoscopic Surgery

Surgery and Surgical Endoscopy is a fully open access, peer-reviewed journal that aspires to publish articles relevant to surgery, surgical oncology as well as surgical endoscopy from researchers worldwide. The journal accepts review articles, research articles, case reports, letters to the editors, study protocols and "How I do it" submissions.

## Editors-in-Chief

*Tomaž Jagrič, Jan Grosek*

## Editorial Board

*Matej Cimerman, Vojko Flis, Štefan Grosek, Tine Hajdinjak, Simon Hawlina, Bojan Krebs, Gregor Norčič, Peter Popovič, Stojan Potrč, Tomaž Smrkolj, Tomaž Štupnik, Aleš Tomažič, Blaž Trotovšek*

## Technical Editor

*Hana Zavrtanik*

## Publisher

*Slovenian Society for Endoscopic Surgery*

## Address of the Editorial Office and Administration

*Zaloška cesta 7, 1000 Ljubljana, E-mail: [info@zeks.si](mailto:info@zeks.si)*

## Reader for English

*DEKS, d.o.o.*

## Layout

*Jan Grosek*

## Graphic design

*GALdesign*

## Printed by

*Tiskarna Januš, Ljubljana*

## Issue frequency

*2 issues/year*

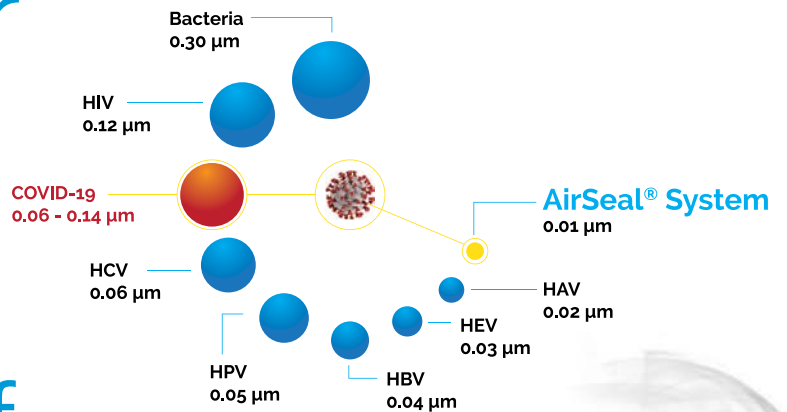
## Circulation

*150*

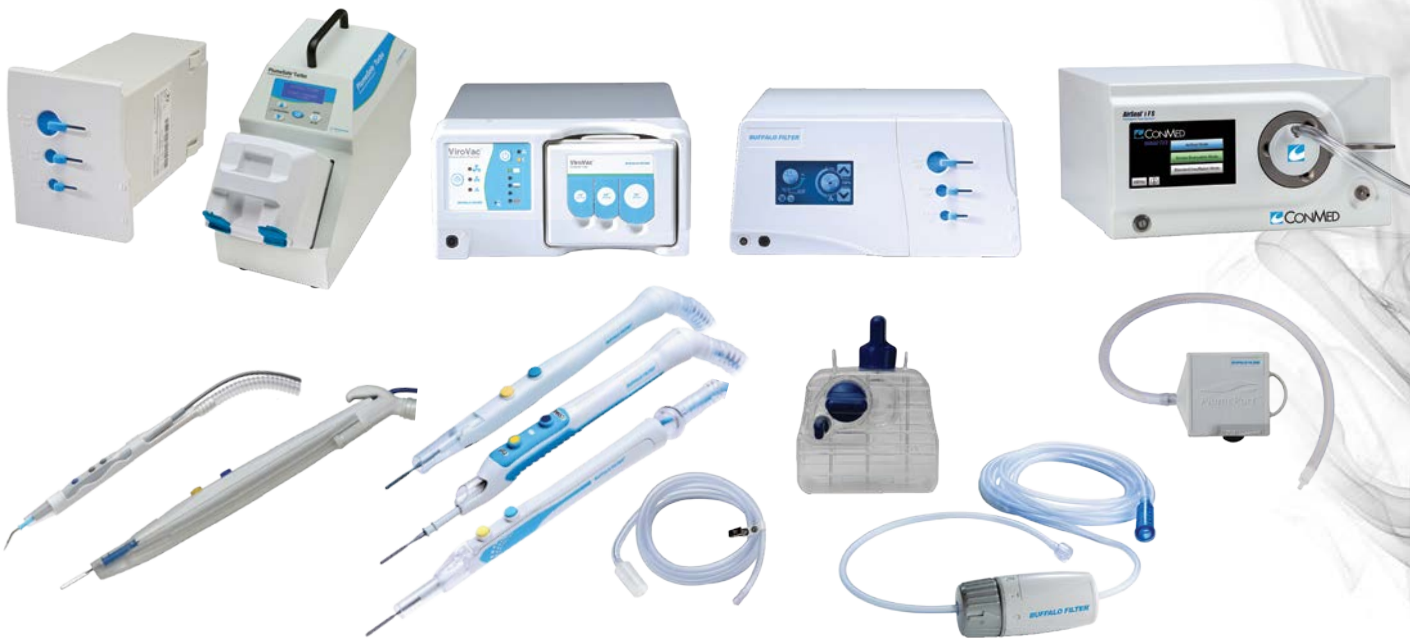## Indexed and/or abstracted

*Digitalna knjižnica Slovenije (dLib)*

# Protect your patients, your staff and yourself



There are dangers in Surgical Smoke Plume  
**Together, we can help eliminate them**



The broadest, most advanced, and complete product portfolio for Surgical Smoke Plume Evacuation and Filtration

➤ The **LEADER** in Surgical Smoke Management

Endosurgical | Šmartinska cesta 152, 1000 Ljubljana  
 dsemrov@endosurgical.si | +386 41 799 123

# Contents

## RESEARCH ARTICLES

---

- 7** **The Impact of COVID-19 on Surgical Residency Programs at the Ljubljana University Medical Center**  
Žan Čebren, Aleš Tomažič
- 13** **The Value of Bridging Self-expandable Stents in Resectable Obstructive Colorectal Carcinoma**  
Bojan Krebs, Tomaž Jagrič

## CASE REPORTS

---

- 21** **Management of Open Abdomen after Trauma Laparotomy with an Abdominal Reapproximation Anchor System in Conjunction with Negative-Pressure Wound Therapy: A Case Report With a Review of the Literature**  
Jurij Aleš Košir, Jan Grosek, Aleš Tomažič
- 27** **A Rare Case of Mixed Epithelial and Stromal Tumor of the Kidney Managed by Robot-Assisted Laparoscopic Partial Nephrectomy**  
Klemen Lovšin, Simon Hawlina
- 33** **Endoscopic Submucosal Dissection as a Treatment for Early Gastric Cancer: A Case Report**  
Martin Zaplotnik, Sebastian Stefanović, Samo Plut, Luka Strniša, Aleksandar Gavrić

## HOW I DO IT

---

- 39** **How I Do It: Laparoscopic Gastrectomy for Gastric Adenocarcinoma Using the Livsmed® Surgical System**  
Tomaž Jagrič
- 45** **Laparoscopic Living Donor Nephrectomy: Description of a Transabdominal Approach and Our Experience at the Ljubljana University Medical Center**  
Milena Taskovska, Simon Hawlina
- 53** **Single Anastomosis Duodeno-Ileal Bypass with Sleeve Gastrectomy: A “New” Bariatric Surgery, Presentation of the Surgery, and Our Experiences with the First Cases**  
Barbara Rožej, Gregor Kunst, Jure Kovač Myint, Brane Breznikar
- 59** **Minimally Invasive Non-Endoscopic Intracerebral Hematoma Evacuation: An Illustration of the Operative Method**  
Tomaž Velnar

## STUDY PROTOCOLS

---

- 67** **Ileocecal Valve Syndrome and Vitamin B12 Deficiency After Right Hemicolectomy: A Study Protocol**  
Jurij Janež



# Editorial

**Blaž Trotovšek**, *President of the WEB IHPBA chapter*

## CORRESPONDENCE

Asst. Prof. **Blaž Trotovšek**, MD, PhD  
blaz.trotovsek@kclj.si

Dear Colleagues,

It is my honor to present the fifth issue of *Surgery and Surgical Endoscopy*. I am especially pleased because several articles published in this issue show that surgery in Slovenia continues to keep in step with innovations and trends in cutting-edge medicine around the world.

Open abdomen management in trauma is an old story, but with many unresolved problems that we encounter in our patients. These problems deserve continuous development of new techniques and approaches to achieve optimal results of this life-saving treatment in severely injured or ill patients. Trauma can affect anyone, but the younger and fitter population more often requires a laparotomy for trauma than older people, who require an expedient laparotomy for other diseases. In trauma, damage-control laparotomy is a well-established technique with two basic components: control of bleeding and contamination in the abdominal cavity, and leaving the abdomen open to decompress and/or facilitate return at planned re-laparotomy. In non-military trauma, one-third of patients undergoing a trauma laparotomy have damage control, rather than a definitive laparotomy. This aims to preserve and restore the physiological reserves of the severely injured first and only later to restore anatomical congruity. Delaying closure facilitates abdominal re-exploration and mitigates the development of intraabdominal hypertension and abdominal compartment syndrome. Mortality rates are high in developed abdominal compartment syndrome, usually over 30%, but depending on the patient cohort this can even reach up to 100% if left untreated. Delaying fascial closure until after the visceral injuries have been definitively managed plays a key role in damage control laparotomy. However, in only two-thirds of these patients is delayed primary fascial closure (DPFC)—apposition of fasciae—achievable. The duration of an open abdomen treatment is one of the most important prognostic factors affecting restoration of abdominal continuity. Open abdomen management longer than 8 days reduces the chance of DPFC and increases the incidence of significant abdominal complications such as entero-atmospheric fistulae and abdominal wall loss. Maintaining the abdomen domain requires a temporary abdominal closure.

Prevention of lateralization and fixation of the abdominal wall is of paramount importance. Negative-pressure-mediated temporary abdominal closure has become the technique most often used in the last 10 years. When combined with the “shark fin” technique described by Hougaard in the 1<sup>st</sup> week and later with “mesh mediated traction” promoted by Petersson and numerous other authors, this leads to one of the highest rates (76%) of DPFC in nonselected patients, and in selected groups even up to 90%, with the lowest complication rates among temporary abdominal closure techniques.

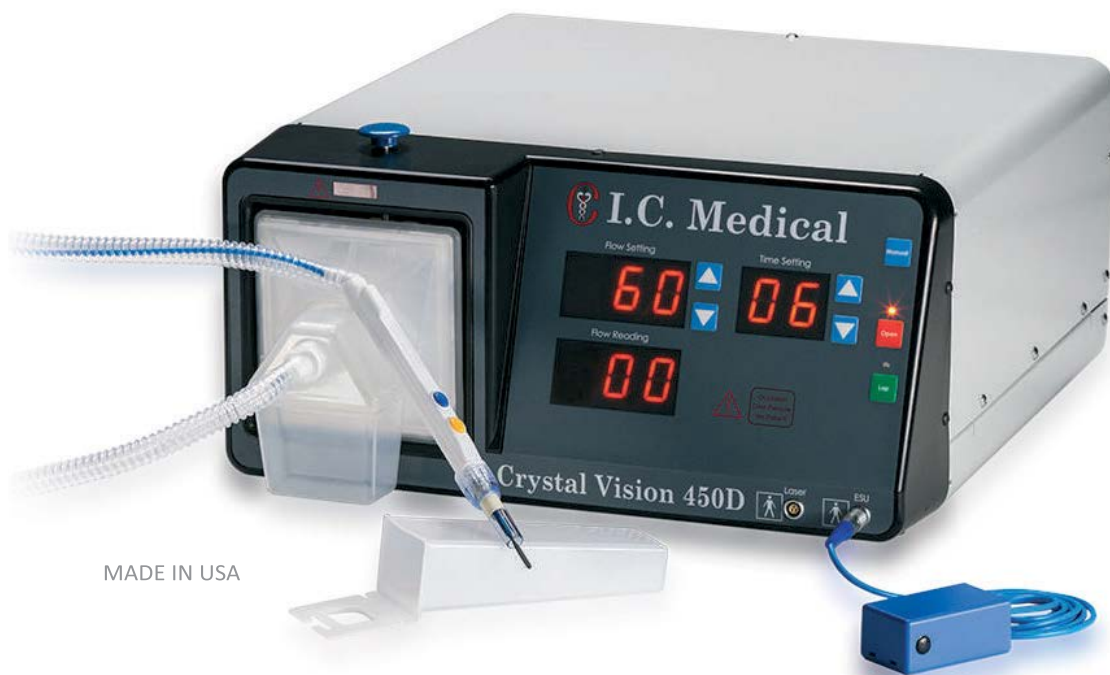Loss of abdominal wall in trauma is an unusual condition following penetrating or blast injuries caused by high-velocity military weapons and avulsion injuries in traffic accidents. Sometimes it is a consequence of extensive surgical debridement in necrotizing fasciitis following trauma to the abdominal wall. The abdomen is of necessity open and requires temporary abdominal closure until it is possible to reconstruct the wall. An innovative approach designed to restore the lost abdominal domain and achieve closure of large abdominal wall defects using a continuous dynamic tension device called the abdominal reapproximation anchor (ABRA) system (Canica Design, Almonte, Ontario, Canada) is a promising technique that can help prevent the development of large posttraumatic hernias. The article “Management of open abdomen after trauma laparotomy with an abdominal reapproximation anchor system in conjunction with negative pressure wound therapy: a case report with a review of the literature” by Košir et al. describes this contemporary approach. Timely decision-making, excellent surgical technique and intensive care, and premeditated use of alternative modern techniques supported by technical innovations led to survival, full recovery, and return to the everyday life for this severely injured patient.

In conclusion, I would like to emphasize the importance of publishing reports on exceptional cases backed up with evidence available from the literature. Although the level of evidence will always be considered low, in such cases randomized control trials will never be available. The current issue presents up-to-date knowledge and experience that can be helpful for every surgeon dealing with these severely ill patients. Last but not least, we should always remember the old adage: “A failure to plan is a plan to fail!”



## Crystal Vision 450D

The most sophisticated surgical smoke evacuation and filtration system



MADE IN USA



COVID-19 Risk Prevention

- SAFEGUARD BLUE™ Hydrophobic ULPA Filter delivers >99.9999% efficiency on all particle sizes down to 0.03 micron, including all SARS-CoV-2 particles
- Indicator alerts OR staff when the ULPA filter with built-in fluid trap is not capturing at 100% and needs to be changed
- Automatically operates with all surgical cutting devices, including ultrasonic devices, ESU monopolar, bipolar, and lasers in both modes open and laparoscopic
- Made with a quiet, reliable, brushless high quality rotary vein pump motor



# The Impact of COVID-19 on Surgical Residency Programs at the Ljubljana University Medical Center

Žan Čebtron, Aleš Tomažič

Department of Abdominal Surgery, Ljubljana University Medical Center

## CORRESPONDENCE

Žan Čebtron, MD  
zan.cebron@kclj.si

## KEY WORDS

COVID-19, pandemics, epidemic, surgical residents

## RESEARCH ARTICLE

SURGERY SURG ENDOS 2021; 3(1):  
7-12

## Abstract

**Background:** The increasing number of COVID-19 patients admitted to the hospital has caused drastic changes in the organization of work at our hospital, with the majority of elective surgery procedures being canceled due to the situation. As an undesirable consequence of these necessary adjustments, the hands-on education of surgical residents has been affected. This study evaluates the impact of COVID-19 on surgical residency programs.

**Methods:** An anonymous online survey was sent via e-mail to all 68 surgical residents on January 4<sup>th</sup>, 2021 and was left open for 6 days. Completion of the survey was voluntary, and anonymity was ensured by not requiring entry of any personal data. However, the residents' age, sex, and surgical field were asked to exclude multiple entries by the same resident. A list of questions was generated to offer insight into the effects that COVID-19 has had on residents' work: how frequent CoV-SARS-2 infection was among the residents, the most probable place of infection, whether residents had always been offered appropriate personal protection equipment, what the residents' greatest fears were, and—most importantly from the educational point of view—how many surgical procedures they had been able to perform during the COVID-19 epidemic.

**Results:** Over the 6-day collection period, a response rate of 53% (36/68 surgical residents) was achieved. Both male (69%; 25/36) and female (31%; 11/36) surgical residents participated in our online survey. Less than half of the participants felt they had always been offered appropriate personal protective equipment (42%; 15/36). The residents' greatest fear during the epidemic was concern about transmitting COVID-19 to their families (94%; 34/36). Approximately one-third of the participants had had a confirmed SARS-CoV-2 infection before December 31<sup>st</sup>, 2020 (31%; 11/36). Due to the epidemic, 25/36 residents (69%) had had to change the clinical rotation of their residency within the first wave and return to their preassigned wards. During the second wave, the number of residents changing their residency program was significantly lower (19%; 7/36); one surgical

resident had been assigned to the COVID-19 department. Only a quarter of the participants (9/36) stated that they had managed to perform the expected number of surgical procedures despite the epidemic.

**Conclusion:** The COVID-19 outbreak has affected surgical residency programs dramatically. The residents generally performed fewer surgical procedures than expected, the residency programs were changed, and a significant number of the residents had been infected. Based on the literature and our study's individual approach, the evaluation of each resident's skills is advised.

## Introduction

The rapid spread of COVID-19 across the world resulted in the declaration of a pandemic by the World Health Organization on March 11<sup>th</sup>, 2020 (1). The following day, the Slovenian government also declared an epidemic. Due to the rapidly increasing number of COVID-19 patients being treated at the Ljubljana University Medical Center and many of the medical staff being on sick leave or in quarantine, there has been a drastic change in the organization of work at our hospital, with the majority of elective surgery procedures being canceled due to the situation. Because of COVID-19, changes have been made to the planned clinical rotations of our surgery residents—initially during the first wave of the epidemic in spring 2020, and then during the second wave, which officially started on October 19<sup>th</sup> and is still in progress at the time of writing this article.

As an undesirable consequence of these necessary adjustments, the hands-on education of surgical residents has probably been affected. Some of the residents had been selected to help at COVID-19 departments where almost no surgical procedures were being performed. Other residents returned to their preassigned departments, where a significant number of elective procedures had also been canceled.

Our study evaluates the educational and personal concerns of surgical residents during the first and second waves of the COVID-19 epidemic.

## Methods

A list of questions was generated to obtain insight into the effects COVID-19 has had on residents' work: how frequent CoV-SARS-2 infection was among the residents, the most probable place of infection, availability of appropriate personal protection equipment, what the residents' greatest fears were, and—most importantly from the educational point of view—how many surgical procedures they had been able to perform during the COVID-19 epidemic. The online survey consisted of several questions, mostly short multiple-choice items; there were a few questions with several possible answers, or with an expected explanatory answer (Figure 1). The survey took 5 to 10 minutes to complete.

An anonymous online survey was sent via e-mail to all 68 surgical residents at the Ljubljana University Medical Center on January 4<sup>th</sup>, 2021. The online survey then closed on January 10<sup>th</sup>, 2021. To improve the response rate, an additional reminder to complete the survey was sent on January 8<sup>th</sup>, 2021.

Completion of the survey was voluntary, and anonymity was ensured by not requiring entry of any personal data. However, the residents' age, sex, and surgical field were asked to exclude multiple entries by the same resident.

## Results

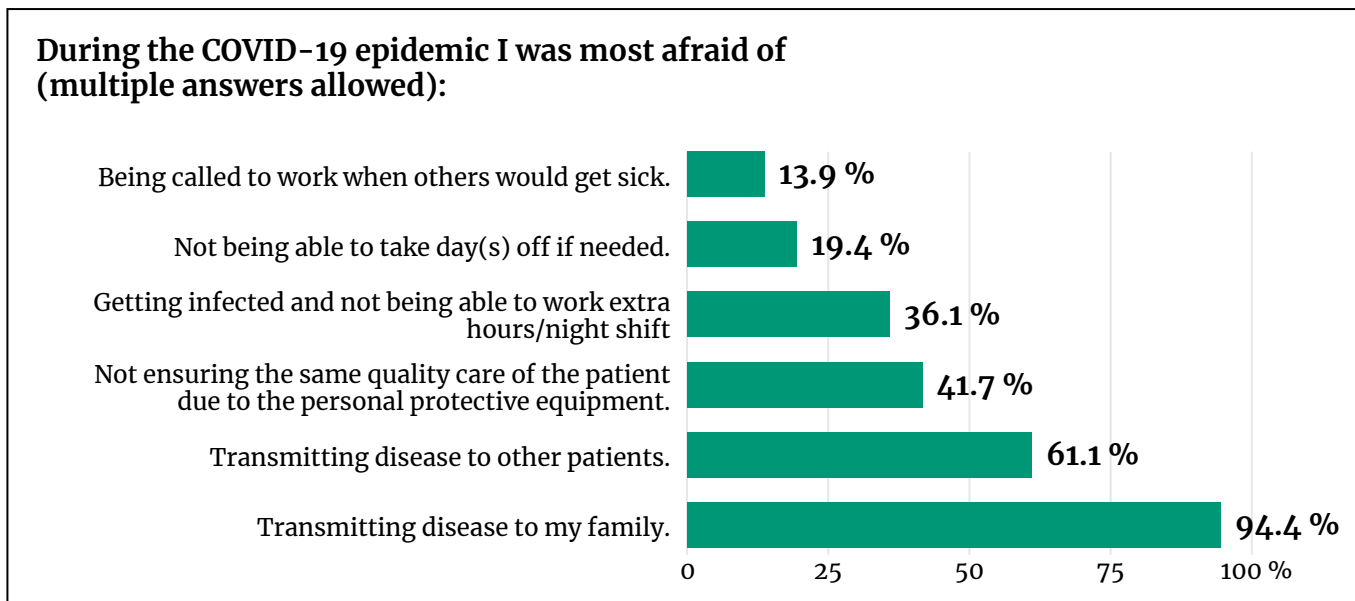
Over the 6-day collection period, a response rate of 53% (36/68 surgical residents) was achieved. Both male (69%; 25/36) and female (31%; 11/36) surgical residents participated in our online survey. The age of the participants ranged from 27 to 36 years, the average being 30 years. Most answers were received from general, abdominal, plastic surgery, and traumatology residents.

Fewer than half of the participants felt that they had always been offered appropriate personal protective equipment (42%; 15/36). Most of the participants (58%; 21/36) had at some point during the epidemic not been able to protect themselves (53% or 19/36 during the first wave, and 31% or 11/36 during the second wave).

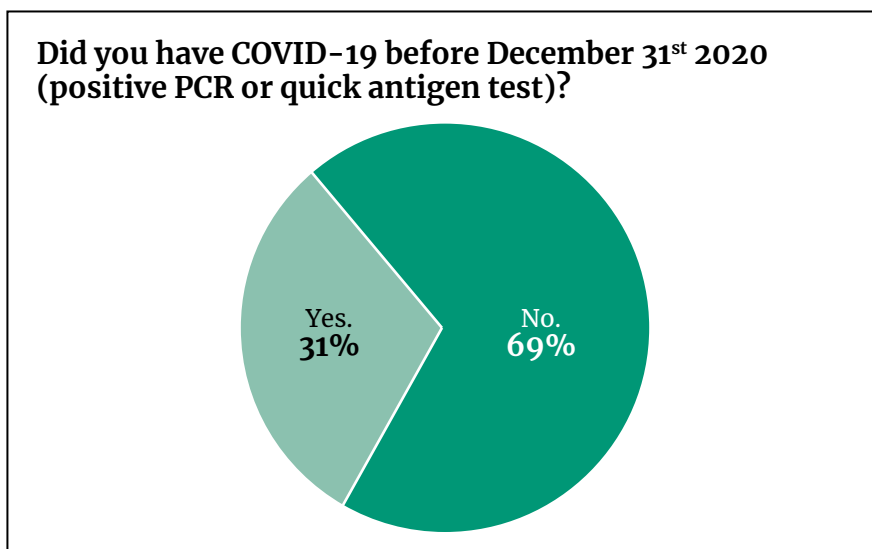
The residents' greatest fear during the epidemic was the concern of transmitting COVID-19 to their

**Figure 1.** List of questions and choices from the online survey.

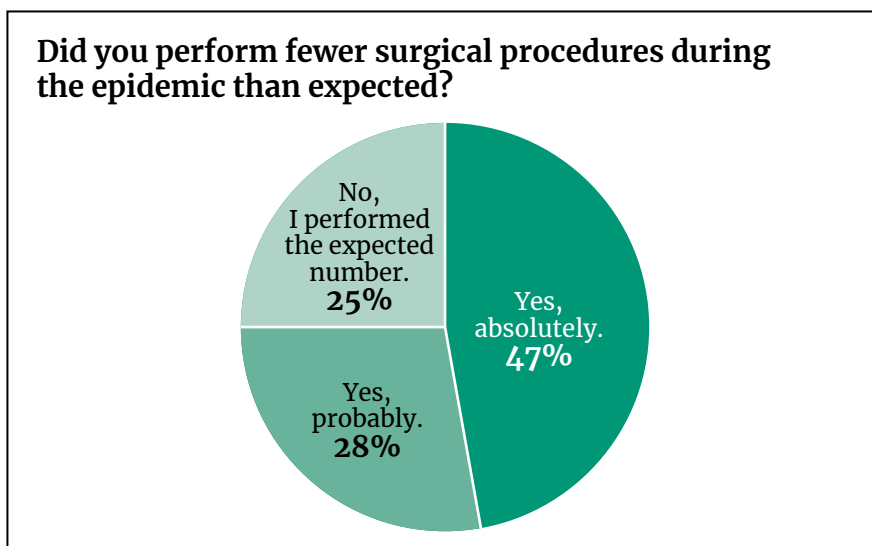
1. **Age**
2. **Sex**
3. **Field of residency**
  - a. Traumatology
  - b. Abdominal surgery
  - c. Urology
  - d. Thoracic surgery
  - e. Cardiovascular surgery
  - f. General surgery
  - g. Neurosurgery
  - h. Plastic surgery
  - i. Pediatric surgery
4. **Were you always offered appropriate personal protective equipment?**
  - a. Yes, always.
  - b. No, in the first wave I was not always able to protect myself sufficiently.
  - c. No, in the second wave I was not always able to protect myself sufficiently.
  - d. No, in both waves I was not always able to protect myself sufficiently.
5. **During the COVID-19 epidemic I was most afraid of (multiple answers allowed):**
  - a. Transmitting disease to other patients
  - b. Transmitting disease to my family
  - d. Not ensuring the same quality of care for patients due to personal protective equipment
  - e. Being infected and not being able to work extra hours / night shift / on-call shift
  - f. Not being able to take day(s) off if needed
  - g. Being called to work if others became sick
6. **Did you have COVID-19 before December 31<sup>st</sup>, 2020 (positive PCR or quick antigen test)?**
  - a. Yes
  - b. No
7. **Days absent due to COVID-19 infection or days absent due to high-risk contact quarantine:**
  - a. Less than 10 days
  - b. 11–14 days
  - c. 15–21 days
  - d. More than 21 days
8. **The most probable place where you got COVID-19:**
  - a. At work
  - b. At home
  - c. Private gathering, private parties
  - d. Other
9. **Were you vaccinated before December 31<sup>st</sup> or prior to completing this survey?**
10. **Was your residency program changed during the first wave?**
11. **Was your residency program changed during the second wave?**
12. **Did you perform fewer surgical procedures during the epidemic than expected?**
13. **Did you find online lectures useful?**
  - a. Yes, I prefer online lectures.
  - b. Yes, but I prefer live lectures.
  - c. No, I do not like online lectures.
14. **Were there enough online lectures during the epidemic?**
  - a. Yes
  - b. No
15. **Will you postpone taking the medical board exam due to the epidemic?**
  - a. No
  - b. Yes, I will attend the medical board exam later.
  - c. Yes, I postponed the medical board exam due to the epidemic.



**Figure 2.** Residents' greatest fears.



**Figure 3.** COVID-19 among surgical residents.



**Figure 4.** Effect of the epidemic on the number of surgical procedures performed.

families (94%; 34/36), the concern of transmitting COVID-19 to patients (61%; 22/36), and not ensuring the same quality of care for patients due to personal protective equipment (42%; 15/36). The other answers are presented in Figure 2.

Approximately one-third of the participants were infected with SARS-CoV-2 before December 31<sup>st</sup>, 2020 (31%; 11/36; Figure 3). Nine of them were presumably infected at work (82%; 9/11). All the confirmed infections happened during the second wave; that is, 1/11 in September, 4/11 in November, and 6/11 in December. The remainder of the participants had had a negative test (69%; 25/36). However, 11/25 participants that had not been infected had been in quarantine at some point due to having been exposed to high-risk contacts (31%).

Prior to December 31<sup>st</sup>, none of the residents had been vaccinated against COVID-19. Nevertheless, 10/36 residents (28%) had already been vaccinated with the first dose at the time of answering the online survey.

Due to the epidemic, 25/36 residents (69%) had had to change the clinical rotation of their residency in the first wave and return to their preassigned wards. During the second wave, the number of residents changing their residency program was significantly lower (19%; 7/36); one surgical resident had been assigned to the COVID-19 department.

Only a quarter of the participants (9/36) stated that they had managed to perform the expected number of surgical procedures despite the epidemic. Another quarter thought that they had probably carried out fewer than the expected number of surgical procedures (28%; 10/36). Approximately half (47%; 17/36) were sure that they had performed fewer surgical procedures than expected (Figure 4). Most of the residents found online lectures useful (92%; 33/36). Roughly one-third (31%; 11/36) would have preferred more online lectures. Two of the residents (6%; 2/36) would surely postpone the board exam due to the COVID-19 epidemic.

## Discussion

Our study evaluates the impact of the COVID-19 epidemic on the surgical residency programs at the Ljubljana University Medical Center during the first and second waves. Emphasis was placed on the changes to clinical rotations, the number of surgical procedures performed, and the number of residents infected with the SARS-CoV-2 virus.

As COVID-19 has quickly spread across the world, there has been a major demand for personal protective equipment (PPE), and many countries have faced a lack of appropriate PPE, including Slovenia (2). According to our survey, there was a lack of suitable PPE at some points during the epidemic because 58% of the residents felt they had not been able to protect themselves appropriately. As expected, the percentage was lower during the second wave (31%), when our hospital had anticipated the worsening of the epidemic and had thus had time to secure larger stocks of PPE.

Despite knowledge about how the virus spreads and how PPE should be used, the number of residents infected was not negligible. Approximately one-third of the participants had had a confirmed SARS-CoV-2 infection before December 31<sup>st</sup>, 2020 (31%; 11/36). The problem with the SARS-CoV-2 virus, as already known, is its ability to spread in the very early stage, when someone is asymptomatic (3). The majority of residents stated they had been infected at work (82%), which is interesting because healthcare workers are supposed to wear PPE all the time during work. The potential risk situations are communal dining in the cafeteria and the breakrooms, where employees do not wear masks and are close together, which is known to be a high-risk situation for virus transmission (4, 5).

During the COVID-19 epidemic, only emergency and urgent operations were performed at the majority of the surgical departments, meaning that surgical departments had an enormous decrease in the operations carried out. Many articles have been published stating that residents operated significantly less than expected (6, 7). In our survey, we also noticed the same problem. Three-quarters of participants stated they had performed fewer surgical procedures than expected (75%; 27/36). Because the epidemic has lasted for almost a year, this is an important finding and may seriously impact each resident's development of hands-on and theoretical skills.



Nevertheless, the number of surgical procedures performed is not the only part of surgical residency education. The literature states that an epidemic may also affect responsibility in patient care, maturation in clinical judgement, and teaching skills (8). At our hospital, many residents had to change their clinical rotation due to the epidemic, but almost all of them remained on surgical wards, and only one resident was transferred to work at a COVID-19 department. Based on these facts, we are not concerned that our residents will lack skills in patient care and clinical judgement due to the epidemic. However, as the literature suggests, an individual approach is advised so that mentors can evaluate the expected skills of each resident, and, based on the findings, additional clinical rotations and/or surgical procedures should be planned.

Nevertheless, our study had several important limitations. The most important limitation was the low response rate of the residents (53%; 36/68), despite the reminder sent to the residents 4 days after the online survey started.

In conclusion, the COVID-19 outbreak has affected surgical residency programs dramatically. During both waves of the epidemic, residents generally performed fewer surgical procedures than expected, the residency programs changed, and a significant number of residents were infected. Based on the literature and our online survey, observations should be considered throughout the remainder of every residency, and an individual mentoring approach is advised.

## References

1. Cucinotta D, Vanelli M. WHO declares COVID-19 a pandemic. *Acta Biomed.* 2020;91(1):157–60.
2. Iacobucci G. Covid-19: doctors still at “considerable risk” from lack of PPE, BMA warns. *BMJ.* 2020;368:m1316.
3. Liu X, Liu C, Liu G, Luo W, Xia N. COVID-19: progress in diagnostics, therapy and vaccination. *Theranostics.* 2020;10(17):7821–35.
4. Setti L, Passarini F, De Gennaro G, Barbieri P, Perrone MG, et al. Airborne transmission route of COVID-19: why 2 meters / 6 feet of inter-personal distance could not be enough. *Int J Environ Res Public Health.* 2020;17(8):2932.
5. Morawska L, Tang JW, Bahnfleth W, Bluysen PM, Boerstra A, et al. How can airborne transmission of COVID-19 indoors be minimised? *Environ Int.* 2020;142:105832.
6. Kogan M, Klein SE, Hannon CP, Nolte MT. Orthopaedic education during the COVID-19 pandemic. *J Am Acad Orthop Surg.* 2020;28(11):e456–64.
7. Amparore D, Claps F, Cacciamani GE, Esperto F, Fiori C, et al. Impact of the COVID-19 pandemic on urology residency training in Italy. *Minerva Urol e Nefrol.* 2020;72(4):505–9.
8. Zheng J, Hundeyin M, He K, Sachs T, Hess DT, et al. General surgery chief residents’ perspective on surgical education during the coronavirus disease 2019 (COVID-19) pandemic. *Surg (United States).* 2020;168(2):222–5.

# The Value of Bridging Self-expandable Stents in Resectable Obstructive Colorectal Carcinoma

**Bojan Krebs, Tomaž Jagrič**

*Department of Abdominal and General Surgery, Maribor University Medical Center*

## CORRESPONDENCE

Asst. Prof. **Bojan Krebs**, MD, PhD  
bojan.krebs@guest.arnes.si

## KEY WORDS

obstruction, colorectal cancer, bridging, self-expandable stent

## RESEARCH ARTICLE

SURGERY SURG ENDOS 2021; 3(1):  
13-20

## Abstract

**Background:** Colonic stent placement of self-expandable metallic stenting is a relatively new method to avoid emergency surgery or ostomy formation in patients with obstructive left colon malignancy. The procedure initially acquired a negative connotation, implying that the patients in which it was used as a bridge to definitive surgery would have the worst oncological results. Those statements were later refuted on the ground of multicenter randomized trials.

**Methods:** We retrospectively evaluated all patients treated for acute sigmoidal obstruction with self-expandable metallic stent insertion as a bridge to surgery between December 2015 and October 2019.

**Results:** During the period observed we inserted eight stents as a bridge to surgery, six of them for rectal obstruction and two for sigmoid obstruction. There were no stent-related early complications, and all patients were decompressed. They were later radically operated on after appropriate neoadjuvant therapy. Four of them were operated on laparoscopically. There were no major complications after surgery. All patients are followed up on a regular basis with no signs of recurrence.

**Conclusion:** We believe that self-expandable metallic stent insertion as a bridge to surgery in patients with acute left colorectal obstruction is a safe and above all patient-friendly method. It relieves the obstruction and gives the patient time for preparation for radical laparoscopic surgery without ostomy.

## Introduction

Colorectal cancer is one of the most common cancers worldwide. According to various sources, 7 to 29% of all patients diagnosed with colorectal carcinoma are operated on in an urgent manner (1). Traditionally, the gold standard for a patient operated on for obstructive cancer of the left colon, especially

of the sigmoid colon and rectum, was Hartmann's procedure (2). Patients usually ended up with a terminal ostomy, which was never converted in a substantial percentage of patients (3, 4).

Alternative treatment for patients with obstructive left colon cancers was performing an ostomy. A new technique emerged in the 1990s. An insertion of self-expandable metallic stents (SEMS) was first introduced as a palliative procedure. It helped patients with left colonic obstruction—who were frequently elderly and had multiple associated diseases—avoid surgery and ostomy (5). Later on, the procedure was also used for younger and healthier patients with a newly discovered obstructive lesion to bridge the time between primary diagnosis and definitive surgery (6). In the meantime, after the SEMS placement, detailed diagnostic procedures could be performed. The patient can have a colonoscopy through the colonic stent, which can help identify coexisting lesions and stage cancer more accurately. In most cases, the obstruction is resolved and patients can start taking food orally and be better prepared for later elective surgery (7).

Initially there was much controversy regarding the procedure. There were concerns about tumor cell seeding during SEMS insertion, especially if there might be a perforation. Multiple randomized controlled trials and meta-analyses were performed, but there were no clear statements about the real usefulness and safety of the procedure (8–10). In light of these findings, the European Society of Gastrointestinal Endoscopy (ESGE) posted guidelines in 2014 in which it stated that SEMS placement as a bridge for obstructive left-sided colonic malignancies is not recommended as a standard treatment (11).

Many surgeons did not agree with this recommendation, especially because of other opinions in eastern countries and especially Japan (12). Further studies and investigations were performed, which encouraged the opinion that colonic stent placement in obstructive colon cancer is at least as good as emergency surgery, if not better. Two of the most prominent were the ESCO trial and CREST trial (7, 13). The aim of this study was to determine the clinical value of bridging stents in patients treated for obstructive colorectal cancer with the intention to heal.

## Methods

### Patients

The documentation of all patients in which SEMS insertion was performed between December 2015 and October 2019 was retrospectively evaluated. Age, sex, tumor distance from the anocutaneous line, and surgical and general complications after stent placement were recorded. Data regarding clinical efficiency and the need for early stent removal were also collected. We were interested in the time between SEMS insertion and colonic resection, TNM classification of the tumor, the need for neoadjuvant treatment, the type of colonic resection, the ratio of ostomy performed, complications after surgery (open or laparoscopic), and tumor regression in patients after radiation therapy.

### Colonoscopy and Stenting

Before stenting, all patients were given a cleansing enema with no additional colon preparation. The procedure was performed under conscious sedation by two surgeons trained in endoscopies. Sedation was achieved with oral midazolam (7.5 mg) 30 minutes before the procedure. During the endoscopy, the patient received a drip infusion of meperidine (0.5 mg/kg) and 0.2 mg Buscopan in 100 ml normal saline.

The procedures were performed in an operating theatre on a radiolucent operating table under fluoroscopic guidance. The patient was placed in gynecological position, with the swing-arm of the fluoroscope placed in antero-posterior position centered on the pelvis. A standard colonoscope (CLV-U20, Olympus) was used. Later SEMS were placed endoscopically, using an endoscope with a large working channel (GIF-XTQ160 Video Gastroscopy, Olympus).

With the patient lying supine in gynecological position the endoscope was introduced to the point of stricture. If fluoroscopic guidance was used, the endoscope was placed with the tip next to the stricture, and an X-ray was taken as a reference for the level of obstruction. Preoperative pelvic MRI was used to determine the length of the stricture. Patients with a stricture of more than 6 cm, or patients with multi-level stenosis and a contorted stricture, were preoperatively determined as not

amenable for stenting. A guidewire was then introduced through the stricture under fluoroscopic control. A coaxial release system was passed along the guidewire and a nitinol uncovered stent was inserted and advanced over the stricture. Only stents 110 mm in length and 25 mm in diameter were used (Hanarostent NNN; M.I.Tech Co., Gyeonggi-Do, Korea). The stent was placed with the proximal and distal ends extending 2 cm over the stricture. Later we adopted endoscopically guided SEMS placement through the working channel of the endoscope. The guide for the correct position of the stent was the proximal marker on the release system, which was placed 2 cm over the distal end of the stricture. During the deployment of the releasing system, the position of the stent was frequently corrected because of the tendency of distal migration of the stent.

Technical success of stent placement was determined endoscopically and radiologically. A successful SEMS placement was defined as a fully deployed stent extending at least 2 cm over the proximal and distal ends of the stricture. The position was additionally verified endoscopically immediately after SEMS placement. Clinical success was defined as colonic decompression within 24 hours after the procedure. Patients that were symptom-free and were passing stool satisfactorily were discharged within 1 day if no additional procedures were planned and if their general state permitted.

## Surgery

If the stenting was successful and the signs of acute bowel obstruction subsided, patients were presented to the multidisciplinary colorectal team. Patients with rectal carcinoma amenable for neoadjuvant treatment were taken over by the oncologist and operated on after radio/chemotherapy. The surgery was performed in accordance with the recommendations for the treatment of patients with colorectal cancer in Slovenia.

A protective stoma was fashioned at the surgeon's discretion. A terminal ostomy was chosen if the patient was in a poor general state, if the remaining colon was of poor quality, or if an anastomosis carried a great risk of failure. The surgery was performed open or laparoscopically, depending on the patients' general state, tumor stage, tumor location, or previous abdominal surgery.

## Follow-up

Patients were regularly examined postoperatively as outpatient visits. The first control was 3 weeks after discharge and at regular 3-month intervals afterward or until complications occurred. Patients were examined by surgeons and the stoma therapist. All stoma- and stent-related complications were recorded.

## Endpoints

Primary endpoints were clinical resolution of bowel obstruction, morbidity, and mortality after SEMS placement. Secondary endpoints were clinical, objective, and histological regression. Clinical regression was defined as downsizing of the tumor on digito-rectal exam. Objective regression was defined as a regression grade according to Dworak. Histological regression was defined as a grade of tumor replacement by fibrotic tissue.

## Statistical Analysis

Categorical variables were expressed as numbers and percentages, and normally distributed continuous variables were expressed as mean  $\pm$  standard deviation. Continuous variables without a normal distribution were expressed as median and interquartile range. The Shapiro-Wilk and Kolmogorov tests were used to test normality. Normally distributed continuous variables were compared with Student's *t*-test, and continuous variables without normal distribution were compared with the Mann-Whitney *U* test. For comparison of categorical data, the  $\chi^2$  test was used. Survival analysis was performed with the Kaplan-Meier method. A *p*-value of 0.05 was selected as the level of significance.

## Results

Eight patients were selected for bridging stenting with the intention to treat with interval colon resection. The mean age of the patients in which a SEMS was introduced was  $69 \pm 12.5$  years. Six patients were male and two were female. The patients were in good general health, mostly with no accompanying diseases. The tumor was

usually located in the middle or upper third of the rectum. The average distance from the anocutaneous line was  $14 \pm 13.5$  cm. After stenting, six patients completed  $5 \times 5$  Gy fraction radiotherapy. The patients' characteristics are presented in Table 1.

## Stent Placement Results

After the placement of SEMS, the resolution of clinical symptoms of bowel obstruction was observed in all eight patients. There were no early general or surgical complications after the

**Table 1.** Patient and procedural characteristics.

Variable	Value
Age, years $\pm$ SD	$69 \pm 12.5$
Sex, n (%)	
M	6 (75)
F	2 (25)
Tumor distance from anocutaneous line, cm $\pm$ SD	$14 \pm 13.5$
Hospital stay after stenting, days (IQR)	5 (10.7)
Surgical complications after stenting, n (%)	
Yes	0 (0)
No	8 (100)
General complications after stenting, n (%)	
Yes	0 (0)
No	8 (100)
Early stent removal, n (%)	
Yes	1 (12.5)
No	7 (87.5)
Clinical efficiency, n (%)	
Yes	8 (100)
No	0 (0)
Radiotherapy, n (%)	
Yes	6 (75)
No	2 (25)
Time interval to interval colon resection, days (IQR)	95 (200)
Protective ostomy at resection, n (%)	
Yes	5 (62.5)
No	3 (37.5)
TNM T stage, n (%)	
0	1 (12.5)
3	6 (75)
4a	1 (12.5)



TNM N stage, n (%)	
0	3 (37.5)
1a	1 (12.5)
1c	1 (12.5)
2a	1 (12.5)
2b	2 (25)
TNM M stage, n (%)	
0	6 (75)
1	2 (25)
R0, n (%)	
Yes	8 (100)
No	0 (0)
Complications according to Clavien–Dindo for interval colorectal resection, n (%)	
0	5 (62.5)
2	1 (12.5)
3a	1 (12.5)
3b	1 (12.5)
Regression clinical, n (%)	
Yes	4 (50)
No	4 (50)
Regression Dworak, n (%)	
0	3 (37.5)
1	1 (12.5)
3	3 (37.5)
4	1 (12.5)
Regression histological, n (%)	
Yes	5 (62.5)
No	3 (37.5)
ASA, n (%)	
I	6 (75)
II	2 (25)
Laparoscopic interval colon resection, n (%)	
Yes	4 (50)
No	4 (50)
Type of colon operation, n (%)	
Anterior rectum resection	1 (12.5)
Segmental sigmoid colon resection	2 (25.5)
Abdominoperineal excision	1 (12.5)
Laparoscopic anterior rectum resection	2 (25.2)
Laparoscopic segmental sigmoid colon resection	2 (25.2)

placement. Patients were discharged after a median hospital time of 5 days. The most common late complication was dislocation in one case and bleeding, which ceased after conservative treatment in another patient. Dislocation led to early stent removal in one case.

## Surgery Results

After a median period of 95 days, patients were scheduled for interval surgery. After preoperative evaluation, clinical regression was observed in four patients. In addition, preoperative MRI of the pelvis showed a regression in five cases. In three cases Dworak regression grade 3 was observed, in one case a complete regression was observed, and one case Dworak regression grade 1 was observed. The regression could be later confirmed on histological exams of the specimen in five cases. Most of the patients had a T3N0 tumor. Synchronous liver metastases were observed in two patients. In both patients a liver-first operation could have been performed thanks to successful stent placement. Hence a globally curative resection could have been made in all eight patients. In four patients a laparoscopic procedure was performed. The surgeons opted for a protective ostomy in five patients, whereas three patients did not receive an ostomy. No major or minor complications were observed after surgical resection in six patients, one patient had a complication of Clavien–Dindo grade IIIa, and in one case a grade IIIb complication was observed.

## Survival

The median observation period was 921 days (210–1,582 days). During that period, none of the patients included died, and none of the patients experienced a recurrence of the disease.

## Discussion

There is no doubt about the usefulness of SEMS in palliative treatment of obstructing cancer, but there is much more controversy when considering the placement of SEMS in patients with acute left colonic obstruction as a bridge to surgery (14). Patients with obstructive cancer in which we have the

intention to cure could be operated on immediately with emergency resection performed, but this procedure is accompanied by high morbidity and mortality. A better option would be decompression of the colon, which would offer more time for patient preparation, better staging, introduction of neoadjuvant treatment, and good preparation for elective surgery or even laparoscopic surgery. Such a decompression procedure turns emergency surgery into elective surgery. Traditionally, there was only one solution for decompression: diverting ostomy. With the introduction of SEMS in 1992, new possibilities arose; we could decompress the patient with a simple procedure without general anesthesia and the need for ostomy, which is an operation with significant morbidity and mortality, and also has a major negative psychological effect. We always thought that SEMS as a bridge to surgery is a better option than diverting ostomy, but it was not the point of view of decision-makers in Europe. In 2014, ESGE guidelines strongly advised against this procedure (11). Despite this, studies about SEMS as a bridge to surgery continued, and the procedure was still used in selected cases (21–23). In our series, we used SEMS as a bridge to surgery in eight patients with acute left colon obstruction. Two of them had the obstruction in the sigmoid colon, and six patients had a rectal obstruction.

Stent placement was described as a safe procedure with low morbidity and very low mortality (15). In our series, we also did not observe any short-term complications at SEMS insertion, and only one patient had problems due to SEMS migration. In this patient, the SEMS was extracted after the decompression was successfully performed.

The short hospital stays after SEMS placement, combined with rapid functional bowel recovery, are the main benefits of SEMS placement. The median hospital stay after SEMS placement was only 5 days in our study. Patients could proceed expeditiously in good general condition to chemoradiotherapy. All six patients included with rectal cancer could complete the neoadjuvant chemoradiotherapy regimen. This is a testimony to the excellent general condition of patients after stent placement.

The benefits of neoadjuvant treatment in rectal cancer have been well established. It is therefore imperative that patients recover as quickly as possible and be in the best condition after colon obstruction resolution. This guarantees the

best oncological results. The value of neoadjuvant treatment was evident in our study. An objective tumor regression was observed in 62.5% of patients that received adjuvant chemoradiotherapy. One patient had a complete response, three had a Dworak grade 3 response, and one had a Dworak grade 1 response. The tumor down-staging and down-sizing reduced the extent of the resection. In all cases, microscopic tumor-free margins could be obtained on radical operation. The patients avoided a demanding and oncologically inferior emergency operation. In the wake of resolution of colon obstruction, their bowel could be sufficiently prepared for a safe laparoscopic resection and primary anastomosis formation. We managed to perform a laparoscopic resection in four cases. Shimizu et al. reported that SEMs placement reduced the rate ostomy formation after SEMs placement and laparoscopic resection (21). We did not observe a significant reduction in ostomy formation in our series. This might be due to the individual surgeon's preference, but it is more likely that the resection itself was more demanding after stent placement. Therefore, more than a third of patients received an ostomy during the operation. Indeed, there is some debate concerning laparoscopic colorectal resections after SEMs insertion (16). Some authors have pointed out that the surgical preparation could be more difficult because of rigidity of the colonic segment with a SEMs, but mostly they agree that the procedure is possible (17, 18). We agree that laparoscopic surgery on patients with a SEMs is more demanding, and we recommend that such operations be performed by experienced laparoscopic surgeons.

Although many studies have also confirmed the short-term safety and benefits of SEMs placement, there are still many concerns regarding long-term prognosis after SEMs placement. ESGE advocates against the use of bridging SEMs. In their recommendations, they heavily cited the study by van Hooft et al., in which the authors claimed that SEMs placement caused tumor cell spillage and dissemination due to undiagnosed microperforations (24). This hypothesis, however, did not stand the test of time, and no randomized controlled trials could prove the negative prognostic impact of SEMs placement on long-term survival (21–23). On the contrary, many small prospective cohort trails have proven the safety of SEMs placement without a negative impact on survival. In our patient group, we did not observe

any locoregional or distant recurrence after median time of follow-up of  $925 \pm 550$  days. We believe that insertion of SEMs in patients with left colon obstruction is a better solution than diverting ostomy. Our rather modest experience has been confirmed by far larger studies and meta-analyses (7, 13, 19). In 2020, the ESGE released guidelines in which they revised the recommendations regarding SEMs as a bridge to colon resection. ESGE suggests consideration of colonic stenting for malignant obstruction of the proximal colon either as a bridge to surgery or in a palliative setting, which is in line with our observations (20).

The results of our study confirm that SEMs insertion as a bridge to surgery in patients with acute left colorectal obstruction is a safe method and above all a patient-friendly one. It relieves the obstruction and gives the patient time for preparation for radical laparoscopic surgery without ostomy.

## References

1. Frago R, Ramirez E, Millan M, et al. Current management of acute malignant large bowel obstruction: a systematic review. *Am J Surg.* 2014;207:127–38.
2. Meyer F, Marusch F, Coch A, Meyer L, Fuhrer S, et al.; the German Study Group Colorectal Carcinoma (Primary Tumor). Emergency operation in carcinomas of the left colon: value of Hartmann's procedure. *Tech Coloproctol.* 2004;8:S226–9.
3. Zorcolo L, Covotta L, Carlomagno N, Bartolo DC. Safety of primary anastomosis in emergency colorectal surgery. *Colorectal Dis.* 2003;5:262–9.
4. Trompetas V. Emergency management of malignant acute left-sided colonic obstruction. *Ann R Coll Surg Engl.* 2008;90(3):181–6.
5. Foo CC, Poon JTC, Law WL. Self-expanding metallic stents for acute left-sided large-bowel obstruction: a review of 130 patients. *Colorectal Dis.* 2011;13(5):549–54.
6. Ho KM, Chan KM, Kwok SY, Lau PY. Colonic self-expanding metal stent (SEMS) as a bridge to surgery in left-sided malignant colonic obstruction: an 8-year review. *Surg Endosc.* 2017;31(5):2255–62.
7. Arezzo A, Balague C, Targarona E, Borghi F, Giraudo G, et al. Colonic stenting as a bridge to surgery versus emergency surgery for malignant colonic obstruction: results of a multicentre randomized controlled trial (ESCO trial). *Surg Endosc.* 31(8):3297–305.
8. Ribeiro IB, Bernardo WM, da Costa Martins B, de Moura DTH, Baba ER, et al. Colonic stent versus emergency surgery as treatment of malignant colonic obstruction in the palliative setting:

- a systematic review and meta-analysis. *Endosc Int Open*. 2018;6(5):E558–67.
9. Arezzo A, Passera R, Lo Secco G, Verra M, Bonino MA, et al. Stent as bridge to surgery for left-sided malignant colonic obstruction reduces adverse events and stoma rate compared with emergency surgery: results of a systematic review and meta-analysis of randomized controlled trials. *Gastrointest Endosc*. 2017;86(3):416–26.
  10. Foo CC, Poon SHT, Chiu RHY, Lam WY, Cheung LC, et al. Is bridge to surgery stenting a safe alternative to emergency surgery in malignant colonic obstruction: a meta-analysis of randomized control trials. *Surg Endosc*. 2019;33(1):293–302.
  11. van Hooft JE, van Halsema EE, Vanbiervliet G, Beets-Tan RG, DeWitt JM, et al.; European Society of Gastrointestinal Endoscopy. Self-expandable metal stents for obstructing colonic and extracolonic cancer: European Society of Gastrointestinal Endoscopy (ESGE) Clinical Guideline. *Endoscopy*. 2014;46(11):990–1053.
  12. Matsuzawa T, Ishida H, Yoshida S, Isayama H, Kuwai T, et al. A Japanese prospective multicenter study of self-expandable metal stent placement for malignant colorectal obstruction: short-term safety and efficacy within 7 days of stent procedure in 513 cases. *Gastrointest Endosc*. 2015;82(4):697–707.
  13. Hill J, Kay C, Morton D, Magill H, Handley K, et al. CREST: randomised phase III study of stenting as a bridge to surgery in obstructing colorectal cancer—results of the UK ColoRectal Endoscopic Stenting Trial (CREST). *J Clin Oncol*. 2016;34:Suppl 15:3507.
  14. Ormando VM, Palma R, Fugazza A, Repici A. Colonic stents for malignant bowel obstruction: current status and future prospects. *Expert Rev Med Devices*. 2019;16(12):1053–61.
  15. Sousa M, Pinho R, Proença L, Silva J, Ponte A, et al. Predictors of complications and mortality in patients with self-expanding metallic stents for the palliation of malignant colonic obstruction. *GE Port J Gastroenterol*. 2017;24:122–8.
  16. Shimizu H, Yamazaki R, Ohtsuka H, Osaka I, Takuma K, et al. Feasibility of laparoscopic surgery after stent insertion for obstructive colorectal cancer. *Asian J Endosc Surg*. 2018;11(2):118–22.
  17. Enomoto T, Saida Y, Takabayashi K, Nagao S, Takeshita E, et al. Open surgery versus laparoscopic surgery after stent insertion for obstructive colorectal cancer. *Surg Today*. 2016;46(12):1383–6.
  18. Law WL, Poon JT, Fan JK, Lo OS. Colorectal resection after stent insertion for obstructing cancer: comparison between open and laparoscopic approaches. *Surg Laparosc Endosc Percutan Tech*. 2013;23(1):29–32.
  19. Jain SR, Yaow CYL, Ng CH, et al. Comparison of colonic stents, stomas and resection for obstructive left colon cancer: a meta-analysis. *Tech Coloproctol*. 2020;24:1121–36.
  20. van Hooft JE, Veld JV, Arnold D, Beets-Tan RGH, Everett S, et al. Self-expandable metal stents for obstructing colonic and extracolonic cancer: European Society of Gastrointestinal Endoscopy (ESGE) Guideline—Update 2020. *Endoscopy*. 2020;52(5):389–407.
  21. Shimizu H, Yamazaki R, Ohtsuka H, Osaka I, Takuma K, et al. Feasibility of laparoscopic surgery after stent insertion for obstructive colorectal cancer. *Asian J Endosc Surg*. 2018;11:118–22.
  22. Tomita M, Saito S, Makimoto S, Yoshida S, Isayama H, et al. Self-expandable metallic stenting as a bridge to surgery for malignant colorectal obstruction: pooled analysis of 426 patients from two prospective multicenter series. *Surg Endosc*. 2019;33:499–509.
  23. Arezzo A, Balague C, Targarona E, Borghi F, Giraudo G, et al. Colonic stenting as a bridge to surgery versus emergency surgery for malignant colonic obstruction: results of a multicentre randomised controlled trial (ESCO trial). *Surg Endosc*. 2017;31:3297–305.
  24. van Hooft JE, Bemelman WA, Oldenburg B, Marinelli AW, Lutke Holzik MF, et al.; Dutch Stent-In Study Group. Colonic stenting versus emergency surgery for acute left-sided malignant colonic obstruction: a multicentre randomised trial. *Lancet Oncol*. 2011;12:344–52.

# Management of Open Abdomen after Trauma Laparotomy with an Abdominal Reapproximation Anchor System in Conjunction with Negative-Pressure Wound Therapy: A Case Report With a Review of the Literature

Jurij Aleš Košir, Jan Grosek, Aleš Tomažič

Department of Abdominal Surgery, Ljubljana University Medical Center

## CORRESPONDENCE

Jurij Aleš Košir, MD  
jurij.ales.kosir@kclj.si

## KEY WORDS

open abdomen, damage-control laparotomy, abdominal reapproximation anchor system, negative-pressure wound therapy, abdominal trauma, temporary abdominal closure

## CASE REPORT

SURGERY SURG ENDOS 2021; 3(1):  
21-26

## Abstract

Open abdomen is a surgical technique that is being increasingly used in the treatment of intra-abdominal sepsis, damage-control laparotomy, and abdominal compartment syndrome. The most commonly used method to sustain open abdomen is with the negative-pressure wound therapy system. However, the use of negative-pressure wound therapy is associated with lateral retraction of the abdominal wall, and at the end of surgical treatment fascial closure is not achievable in one-third of patients. The abdominal reapproximation anchor system allows closure of the abdominal wall in a higher proportion of patients than the use of negative-pressure wound therapy system alone. We present a case report of a 59-year-old woman that suffered severe abdominal trauma when injured as a driver in a motor vehicle collision. A damage-control laparotomy was performed, and temporary abdominal closure was achieved with negative-pressure wound therapy. Due to severe injuries to the abdominal wall and severe retraction of the fascia, we used the abdominal reapproximation anchor system to close the fascial defect.

## Introduction

In trauma, damage-control laparotomy is a well-established technique that improves the survival of patients with abdominal trauma (1, 2). It focuses on swift correction of intraabdominal bleeding and contamination without achieving the previous anatomical completeness that can be managed in subsequent operations, when the patient is in better condition. One of the



key components of damage-control laparotomy is postponing the closure of the abdominal fascia until after the intraabdominal injuries have been successfully managed (1). This so-called open abdomen (OA) prevents the development of abdominal compartment syndrome and it allows easier reentry into the abdomen and a faster transition of the patient to the intensive care unit, where final correction of coagulopathy, hypothermia, and acidosis can be managed (3). With the widespread use of OA, several methods of temporary abdominal closure (TAC) have been developed to protect the abdominal organs while the abdominal fascia is open.

Methods of TAC currently in use include passive closure of the abdomen with skin or a Bogota bag, the use of a Wittmann patch, transient use of mesh, dynamic fascial traction systems, and negative-pressure wound therapy (NPWT) (4, 5). NPWT is used the most because of its ability to evacuate fluids and prevent fascial retraction while preventing adhesions of the bowel to the abdominal wall. However, fascial retraction is not prevented entirely and can still lead to progressive loss of the abdominal domain (6, 7). NPWT used alone allows primary fascial closure in 63.5 to 88% of cases (7–9). The inability to primarily close the fascia leads to a higher occurrence of enteroatmospheric fistulas, chronic back pain, poor mobility, the need for skin grafting, or a giant postoperative hernia, and it is associated with poorer survival (10).

The use of NPWT together with dynamic fascial traction systems or with mesh reduces fascial retraction and can increase the fascial closure rate to 90% (8, 11–13). The use of NPWT with mesh-mediated traction was first described by Peterson, who used a polypropylene mesh sutured to the fascial edges and reapproximated them every couple of days (14).

The abdominal reapproximation anchor system (ABRA) is an example of a dynamic fascial traction system that uses transfascial elastomers to provide appositional traction on the abdominal fascia. A visceral protector is placed under the elastomers to protect the bowel, and the elastomers are anchored to the abdominal skin on each side under slight tension. The combined use of NPWT and ABRA have increased the closure rate to an estimated 83 to 92% (5, 15).

This article presents a case report of a patient that suffered from severe abdominal trauma that

required a trauma laparotomy and the use of a TAC system to correct the injuries and intraabdominal sepsis. Wide retraction of the fascia developed due to injuries to the abdominal wall and the prolonged use of OA, but it was successfully treated with the use of ABRA.

## Case report

A 59-year-old female patient was urgently admitted to the intensive care unit of a tertiary medical center due to polytrauma that she suffered in a motor vehicle collision. She suffered a subarachnoid hemorrhage, fracture of the first rib on the left side, fracture of the sternum, bilateral pneumothorax, rupture of the abdominal wall, dissection of the left common iliac artery with a large retroperitoneal hematoma, and fracture of the right patella.

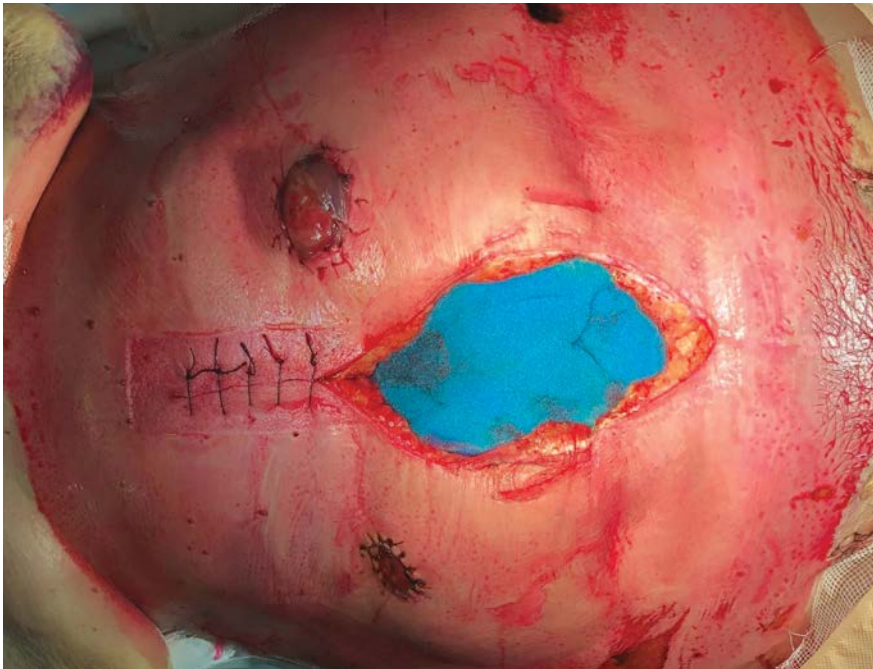
At the time of the injury, she was receiving anti-coagulant therapy with rivaroxaban due to chronic atrial fibrillation. She was not suffering from any other significant chronic diseases.

After initial resuscitation in the emergency department, she underwent insertion of an aorto-bi-iliac endograft to stop the bleeding. During the procedure, she received 14 units of packed red blood cells, eight units of fresh frozen plasma, three units of thrombocytes, and other coagulation factors. The following day we repeated an abdominal CT scan, which revealed hematomas in the abdominal wall and in the paracolic space without active extravasation. Due to suspicion of small intestinal injury on the previous CT and higher intra-abdominal pressure, she was operated on the day after the injury. Exploratory laparotomy revealed multiple small bowel perforations, ischemia of the sigmoid colon, destruction of the abdominal wall, and multiple hematomas. The small bowel was resected and primary anastomoses were performed, the sigmoid colon was also resected, and a terminal colostomy was created at the site of resection. NPWT was inserted to facilitate the reentry into the abdomen 3 days later, where an additional small bowel perforation was resected and an ischemic part of the bowel was resected, leaving in total 150 cm of small bowel with an end ileostomy. The previous colostomy was left in situ as a mucous fistula. On the third reentry into the abdomen, 8 days after the primary lapa-

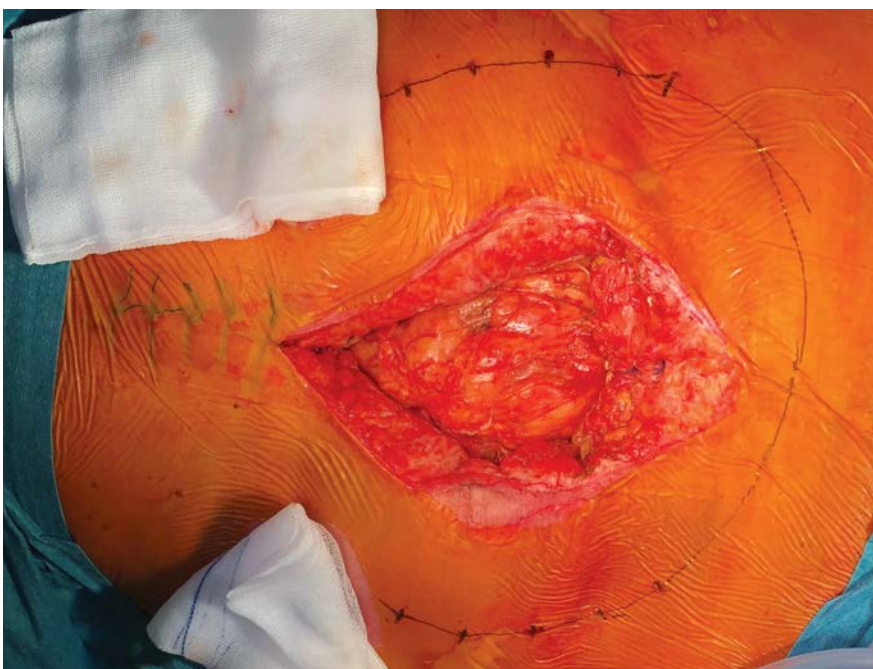rotomy was made, we inserted ABRA to facilitate abdominal wall closure (Figures 1–7). Every 24 hours we readjusted the tension on the elastomers to progressively reapproximate the fascia. Three days after the insertion of ABRA, the abdominal fascia was successfully closed without significant tension and ABRA was removed.

She was treated in the intensive care unit for 2 months and after this she received treatment on the surgical ward and in the rehabilitation unit for

2 more months. She was treated for short bowel with parenteral home nutrition, and 1 year after the accident she was reoperated on and the terminal ileostomy along with the mucous fistula were closed to establish continuity of the bowel and improve bowel function. At the time of stomal closure, there was no ventral hernia in the anterior abdominal wall. However, 3 months after this operation she still requires home parenteral nutrition due to persisting short bowel.



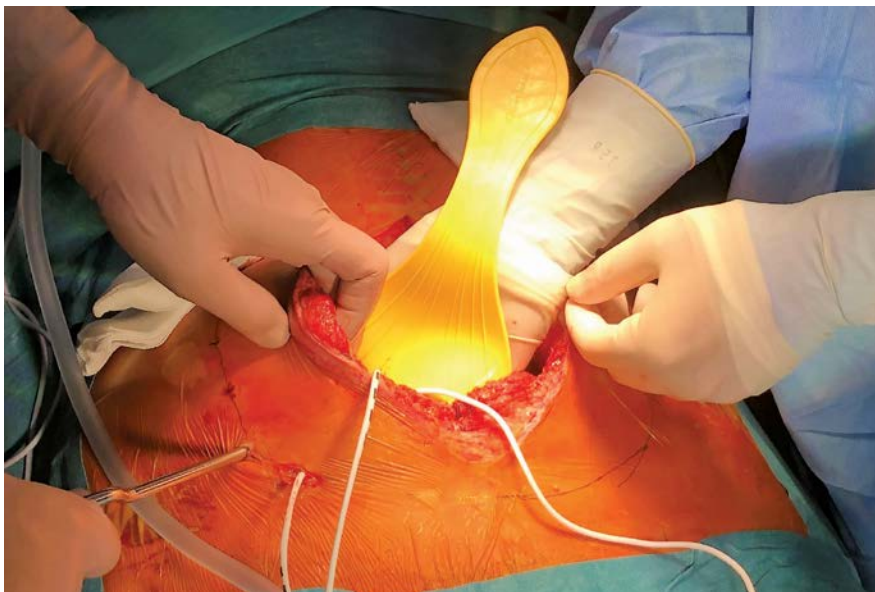
**Figure 1.** Laparotomy at the start of the operation after removing the previously inserted negative-pressure wound therapy system. On the right side of the wound there is a terminal ileostomy, and on the left side of the wound there is a mucous fistula to the descending colon.



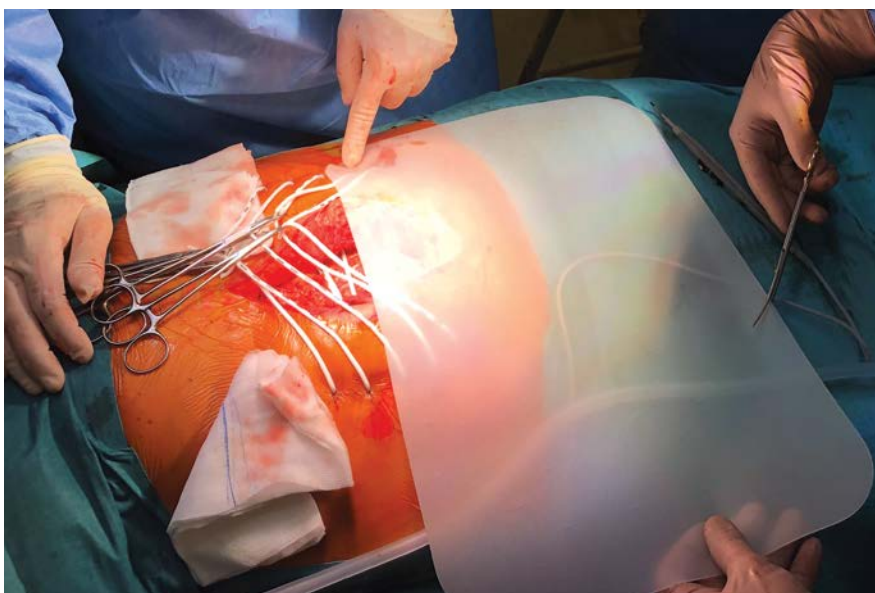
**Figure 2.** Marking for insertion sites of elastomers.



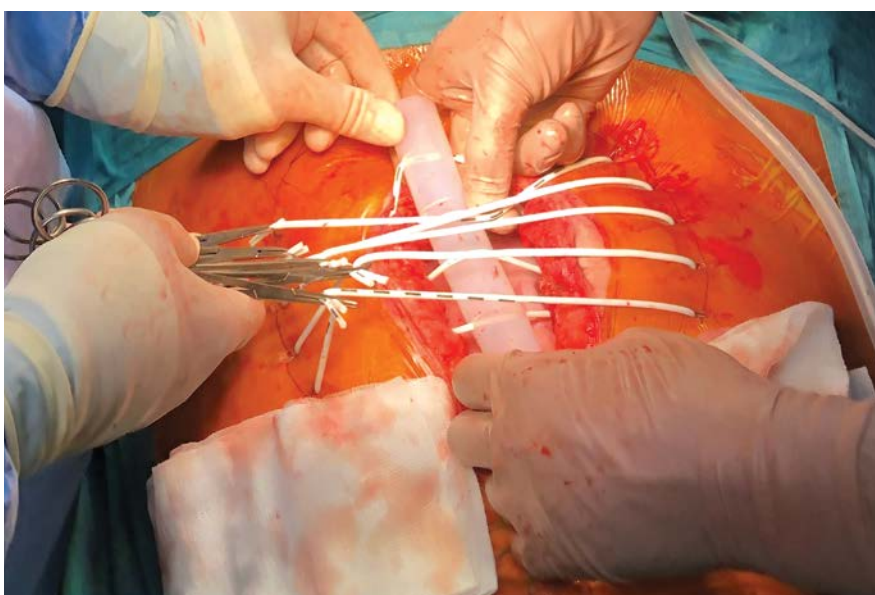
**Figure 3.** Insertion of the silicone elastomers.

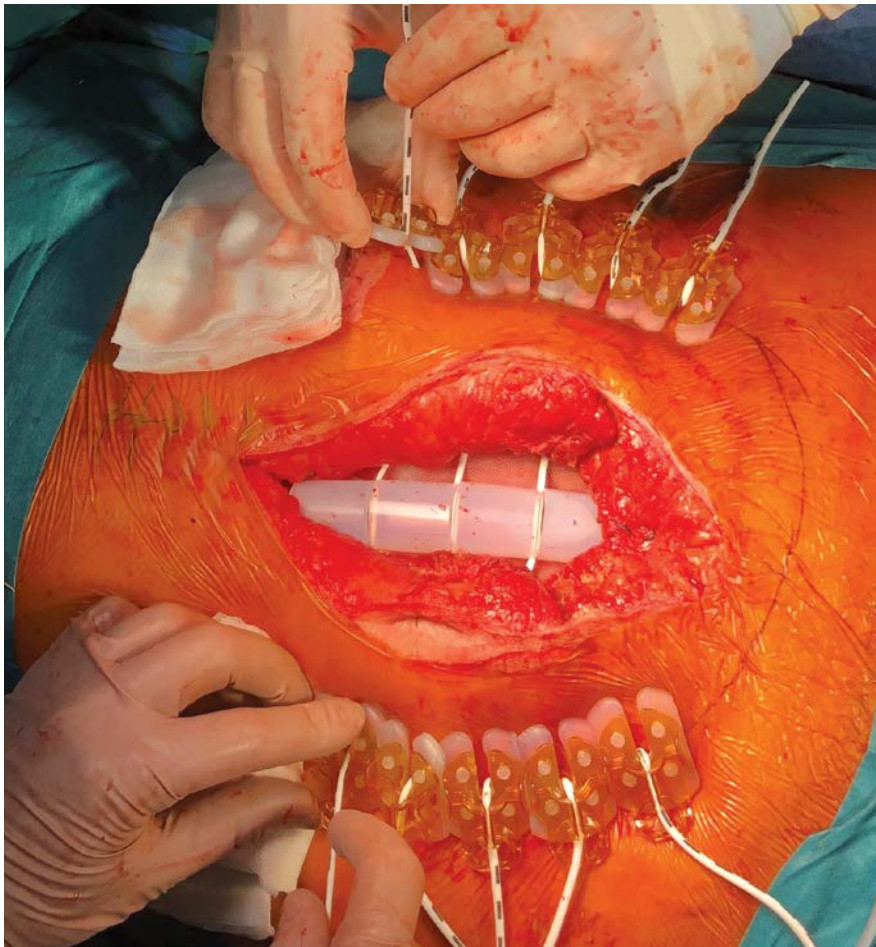


**Figure 4.** Resizing the perforated silicone viscera protector.

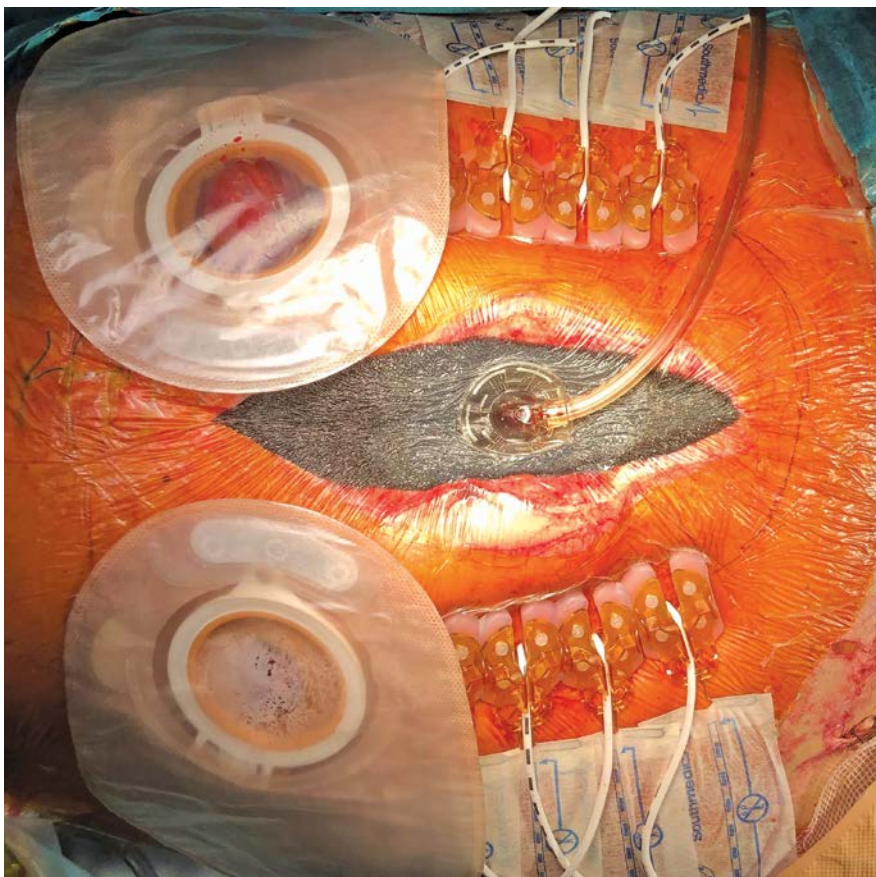


**Figure 5.** Installation of the elastomer retainer.





**Figure 6.** Anchoring the elastomers.



**Figure 7.** The end result after applying the negative-pressure wound therapy device.



## Discussion

Although OA is a technique that saves lives, it is associated with morbidity related to the loss of abdominal domain, enteroatmospheric fistula, and loss of proteins and electrolytes (15). These are the reasons why it is so important to close the abdominal fascia as soon as possible. The use of NPWT slows down the retraction of the fascia, but not completely. It is estimated that after 3 to 5 days of NPWT the fascial closure is impaired, and in the case of significant retraction the use of ABRA is advised (5). Other factors that can reduce the rate of abdominal wall closure have to be accounted for, such as concomitant defects of the abdominal wall and intraabdominal hypertension, which can be related to edema of the intra-abdominal organs or dilation of the bowel. Our patient suffered from both severe injury to the abdominal wall and also severe edema resulting in anasarca. Both of these contributed to inability to close the fascia without tension. The major bowel resection in this regard helped with the abdominal closure by reducing the volume of intraabdominal content.

There is still room to optimize TAC techniques, and there are no widely accepted recommendations regarding this yet. We are still waiting for prospective randomized trials to gain a better understanding of the impact of each method.

## Conclusion

Damage-control laparotomy has had a major impact on the survival of trauma patients, but optimal treatment is still a challenge. The use of ABRA allows primary fascial closure in patients treated with NPWT that are at risk of progressive loss of abdominal domain.

## References

1. Rotondo MF, Schwab CW, Philips GR, Fruchterman TM, et al. "Damage control": an approach for improved survival in exsanguinating penetrating abdominal injury. *J Trauma*. 1993;35:375–82.
2. Stone HH, Strom PR, Mullins RJ. Management of the major coagulopathy with onset during laparotomy. *Ann Surg*. 1983;197:532–5.
3. Morris JA, Eddy VA, Blinman TA, Rutherford EJ, Sharp KW. The staged celiotomy for trauma. Issues in unpacking and reconstruction. *Ann Surg*. 1993;217:576–84.
4. Sharrock AE, Barker T, Yuen HM, Rickard R, Tai N. Management and closure of the open abdomen after damage control laparotomy for trauma. A systematic review and meta-analysis. *Injury*. 2016;47(2):296–306.
5. Ladha P, Callander M, Sifri ZC. What's new in critical illness and injury science? Management of the open abdomen: getting it together! *Int J Crit Illn Inj Sci*. 2019;9(2):51–3.
6. Ribeiro Junior MAF, Barros EA, Marques de Carvalho S, Nascimento VP, et al. Open abdomen in gastrointestinal surgery: which technique is the best for temporary closure during damage control? *World J Gastrointest Surg*. 2016;8:590–7.
7. Cheatham ML, Demetrios D, Fabian TC, Kaplan MJ, et al. Prospective study examining clinical outcomes. *World J Surg*. 2013;37:2018–30.
8. Miller PR, Meredith JW, Johnson JC, Chang MC. Prospective evaluation of vacuum-assisted fascial closure after open abdomen: planned ventral hernia rate is substantially reduced. *Ann Surg*. 2004;239:608–14.
9. Cirocchi R, Birindelli A, Biffl WL, Mutafchiyski V, et al. What is the effectiveness of the negative pressure wound therapy (NPWT) in patients treated with open abdomen technique? A systematic review and meta-analysis. *J Trauma Acute Care Surg*. 2016;81:575–84.
10. Cheatham ML, Safcsak K. Is the evolving management of intra-abdominal hypertension and abdominal compartment syndrome improving survival? *Crit Care Med*. 2010;38:402–7.
11. Regner JL, Kobayashi L, Coimbra R. Surgical strategies for management of the abdomen. *World J Surg*. 2012;36:497–510.
12. Rasilainen SK, Mentula PJ, Leppaniemi AK. Vacuum and mesh-mediated fascial traction for primary closure of the open abdomen in critically ill surgical patients. *Br J Surg*. 2012;99:1725–32.
13. Cothren CC, Moore EE, Johnson JL, et al. One hundred percent fascial approximation with sequential abdominal closure of the open abdomen. *Am J Surg*. 2006;192:238–42.
14. Petersson U, Acosta S, Björck M. Vacuum-assisted wound closure and mesh-mediated fascial traction—a novel technique for late closure of the open abdomen. *World J Surg*. 2007;31:2133–7.
15. Mukhi AN, Minor S. Management of the open abdomen using combination therapy with ABRA and AB-Thera systems. *Can J Surg*. 2014;57:314–9.



# A Rare Case of Mixed Epithelial and Stromal Tumor of the Kidney Managed by Robot-Assisted Laparoscopic Partial Nephrectomy

Klemen Lovšin,<sup>1</sup> Simon Hawlina<sup>2,3</sup>

<sup>1</sup> Department of Plastic, Reconstructive, and Aesthetic Surgery and Burns, Ljubljana University Medical Center

<sup>2</sup> Department of Urology, Ljubljana University Medical Center

<sup>3</sup> Department of Surgery, Faculty of Medicine, University of Ljubljana

## CORRESPONDENCE

Asst. Simon Hawlina, MD, FEBU  
simon.hawlina@kclj.si

## KEY WORDS

mixed epithelial and stromal tumor, robot, partial nephrectomy, estrogen, kidney, minimally invasive surgery

## CASE REPORT

SURGERY SURG ENDOS 2021; 3(1):  
27-31

## Abstract

Mixed epithelial and stromal tumor is a rare entity that usually presents in middle-aged female patients with a history of long-term estrogen replacement therapy. Most commonly it has a benign course; however, malignant transformation has been described in the literature. Due to its appearance, it is difficult to diagnose it precisely using only radiological techniques. Therefore, it is usually surgically excised and histologically confirmed. We present the case of a mixed epithelial and stromal tumor that was successfully managed by robot-assisted laparoscopic partial nephrectomy. At the last follow-up, the patient did not show any local recurrence or signs of metastatic disease.

## Introduction

Mixed epithelial and stromal tumor (MEST) is a rare kidney neoplasm composed of a mixture of stromal and epithelial elements (1). In the large majority of cases, it is a benign tumor with rare malignant transformation. However, MEST is usually managed with surgical excision (2). Due to its radiological appearance, it is difficult to distinguish MEST from other renal cystic lesions. MEST was first defined by Michal and Syrucek in 1998 (3). Prior to that, similar tumors were described in the literature with various names such as biphasic tumor of the kidney, adult type of mesoblastic nephroma, and cystic hamartoma of the renal pelvis (4).

This article presents a patient with MEST that was successfully managed by robot-assisted laparoscopic partial nephrectomy.

## Case Presentation

A 48-year-old female was referred to our hospital with a history of intermittent left flank pain for 2 months. Prior ultrasound had revealed a Bosniak classification II to III cystic renal lesion in the left kidney. Her comorbidities were liver hemangioma and gallstones, which were not clinically significant. Physical examination by palpation did not show any evidence of abdominal mass. Routine blood test results were within the normal ranges, and routine urine analysis revealed no hematuria.

In addition, we performed an abdominal contrast-enhanced CT, which revealed a well-circumscribed cystic-solid mass 3 cm in diameter arising from the middle to upper pole of the left kidney and borders to the renal pelvis. The mass contained a few tiny septa and a small mural node that was clearly enhanced in the venous phase. Focal mural calcification was also present. The mass was classified as Bosniak IV and RENAL score 10a (Figure 1).

Considering all the clinical findings, a multidisciplinary board was held, consisting of urologists and radiologists. The preoperative diagnosis was cystic renal cell carcinoma. Robot-assisted laparoscopic partial nephrectomy was indicated.

The patient underwent the procedure in the lateral decubitus position. We used a transperitoneal four-arm approach using the DaVinci Xi robotic system. We added an additional 12 mm AIRSEAL® port for the assistant. During the procedure, we exposed the renal hilum, isolated the solitary renal artery and vein, and exposed the entire kidney, which appeared normal. We used a laparoscopic endoprobe ultrasound (Hitachi Ultrasound) to precisely locate the entirely intraparenchymal lesion. We proceeded with clamping of the renal artery. The kidney parenchyma above the tumor was sharply incised using cold scissors to allow better visualization of the tumor. Enucleation of the tumor was performed (Figure 2). During the excision we opened the renal calyx and sutured it.

After the excision, inner renorrhaphy with a running suture using Monocryl 4-0 was performed. We proceeded with outer renorrhaphy using three Vicryl 2-0 sutures and compressed the kidney parenchyma with the Hem-o-lok sliding technique. After renorrhaphy was completed, we

evaluated the perfusion of renal parenchyma with indigo-cyanine green (ICG; Figure 3). The entire kidney was very well perfused. Warm ischemia time was 32 minutes. The duration of the operation was 120 minutes. There was no significant blood loss (50 ml).

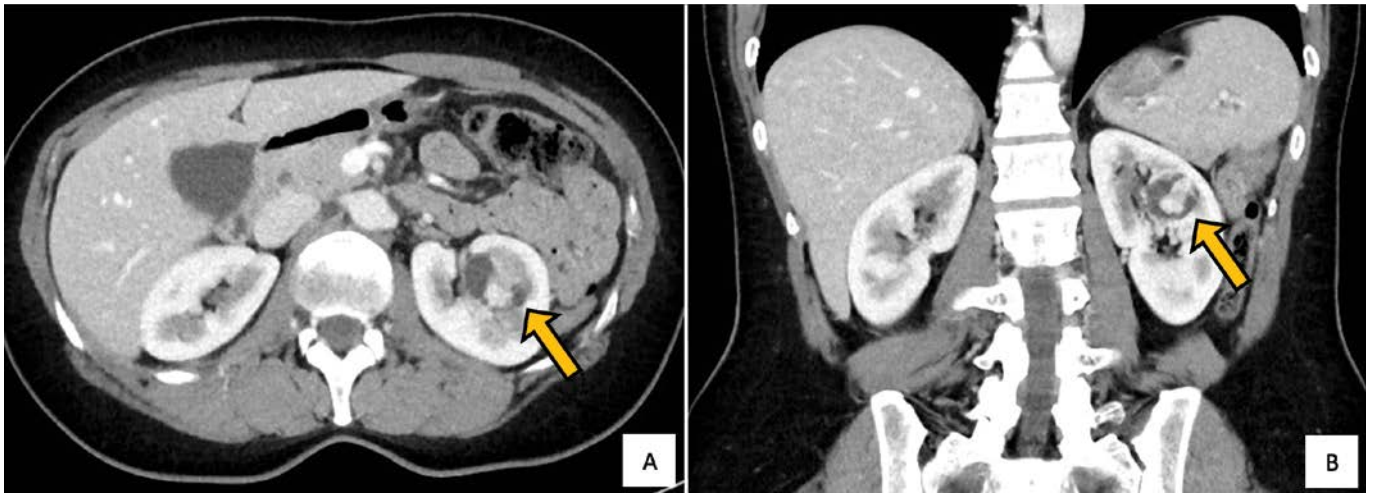
The postoperative course was uneventful, and the control ultrasound after the procedure was normal. The patient was discharged from the hospital 4 days after the procedure. The patient was readmitted to the hospital 2 days after the discharge due to fever and left flank pain. An ultrasound showed 33 ml of fluid in the left perirenal region. The patient was prescribed antibiotics, and she was discharged after 2 days. At the last follow-up after 18 months, she had no imaging findings of local recurrence or signs of metastatic disease, with normal kidney function.

The pathological and immunological findings confirmed MEST. The tumor with stromal and epithelial elements present measured 2.9 cm × 2.7 cm × 1.4 cm. The stromal component consisted of uniform spindle cells and excessive eosinophilic cytoplasm in a mixture of myxoid stroma. Some mitoses were found, but no necrosis was described. The immunohistochemical analysis of this component was positive for desmin, GMA, and CD10 but negative for estrogen and progesterone receptors, S100, WT1, CD117, inhibin, DOG1, HMB45, and melan-A. Tubular and glandular components were found in the epithelial part of the tumor. Larger cysts were also defined, with some cells protruding into the lumen in a hobnail pattern. Mitotic activity was not noted in this component. Immunohistochemically, the epithelial cells were positive for PAX8 and GATA3.

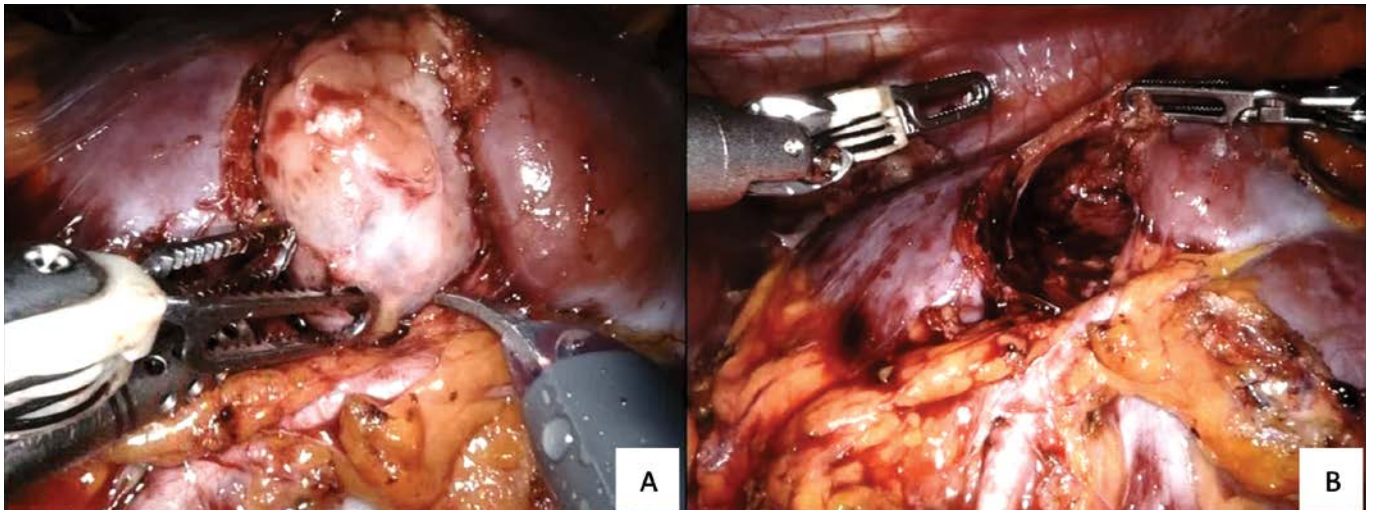
## Discussion

MEST is usually present in perimenopausal middle-aged female patients with a history of long-term estrogen replacement therapy (4). Our patient denied any use of oral contraceptives. Up to the publication of this article, only seven cases were confirmed in male patients (5). Advancements in radiological techniques and regular health examinations make possible early detection of the lesions (2, 4).

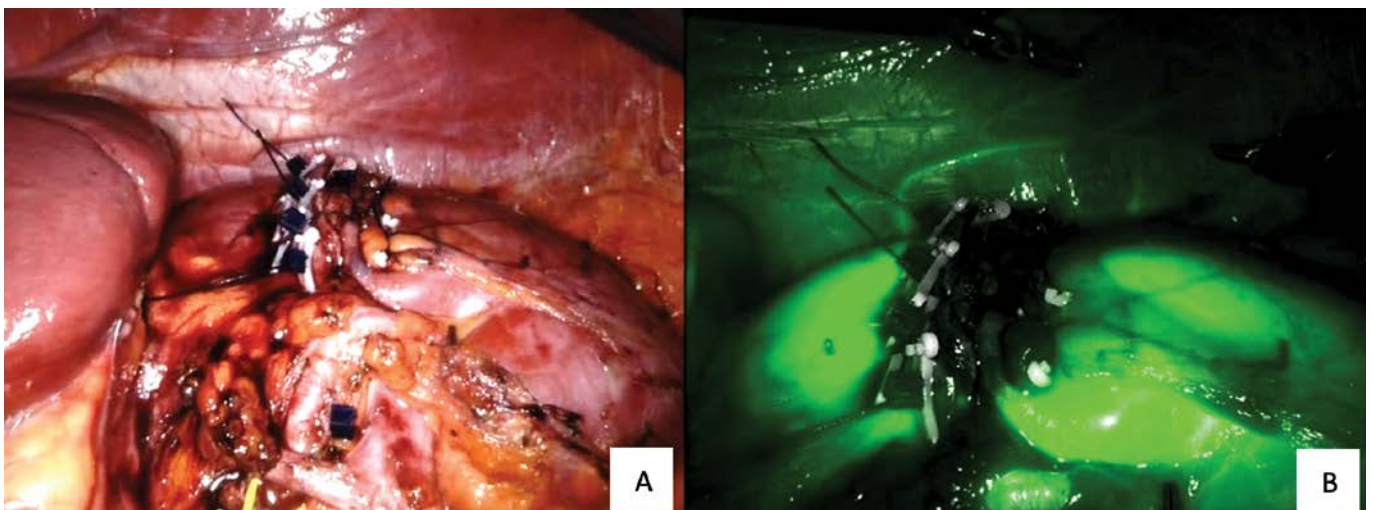
As the literature suggests, patients usually describe flank pain, hematuria, a palpable mass,



**Figure 1.** A) The axial venous phase contrast-enhanced CT scan shows a well-defined mass with cystic and solid components in the left kidney; B) in the coronal venous phase scan, the mass is also seen to contain slight septa. The arrow points the mass.



**Figure 2.** A) Partially excised cystic tumor during the procedure; B) tumor bed in the kidney after enucleation of the tumor.



**Figure 3.** A) The kidney after renorrhaphy; B) complete perfusion of the kidney was confirmed with ICG.



or recurrent genitourinary infections (1). Approximately 25% of MEST are found incidentally (1, 6). In our case, the tumor was first identified with ultrasound, which was performed due to the intermittent left flank pain. CT images of MEST usually reveal a multiseptated cystic and solid mass with delayed contrast agent enhancement (7). Due to a high Bosniak category, it is important to consider cystic renal cell carcinoma as a differential diagnosis (8). Because the tumor has a variable appearance, it may mimic cystic renal lesions, adult cystic nephroma, cystic renal cell carcinoma, a complex cyst, a multicystic dysplastic kidney, a renal abscess, or an obstructed duplicated renal collecting system (9). The last condition was our presumption during the excision of the tumor.

In nearly all reported cases, MEST has a favorable benign course; however, some cases have been described in the literature with malignant transformation to sarcomatoid carcinoma or with another aggressive course (10, 11). Our patient had no local recurrence at the last follow-up after 1.5 years.

The diagnosis of MEST depends on histological characteristics and immunohistological findings. There is usually a high frequency of estrogen and progesterone receptors present in the nuclei of the spindle cells (2). In our case, the tumor was negative for both estrogen and progesterone receptors. About 70% of MEST are Bosniak category IV or solid lesions (6). Such tumors are managed surgically with an open surgical approach in the majority of cases described (12, 13). There are about 100 case reports of renal MEST, but to the extent of our knowledge and research this is the first case described of robot-assisted partial nephrectomy in the treatment of MEST. We were able to remove the tumor with a minimally invasive approach. This method was confirmed to have shorter operative and warm ischemia time, fewer complications, less blood loss, and a shorter length of stay than open partial nephrectomy (14, 15). However, this superiority only applies to experienced surgeons that have completed the learning curve (15).

## Conclusion

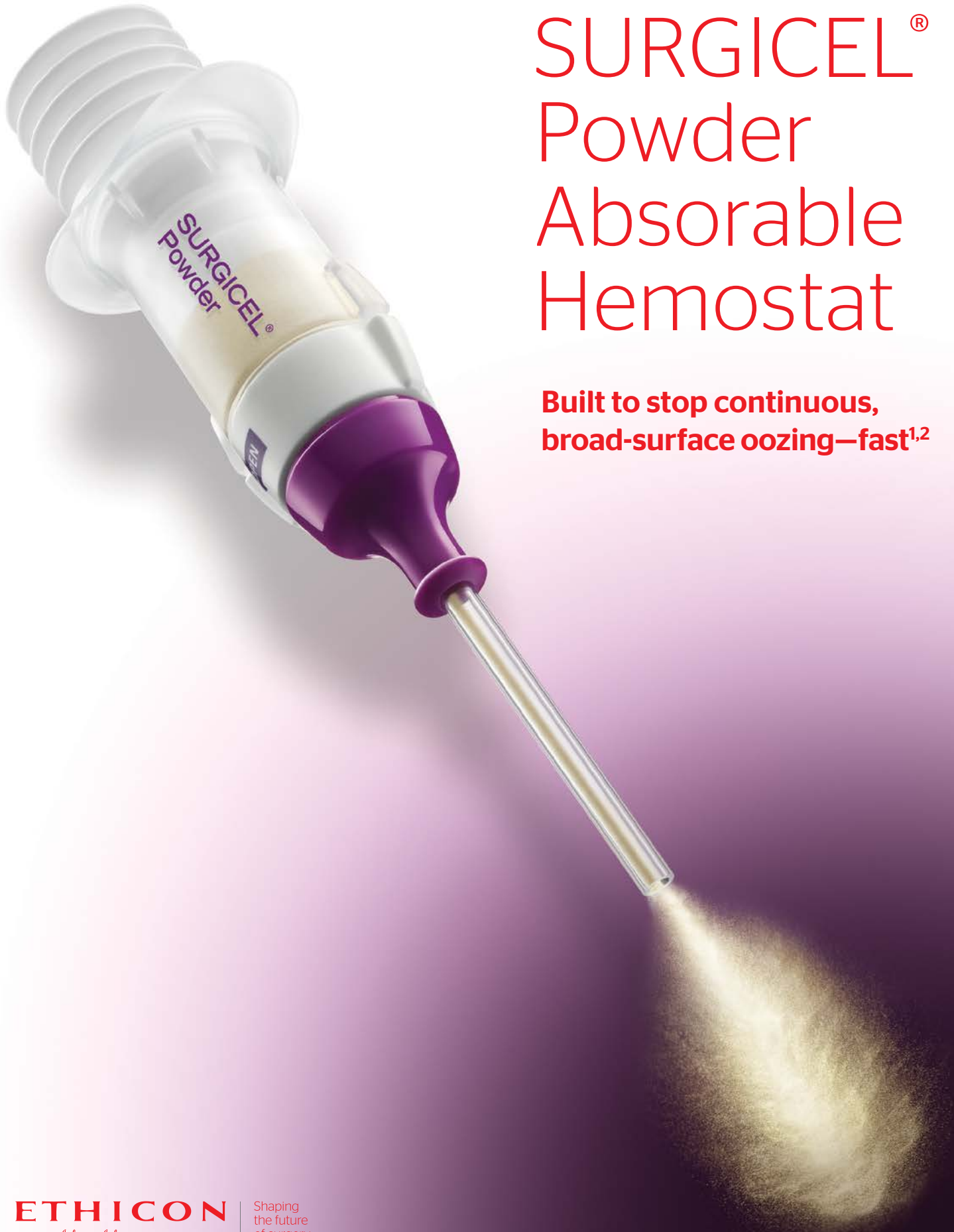MEST is a rare entity that can mimic other types of cystic renal lesions. Even though the course is usually benign, it should be carefully assessed due to possible malignant transformation. Treatment with a robot-assisted approach is feasible and partial nephrectomy, when possible, provides the best outcome for the patient.

## References

1. Adsay NV, Eble JN, Srigley JR, Jones EC, Grignon DJ. Mixed epithelial and stromal tumor of the kidney. *Am J Surg Pathol*. 2000;24(7):958–70.
2. Turbinder J, Amin MB, Humphrey PA, Srigley JR, De Leval L, Radhakrishnan A, et al. Cystic nephroma and mixed epithelial and stromal tumor of kidney: a detailed clinicopathologic analysis of 34 cases and proposal for renal epithelial and stromal tumor (REST) as a unifying term. *Am J Surg Pathol*. 2007;31(4):489–500.
3. Michal M, Syrucek M. Benign mixed epithelial and stromal tumor of the kidney. *Pathol Res Pract*. 1998;194(6):445–8.
4. Michal M, Hes O, Bisceglia M, Simpson RH, Spagnolo DV, Parma A, et al. Mixed epithelial and stromal tumors of the kidney. A report of 22 cases. *Virchows Arch*. 2004;445(4):359–67.
5. Ye J, Xu Q, Zheng J, Wang SA, Wu YW, Cai JH, et al. Imaging of mixed epithelial and stromal tumor of the kidney: a case report and review of the literature. *World J Clin Cases*. 2019;7(17):2580–6.
6. Lane BR, Campbell SC, Remer EM, Fergany AF, Williams SB, Novick AC, et al. Adult cystic nephroma and mixed epithelial and stromal tumor of the kidney: clinical, radiographic, and pathologic characteristics. *Urology*. 2008;71(6):1142–8.
7. Park HS, Kim SH, Kim SH, Paik JH, Hwang SI, Jung SI, et al. Benign mixed epithelial and stromal tumor of the kidney: imaging findings. *J Comput Assist Tomogr*. 2005;29(6):786–9.
8. Kim KA, Choi JW, Park CM, Lee CH, Lee JH, Yoon DK, et al. Unusual renal cell carcinomas: a pictorial essay. *Abdom Imaging*. 2006;31(2):154–63.
9. Chu LC, Hruban RH, Horton KM, Fishman EK. Mixed epithelial and stromal tumor of the kidney: radiologic-pathologic correlation. *Radiographics*. 2010;30(6):1541–51.
10. Mohd Zam NA, Lau WK, Yip SK, Cheng CW, Tan PH. Mixed epithelial and stromal tumour (MEST) of the kidney: a clinicopathological report of three cases. *Pathology*. 2009;41(4):403–6.

11. Rao HD, Sriram S, Srinivas BH, Challa S, Reddy R, Murthy P. Mixed epithelial stromal tumor of the kidney. *Indian J Urol.* 2011;27(2):284–7.
12. Horsanali MO, Yilmaz Y, Ozer K, Kose O, Cakalagaoğlu F, Etit D. Mixed epithelial and stromal tumor of the kidney: two case reports of a rare benign kidney tumor. *Clin Genitourin Cancer.* 2017;15(1):e55–e9.
13. Chuang CK, Pan PY, Kao Y, Chou YC, Ng KF, Wang LJ, et al. Mixed epithelial stromal tumor of the kidney: the male case and literature review. *Urol Case Rep.* 2018;17:122–4.
14. Aboumarzouk OM, Stein RJ, Eyraud R, Haber GP, Chlosta PL, Somani BK, et al. Robotic versus laparoscopic partial nephrectomy: a systematic review and meta-analysis. *Eur Urol.* 2012;62(6):1023–33.
15. Zeuschner P, Greguletz L, Meyer I, Linxweiler J, Janssen M, Wagenpfeil G, et al. Open versus robot-assisted partial nephrectomy: a longitudinal comparison of 880 patients over 10 years. *Int J Med Robot.* 2020:e2167.





# SURGICEL<sup>®</sup> Powder Absorbable Hemostat

**Built to stop continuous,  
broad-surface oozing—fast<sup>1,2</sup>**

# Endoscopic Submucosal Dissection as a Treatment for Early Gastric Cancer: A Case Report

**Martin Zaplotnik, Sebastian Stefanović, Samo Plut, Luka Strniša, Aleksandar Gavrić**  
*Department of Gastroenterology, Ljubljana University Medical Center*

## CORRESPONDENCE

Luka Strniša, MD  
luka.strnisa@gmail.com

## KEY WORDS

early gastric cancer, endoscopic submucosal dissection, endoscopic mucosal resection, bleeding, perforation, surgery, histopathological examination, long-term outcomes

## CASE REPORT

SURGERY SURG ENDOS 2021; 3(1): 33-38

## Abstract

Endoscopic submucosal dissection is an alternative technique for the removal of early gastric cancer. Absolute indications for endoscopic resection of early gastric cancer were established by the Japanese Gastric Cancer Association and have been generally accepted. However, the absolute indications for treating early gastric cancer are rather strict, and therefore expanded indications have been developed. Many studies have reported favorable long-term outcomes for patients that received curative resection for expanded indications. Endoscopic submucosal dissection preserves the stomach, thereby improving patients' quality of life compared to surgery. However, a generally higher incidence of metachronous gastric cancer has been reported after endoscopic resection. Therefore, surveillance endoscopy is indicated after curative endoscopic resection. We present the case of a 75-year-old woman with a 75 × 45 mm T1b1 gastric cancer successfully resected with endoscopic submucosal dissection.

## Introduction

The widespread use of gastrointestinal endoscopy has increased detection of early neoplastic lesions of the gastrointestinal tract. Although these lesions are precancerous in most cases, invasion can be excluded only after an adequate endoscopic resection. Endoscopic biopsies do not appear to be suitable for appropriate estimation of the malignant potential of lesions, as shown by the substantial rate of histological upstaging in the passage from biopsies to resected specimens. Endoscopic resection has also been shown to be an adequate treatment for patients with early gastrointestinal cancers with no or limited submucosal involvement and no additional risk factors. Most superficial gastrointestinal neoplasia may be treated by endoscopic mucosal resection (EMR). EMR is unsuitable for en bloc resection of lesions > 20 mm or non-lifting lesions because it does not

permit adequate histological examination of early cancers. To overcome these limitations, endoscopic submucosal dissection (ESD) has been developed, which allows en bloc resection of lesions > 20 mm. However, ESD is technically demanding with a steep learning curve, and it is associated with a higher risk of adverse events (1).

Curative endoscopic resection of early gastric cancer (EGC) can be achieved only in selected patients, depending on the histopathological type, size, and depth of invasion, and whether ulceration is present or not (2, 3). In general, endoscopic resection should be carried out when the likelihood of lymph node metastasis is low, and the lesion size and site are amenable to resection en bloc (1, 2).

The absolute indications include differentiated EGCs < 20 mm in diameter without ulceration or scarring; moreover, these lesions must be confined to the mucosa, with no lymphatic or vascular involvement (1–3). ESD has shown advantages over conventional endoscopic mucosal resection for the removal of larger lesions with achieving higher rates of en bloc resection and lower rates of residual disease and local recurrence (3). Thus, expanded indications have been developed: 1) differentiated mucosal cancers without ulcerative findings, regardless of tumor size; 2) differentiated mucosal cancers with ulcerative findings < 30 mm; 3) differentiated minute (< 500  $\mu$ m from the muscularis mucosa) submucosal invasive cancers < 30 mm; and 4) undifferentiated mucosal cancers without ulcerative findings < 20 mm, with no lymphatic or vascular involvement (1, 2, 3).

Evaluation of curability is based on local factors and risk factors for lymph node metastasis. If the risk of lymph node metastasis is less than 1% and 3% in pT1a and pT1b cancers, respectively, we assume that similar outcomes can be achieved with ESD or surgical resection. The risk of incomplete resection is higher for lesions with expanded indications resected with EMR, and ESD should be therefore considered the endoscopic resection method of choice for these lesions (2).

Bleeding and perforation are the most common complications, and most of the time they are managed endoscopically without the need for surgical intervention (1). Other reported complications that are noteworthy, although their incidences are low, include stricture, pneumonia, and air embolism (2).

Intraprocedural bleeding is very common during ESD (1, 2) and can be managed endoscopically in

most cases. As a general rule, if large vessels are observed they should be coagulated before proceeding with the dissection (1). Bleeding can initially be controlled with the knife in coagulation mode, and if this fails then coagulation forceps should be used. The use of hemoclips during the procedure should be avoided in the dissection area because this may compromise further dissection. If a bleed cannot be controlled by the coagulation forceps, dissection around the bleeding point should be performed before placing a hemoclip to fully expose the bleeding point and to allow further and complete dissection of the lesion (1, 2). Delayed bleeding occurs in up to 10% of ESDs (1). Visible vessels should be routinely coagulated after dissection because this has been shown to significantly reduce the risk of delayed bleeding from 7.4 to 3.2% (1, 2). However, caution is required because excessive vessel coagulation may increase the risk of delayed perforation. Furthermore, a proton-pump inhibitor should be prescribed following ESD, similar to peptic ulcer therapy (2). If delayed bleeding occurs, this should be handled using the standard methods of endoscopic hemostasis (ideally with hemoclips) and rarely by surgery (1).

Perforations occur rather uncommonly during gastric ESD, at an approximate rate of 1 to 4%. When visible perforation occurs, clear visualization must first be obtained (eventually with further dissection) while minimizing air insufflation (1). Then complete closure of the perforation must be achieved with the application of hemoclips or other closure devices (1, 2). Complete dissection and removal of the entire lesion should be attempted. If necessary, exsufflation of peritoneal air should be performed to reduce post-ESD complications and pain (1). If endoscopic clip closure is successful, the patient can be managed conservatively, with fasting and a nasogastric tube along with broad-spectrum antimicrobial therapy. Although conservative management and careful follow-up are often successful, if the perforation cannot be closed or if peritonitis is suspected despite apparent closure, a surgeon should be consulted on the need for surgical management (2).

Evaluation of the degree of likelihood of cure after ESD is carried out through histopathological examination of the resected specimen, based on which subsequent treatment is decided. When the procedure is considered likely to have been curative, the patient should be carefully observed, bearing in mind the possibility of a residual or



recurrent tumor and the development of metachronous cancer. The cumulative 3-year risk of metachronous gastric cancer after ESD is approximately 5.9%. Even when histopathological examination has indicated curative resection, follow-up with esophagogastroduodenoscopy at intervals of 6 to 12 months is desirable, with the main aim of detecting metachronous gastric cancers. When histopathological examination indicates expanded indication curative resection, follow-up with esophagogastroduodenoscopy, as well as ultrasonography or CT scanning for detection of metastases, is desirable at intervals of 6 to 12 months. When histopathological assessment indicates non-curative resection not requiring surgical resection, observation without further treatment is indicated. Endoscopic surveillance with biopsies is recommended at 3 and 9 to 12 months and then annually (1, 2).

## Case Report

A 75-year-old woman with arterial hypertension, glaucoma, osteoporosis, and postcholecystectomy was admitted to our department in June 2020 for scheduled ESD of a large gastric polyp.

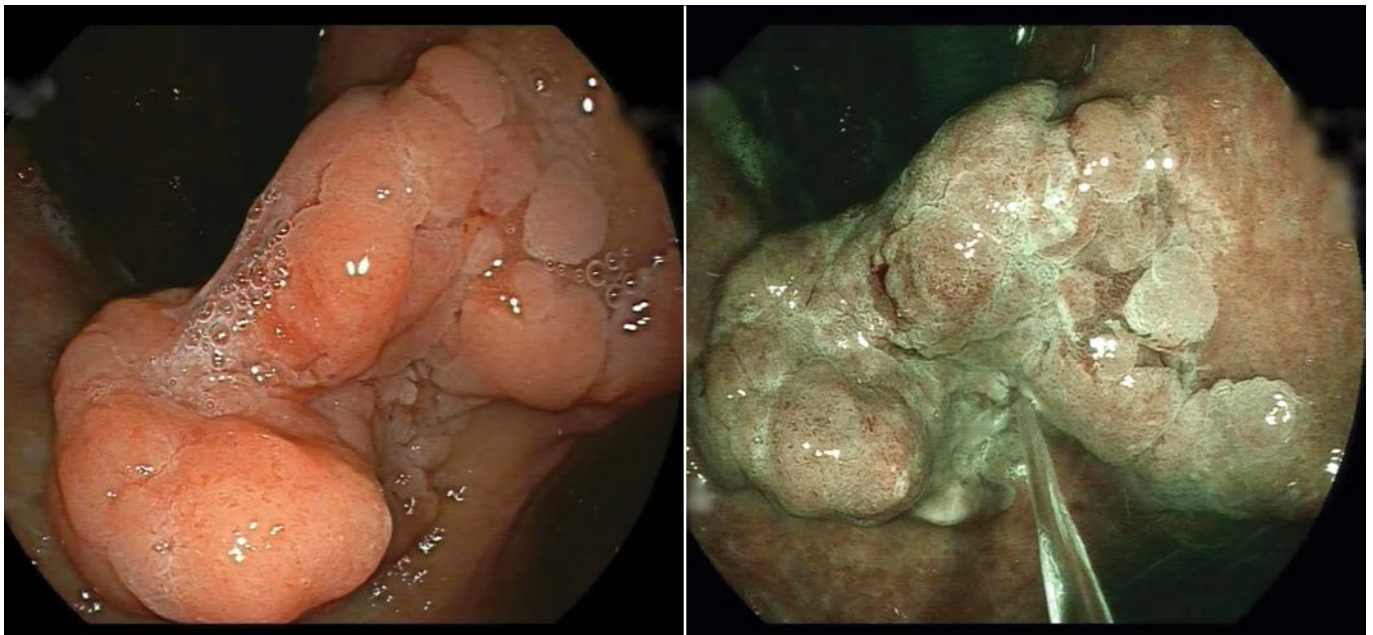
Before admission, the patient presented with a 6-month history of gastroesophageal reflux dis-

ease symptoms, weight loss, and constipation. Esophagogastroduodenoscopy had already been performed and showed a large sessile polyp located on the gastric angular incisure (Figure 1). Assessment under white light and narrow-band imaging did not reveal suspicious signs of invasion. The histopathological results of the biopsy samples revealed tubular adenoma with low-grade dysplasia and concurrent *Helicobacter pylori* infection. She received eradication therapy for *Helicobacter pylori*. ESD removal of the polyp was advised.

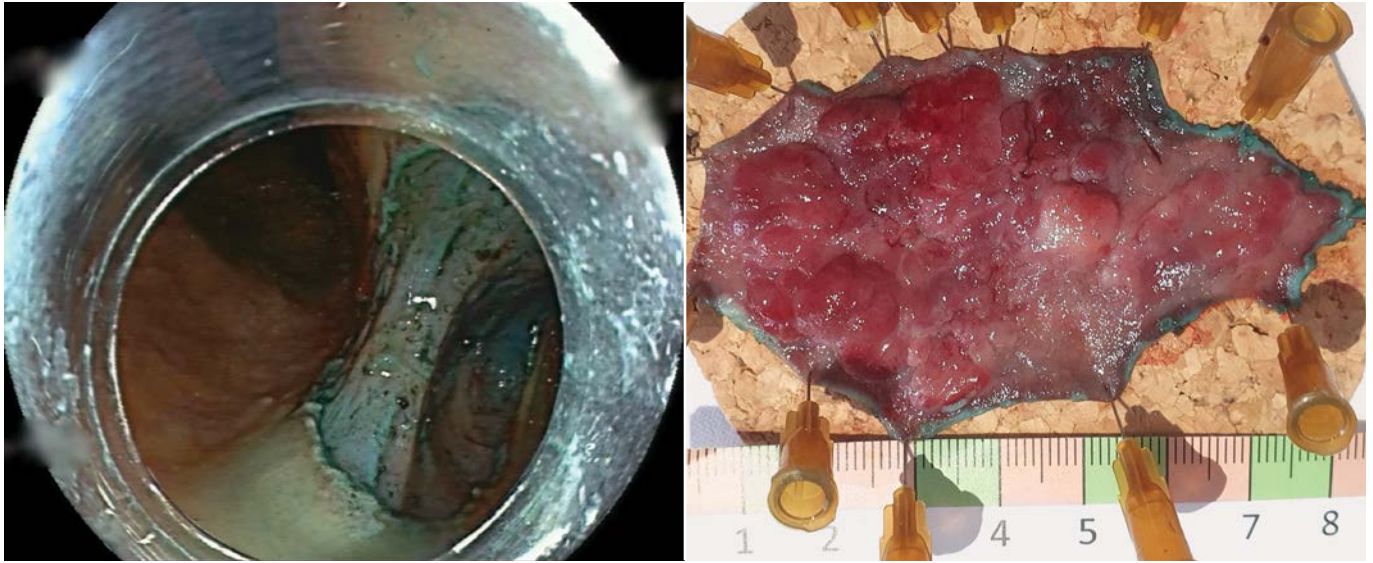
The laboratory data on admission showed normocytic anemia with hemoglobin 96 g/l; other blood parameters were within normal range. Before the procedure, a thoracic and abdominal CT scan and endoscopic ultrasound did not show any signs of deep invasion or metastasis of the lesion.

Esophagogastroduodenoscopy under propofol anesthesia was performed, and it confirmed a 75 × 45 mm, 0-Is lesion above the angular incisure without signs of ulceration. The entire lesion was removed in one piece with ESD (Figure 2). A hemoclip was then applied on the deep mural injury (Sidney II) site identified during the ESD. Histopathological analysis of the lesion removed revealed well-differentiated intestinal-type adenocarcinoma, stage T1b1 with a vertical margin less than 0.1 mm deep. There was no lymphovascular invasion. After the procedure, hematemesis

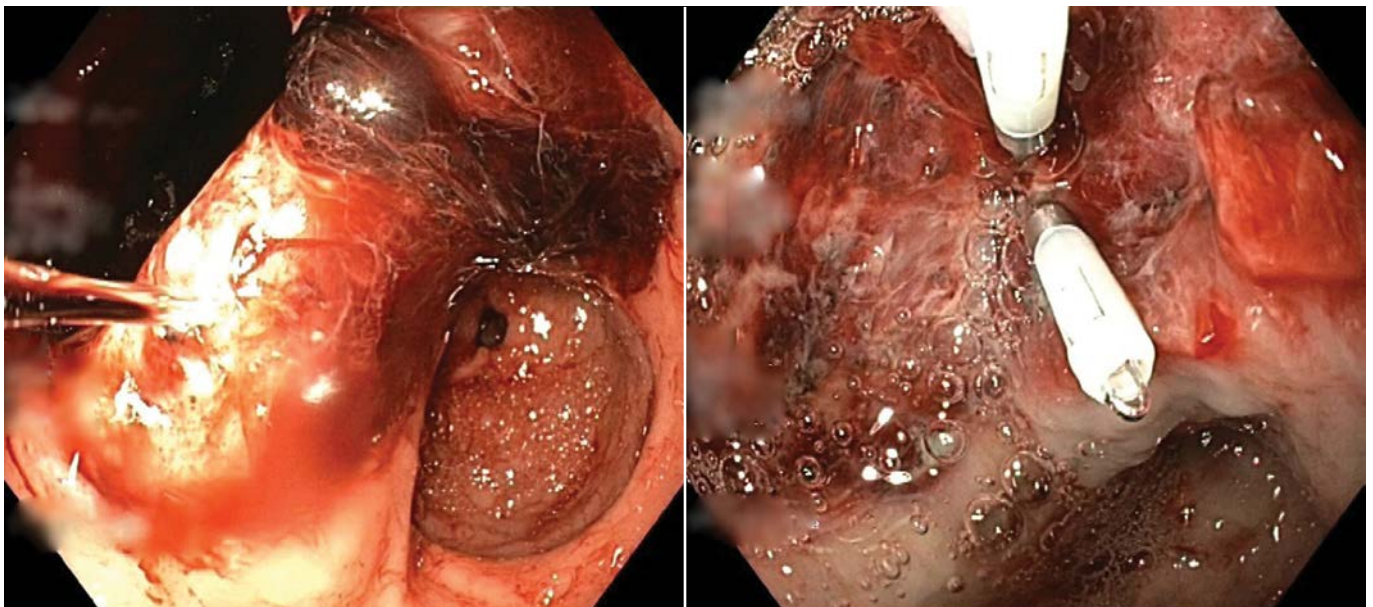
**Figure 1.** A large sessile polyp is seen on gastric angular incisure. Assessment under white light and narrow band imaging did not reveal suspicious signs of invasion.



**Figure 2.** The entire lesion was removed in one piece with endoscopic submucosal dissection.



**Figure 3.** Bleeding from the dissected area was revealed on emergency esophagogastroduodenoscopy, which was stopped with two hemoclips and adrenaline application.



occurred, and consequently emergency esophagogastroduodenoscopy was performed. Bleeding from the dissected area was seen (Figure 3). Hemostasis was successfully achieved with two hemoclips and adrenaline application. The subsequent abdominal X-ray did not show any signs of perforation.

During the course of hospitalization, the patient became dyspneic. CT angiography showed a small segmental pulmonary embolism in the right upper lung lobe. Ultrasound for the lower extremities excluded the presence of deep vein throm-

bosis. No anticoagulation therapy was indicated. Before discharge, the patient received two units of packed red blood cell transfusions and was prescribed proton pump inhibitors.

The case was presented at the multidisciplinary team meeting which—having taken into account the depth of the invasion and close resection margins and estimated a 3 to 4% chance of lymph node metastasis—advised additional surgical treatment. The patient underwent subtotal gastrectomy with D1 lymphadenectomy resection. No cancer remnant was identified in the



histological analysis of the surgical specimen. However, high-grade dysplasia was revealed on the edges of the post-ESD ulcer. All 11 lymph nodes were without malignant infiltration. No adjuvant chemotherapy was indicated. The patient was contacted 6 months after the ESD and was feeling well except for persisting symptoms of discomfort in the upper abdomen.

## Discussion

The available literature suggests that the long-term outcomes of ESD for EGC are favorable. Compared to surgery, the benefits of ESD include a lower complication rate and shorter length of hospital stay. ESD preserves the stomach, thereby improving patients' quality of life compared to surgery, but generally a higher incidence of metachronous gastric cancer has been reported after ESD for EGC. Indeed, our patient underwent surgical resection due to the depth of the vertical invasion (pT1b). Considering the size and differentiation, our patient fulfilled the expanded criteria. Even though there was no cancer in the surgical specimen, histological analysis of the surgical specimen revealed high-grade dysplasia on the edges of the post-ESD ulcer. We can hypothesize that this could be potentially a cause for metachronous gastric cancer after curative ESD. We believe that meticulous inspection prior to ESD to identify edges of the dysplastic adenoma is of the utmost importance because it makes possible removal not only of the early gastric cancer but also the surrounding dysplastic mucosa. On the other hand, because local recurrence can be treated by ESD if the lesion is detected early enough, post-ESD endoscopic surveillance is indicated.

A systematic review and meta-analysis assessed the application of expanded indications by comparing outcomes between absolute and expanded indication groups. The expanded indication group had lower rates of en bloc resection (93.6% vs. 97.0%,  $p < 0.0001$ ) and complete resection (87.8% vs. 95.8%,  $p < 0.00001$ ) compared to the absolute indication group. Local recurrences rates were lower in the absolute indication group compared to the expanded indication group (0.6% vs. 1.5%,  $p = 0.03$ ). There were no significant differences between the two groups in gastric-specific mortality and overall mortality. The 5-year disease-specific survival rate was 99.9% for patients

with absolute indication lesions, and 99.9% for differentiated lesions with expanded indications. The 5-year disease-specific survival rate for undifferentiated cases after curative ESD was 97.5%. These findings indicate that the expanded indications for undifferentiated EGC are reasonable. Of note, patients with non-curative ESD should undergo additional surgery because the malignant potential is much higher in undifferentiated EGC. Fukunaga et al. evaluated the long-term outcomes for patients with expanded indications for differentiated EGC that underwent ESD or surgical resection. After propensity score matching, the 5-year overall survival rate was higher in the ESD group compared to the surgery group (97.1% vs. 85.8%,  $p = 0.01$ ) (3).

On the other hand, patients with intractable disease cannot undergo surgery due to high operation risk. Palliative ESD for lesions beyond expanded indication might be considered as a treatment option for patients with intractable disease in the future.

Another point for discussion is the definition of complete pathological R0 resection of the ESD specimen. While in surgery, a margin of at least 1 mm is necessary to fulfil R0 resection, and in endoscopy a narrow margin was proposed of at least 0.1 mm. Because our patient had a vertical resection margin  $< 0.1$  mm, the multidisciplinary council indicated adjuvant surgical resection. Even though there were no cancer cells in the surgical specimen, high-grade dysplasia was identified on the edges of the post-ESD ulcer. This focus of dysplasia is worrisome because it can lead to development of metachronous cancer. On the other hand, endoscopic surveillance is indicated after ESD to discover potential neoplastic lesions that can be removed by subsequent endoscopic resection.

Unfortunately, our patient developed massive bleeding after the ESD, but endoscopic hemostasis was successfully achieved. The key to improving therapeutic outcomes for EGC is early detection and accurate diagnosis. Early detection of gastric cancer or a precancerous lesion is essential for curative ESD. Recently, several advances in diagnostic endoscopy, including narrow-band imaging and magnifying endoscopy, have allowed improvements in lesion characterization by detailed imaging of the microvascular pattern and mucosal surface structures. Moreover, identifying a precise demarcation line is indispensable

for pathological en bloc resection. Over the past decades, refinements in ESD techniques, instruments, and devices have been achieved. Further development of training systems will promote world-wide standardization of gastric ESD (3). In addition to improving ESD techniques, we should also focus on identifying individuals that are at risk for gastric cancer so they can be involved in endoscopy surveillance programs.

## Conclusion

ESD has been widely accepted and is used for the treatment of EGC with a low risk of lymph node metastasis (2). These findings indicate that ESD is an effective treatment modality for EGC. However, the results of all studies were obtained from retrospective studies. Thus, a prospective multicenter study with a long follow-up is required for a more precise evaluation of the long-term outcomes of gastric ESD (3). In endoscopic practice in eastern countries, detection of an increasing proportion of EGC among all gastric cancers has been achieved owing to nationwide screening programs and advances in endoscopic knowledge and technologies. On the other hand, in western countries ESD has disseminated slowly because it is a technically difficult procedure requiring a high level of endoscopic training and skills. In addition, the incidence of EGC in western countries is considerably lower compared to eastern countries. As a consequence, training is much slower in the west due to the low volume of appropriate cases. In addition to improving the ESD technique, strategies for improving the detection rate of EGC in western countries should be among the priorities.

## References

1. Pimentel-Nunes P, Dinis-Ribeiro M, Ponchon T, et al. Endoscopic submucosal dissection: European Society of Gastrointestinal Endoscopy (ESGE) guideline. *Endoscopy*. 2015;47:829–54.
2. Ono H, Yao K, Fujishiro M, et al. Guidelines for endoscopic submucosal dissection and endoscopic mucosal resection for early gastric cancer. *Digestive Endoscopy*. 2016;28:3–15.
3. Nishizawa T, Yahagi N. Long-term outcomes of using endoscopic submucosal dissection to treat early gastric cancer. *Gut Liver*. 2018;12(2):119–24.

# How I Do It: Laparoscopic Gastrectomy for Gastric Adenocarcinoma Using the Livsmed® Surgical System

**Tomaž Jagrič**

Department of Abdominal and General Surgery, Maribor University Medical Center

## CORRESPONDENCE

Asst. Prof. **Tomaž Jagrič**, MD, PhD  
tomaz.jagric@gmail.com

## KEY WORDS

laparoscopic gastrectomy,  
LivsMed®

## How I Do It

SURGERY SURG ENDOS 2021; 3(1):  
39-44

## Abstract

**Aim:** This article presents the first experience with laparoscopic gastric cancer resection using the LivsMed® surgical platform.

**Methods:** A laparoscopic subtotal gastrectomy was performed. The LivsMed® surgical platform was used for dissection of the no. 6 lymph node station.

**Results:** The extensive angulation of the LivsMed® surgical system allowed a completely bloodless dissection of the lymph node station and easy identification of vascular structures. Patient recovery was uneventful. The patient was discharged on day seven.

**Conclusion:** The LivsMed® surgical system has provided a new benchmark for laparoscopic surgery at our center, compensating for shortcomings in laparoscopy compared to robotic surgery without extending the operation or the costs of the operation.

## Introduction

Gastric cancer is a serious public health issue. It is the fourth most common cancer in the world, and it ranks as the sixth most common cancer in Slovenia (1–4). In some regions of Slovenia such as Carinthia or the Mura Valley, the incidence of gastric cancer approaches that of Asian countries, where gastric cancer is the most common cancer (4). The high incidence and poor long-term prognosis have prompted enthusiastic research in gastric cancer treatment. Advances in diagnostics have made earlier tumor detection possible, and advances in oncological treatment have improved the overall long-term results (1–4).

Until recently, the dictum has prevailed that only a total gastrectomy and only open surgery can cure gastric cancer. The development of new surgical techniques has made it possible for quality surgery to be performed with much less invasiveness,

thus allowing patients faster and more pain-free recovery with better short-term functional results (5–15).

The Department of Abdominal and General Surgery at the Maribor University Medical Center was the first center to introduce laparoscopic gastric cancer surgery in Slovenia (1, 2). Since then, our results in laparoscopic gastric surgery have been outstanding and comparable to the most experienced centers in the world (2, 5–15). We are now performing laparoscopic surgery on almost half of all newly diagnosed gastric cancer patients, and we are still pushing the boundaries in laparoscopic gastric cancer surgery.

Robotic surgery is considered the next natural step in the development of laparoscopic gastric cancer surgery. Robotic surgery makes a demanding laparoscopic procedure easier. The three-dimensional view allows a more immersive experience and provides means to discern even the smallest vascular and lymphatic structures (3). This in turn lessens unnecessary tissue trauma and postoperative inflammation, and in theory it expedites postoperative patient recovery. However, the main advantage of robotic surgery is the endo-wristed instruments. This allows the surgeon to access structures that are at a right angle to the axis of the instruments. The robotic surgery thus increases dexterity and stability during the operation, and in addition the surgeon can operate in a more ergonomic position. The procedure offers less strain for the surgeon, which means that fewer mistakes will be made during the procedure (3). The flexible instruments can mimic the joints of the surgeons' hand. More complex maneuvers can be performed in robotic surgery thanks to these instruments. However, the extremely high price of such robotic platforms makes them unavailable for most medical centers in Slovenia.

We have therefore searched for new and more cost-effective solutions to compensate for the disadvantages of laparoscopic surgery. We have introduced a new surgical platform called LivsMed®. The LivsMed® instruments can be used during laparoscopic surgery and do not require complex docking systems. The instruments are equipped with a joint that allows articulation of the instrument that is paralleled only by robotic instruments. This article therefore presents the first experience with laparoscopic gastric cancer resection using the LivsMed® surgical system.

## Methods

We performed a laparoscopic subtotal gastrectomy. The LivsMed® surgical platform was used for dissection of the no. 6 lymph node station.

### Patient Positioning

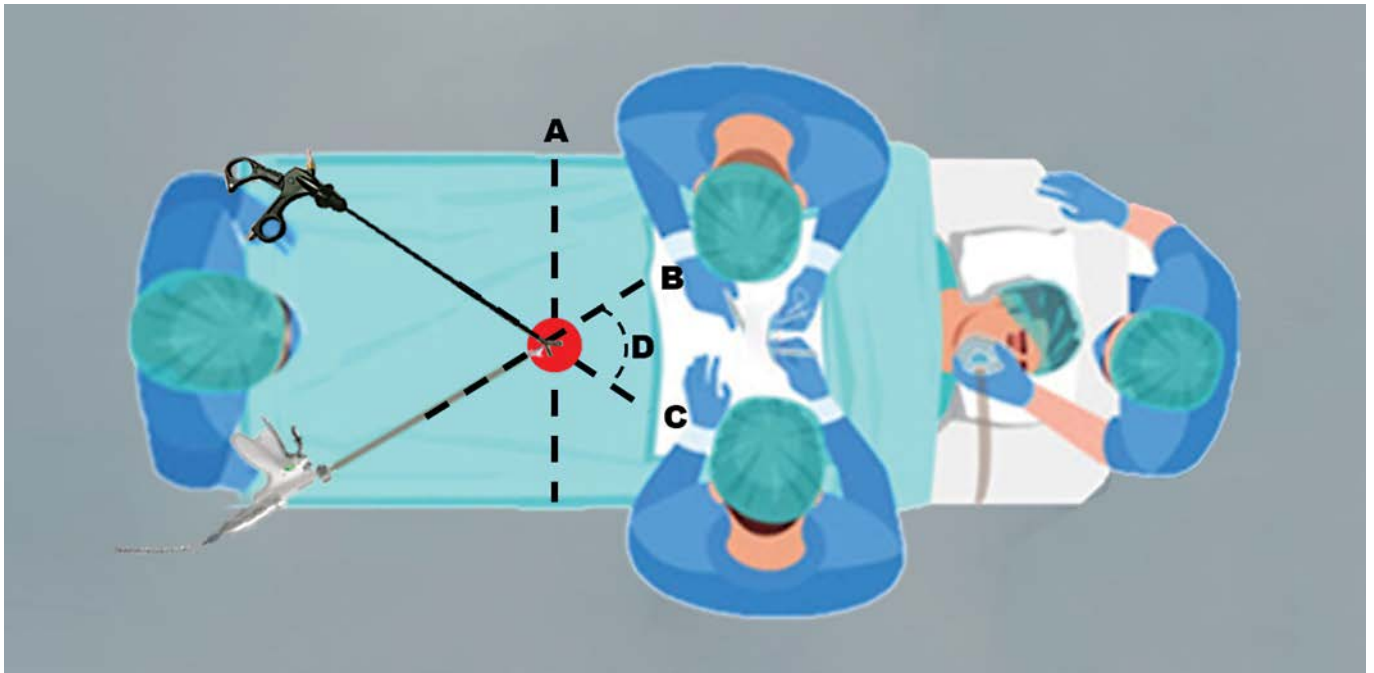
The patient was placed in a supine position with the arms and legs abducted. We used the standard operating room setup. The monitor was placed at the head of the table. The operator's position alternated between the legs of the patient and on the right side of the patient. The assistant was on the left side of the patient, and the camera operator was between the legs. The scrub nurse was placed on the right side of the patient between the operator and the camera operator. The LivsMed® surgical system was used for dissection of the no. 6 lymph node station. During this step, the surgeon was between the patients' legs. In this position, the surgeon obtained the best angles for the dissection of lymph nodes around the right gastroepiploic vein and artery. The schematic position of the surgeon during the dissection of the no. 6 lymph node station is shown in Figure 1. Pneumoperitoneum was established with the Veress needle, and a continuous intraabdominal pressure of 12 mmHg was sustained during the entire procedure.

### Operation

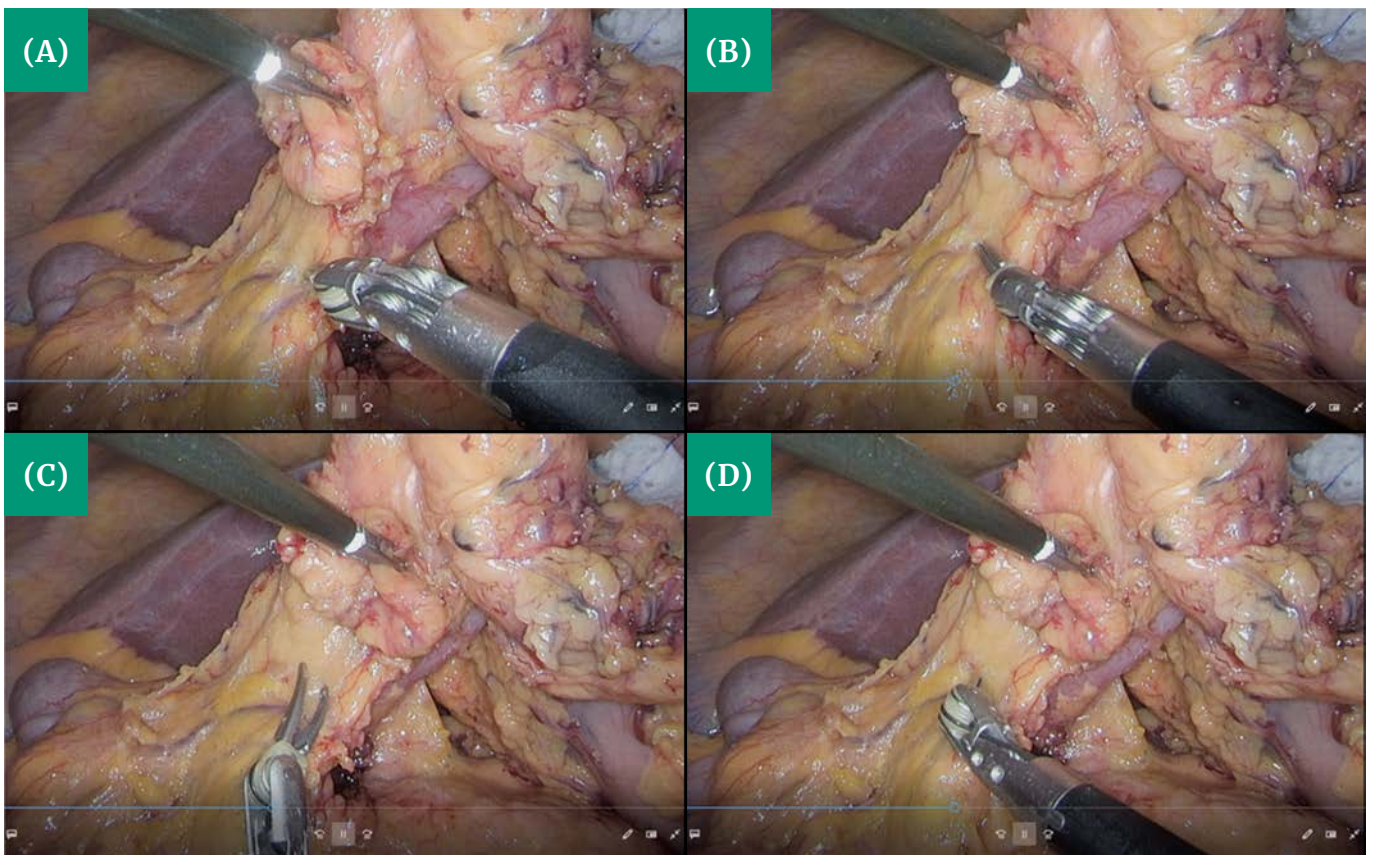
After establishing pneumoperitoneum, four working ports were placed in standard position. The liver was mobilized and fixed with two holding sutures. One suture was placed through the falciform ligament, and the other fixed the left liver lobe. In this fashion, no additional manipulation of the liver was needed.

The dissection of the stomach followed standard steps as described elsewhere (2, 16, 17). After mobilization of the posterior stomach wall, the duodenum was lifted by the first assistant, making the retroduodenal space visible. The following steps were performed with the LivsMed® surgical system. First, the retroduodenal part of the gastroduodenal artery was dissected, visualizing its proximal part with the base of the right gastric artery cranially and the right gastroepiploic





**Figure 1.** Operating team positioning and dissection angles during no. 6 lymph node station dissection: A) ideal angles for no. 6 lymph node station dissection; B) harmonic scalpel axis; C) grasper axis; D) the angle between the grasper and the harmonic scalpel is 60°.



**Figure 2.** Gradual angulation of the LivsMed® surgical system during vessel dissection: A) with the LivsMed® grasper the vessel is approached at a right angle; B) turning the tip of the LivsMed® grasper cranially; C) dissection of the lymph nodes away from the head of the pancreas; D) the LivsMed® graspers extend the reach up to the duodenal loop.



artery caudally. On the lateral side of the duodenal loop the retroperitoneal adhesions were freed, a partial Kocher's maneuver was performed, and the hepatic flexure was dissected free, leaving the duodenum exposed and completely mobilized. The next steps entailed lifting the lymph nodes from the pancreatic head. During this step, the surgeon angulated the dissector at almost 90°, making it unnecessary for the assistant to exert upward traction on the lymphatic tissue. The assistant's forceps were therefore free to perform additional tasks. In addition, the angle made the dissection between the artery and the vein much easier and safe because it reduced the possibility of inadvertent puncture of the vein. After both vessels were clipped, they were transected with impunity. Next, a window for duodenal transection was created behind the duodenum with the LivsMed® surgical system. Again, the system allowed better exposure of the retroduodenal space, where the surgeon's movement was limited by the narrow space. After duodenal tran-

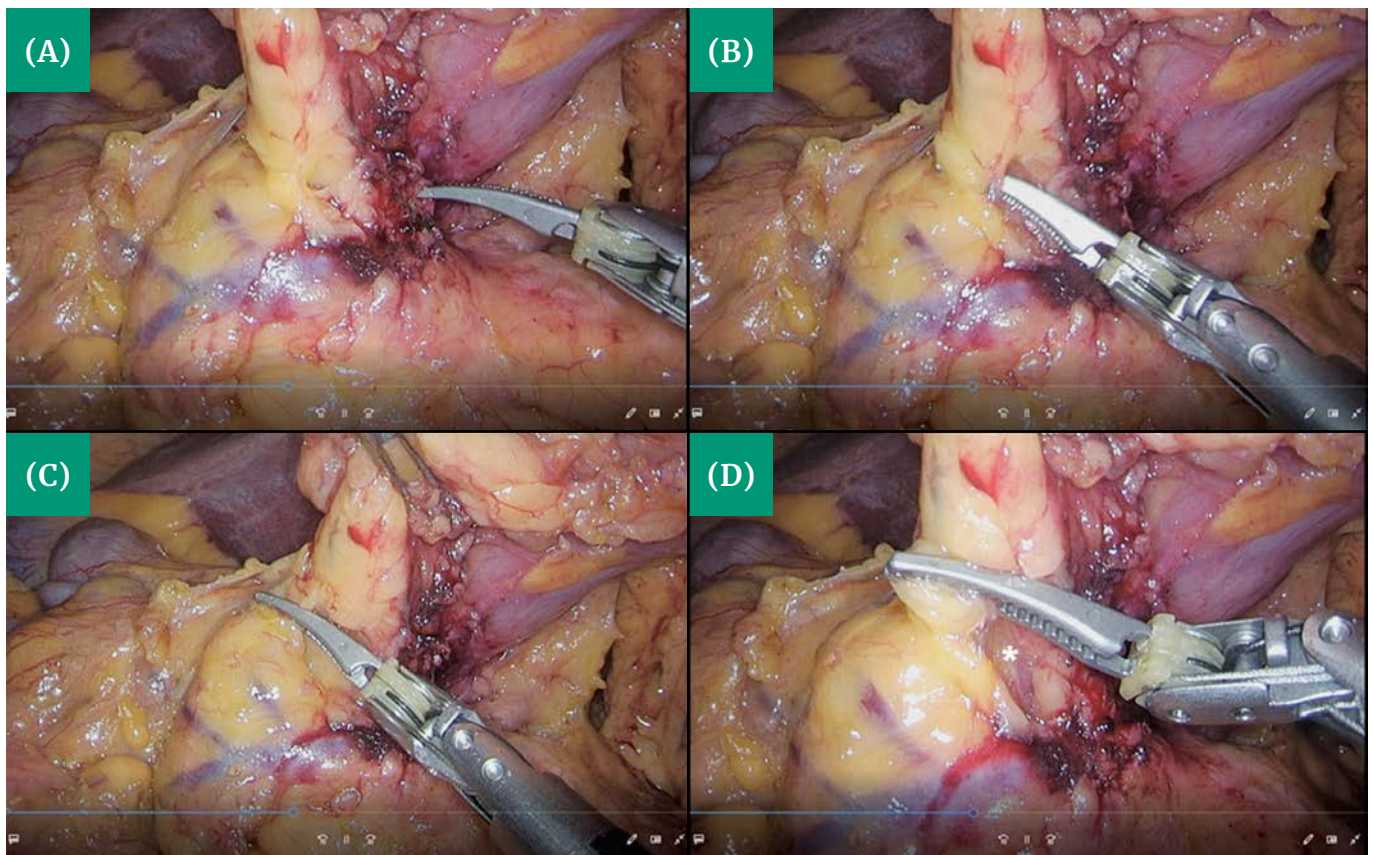
section, the subsequent steps were performed as described elsewhere (2, 16, 17).

### Postoperative Recovery

The postoperative recovery was uneventful. The patient started with clear liquids on day one after surgery, a liquid diet on day three, and a soft diet on day four. He was discharged on day seven.

## Discussion

Many prospective randomized controlled trials have shown laparoscopic gastric cancer surgery to be equivalent to open surgery for distal subtotal gastrectomy with better short-term results (5–15). Although laparoscopy has been embraced by the gastric cancer surgical community and



**Figure 3.** Dissection of the right gastroepiploic vein: A) coagulation with the monopolar LivsMed® grasper; B) with the LivsMed® grasper we can safely dissect the space in front of the right gastroepiploic vein; C) lifting the lymphatic and fatty tissue; D) dissection of vital structures. \*Base of the right gastroepiploic vein.

specialized centers have continued to gain experience, many obstacles still prevent this demanding surgery from gaining wider acceptance.

One reason for its slow implementation is the technical difficulties that surgeons face during surgery. The narrow surgical field, difficult dissection, and stiff laparoscopic instruments are mainly the reason why open surgery is still preferred for more demanding total gastrectomy and advanced gastric cancer (5–15). Robotic surgery has certainly made dissection easier, but the positioning of the patient, a slow learning curve, difficult intestinal reconstruction, longer operating times, and high medical costs prevent robotic surgery from replacing laparoscopic surgery for gastric cancer in the foreseeable future (3). Therefore, surgical systems have emerged that provide a relatively cheap solution for the lack of angulation of the laparoscopic instruments.

Our center decided to implement the LivsMed® surgical system due to its low cost and the superior angulation, which is comparable to robotic instruments. The advantage of the LivsMed® surgical system is that it can be liberally exchanged during the operation. Its lightweight construction does not additionally strain the surgeon. After a month of training on a surgery phantom box, the surgeon became proficient enough to smoothly perform the complicated movement necessary during laparoscopic gastric cancer resection. We decided to first implement the LivsMed® surgical system in no. 6 lymph node dissection. Because of the position of dissecting structures and the position of the surgeon, this lymph node station has the ideal properties for implementation of the LivsMed® surgical system. During the dissection, the surgeon intuitively placed the instrument at an angle of 90°, similar to the placement of surgical instruments during open surgery. The surgery thus obtained a new dimension, allowing more precise and faster dissection. Consequently, the dissection was performed in a completely bloodless field, lessening tissue trauma. The use of the LivsMed® surgical system did not prolong the operation time. This is a key advantage compared to robotic surgery, where exchanging the instrument, repositioning, and docking extends the operation time by at least 30 to 45 minutes.

The LivsMed® surgical system has provided a new benchmark for laparoscopic surgery at our center, compensating for the shortcomings of laparoscopy compared to robotic surgery with-

out extending the operation and the costs of the operation.

## References

1. Juvan J. Do želodca brez odpiranja trebuha [Internet]. Večer; 2015. Available from: <https://www.vecer.com/vecer-v-nedeljo/201507266131380-6131380>.
2. Jagric T. The impact of modifying the laparoscopic lymphadenectomy technique on the extent of lymphadenectomy in laparoscopically operated gastric cancer patients: a single-center study. *Surgery and Surgical Endoscopy*. 2019;1(1):19–25.
3. van Boxel GI, Ruurda JP, van Hillegersberg R. Robotic-assisted gastrectomy for gastric cancer: a European perspective. *Gastric Cancer*. 2019;22:909–19.
4. Zadnik V, Gašljević G, Hočevar M, Ivanuš U, Jarm K, et al. *Cancer in Slovenia 2017*. Ljubljana: Institute of Oncology Ljubljana, Epidemiology and Cancer Registry, Slovenian Cancer Registry; 2020.
5. Costantino CL, Mullen JT. Minimally invasive gastric cancer surgery. *Surg Oncol Clin N Am*. 2018;28(2):201–13.
6. Haverkamp L, Weijs TJ, van der Sluis PC, van der Tweel I, Ruurda JP, et al. Laparoscopic total gastrectomy versus open total gastrectomy for cancer: a systemic review and meta-analysis. *Surg Endosc*. 2013;27:2661–1.
7. Haverkamp L, Ruurda JP, Offerhaus GJA, Weijs TJ, van der Sluis PC, et al. Laparoscopic gastrectomy in western European patients with advanced gastric cancer. *EJSO*. 2016;42:110–15.
8. Straatman J, van der Wielen N, Cuesta MA, de Lange-de Klerk ESM, Jansma EP, et al. Minimally invasive versus open total gastrectomy for gastric cancer: a systematic review and meta-analysis of short-term outcomes and completeness of resection. *World J Surg*. 2015;40(1):148–57.
9. Wang W, Li Z, Tang J, Wang M, Wang B, Xu Z. Laparoscopic versus open total gastrectomy with D2 dissection for gastric cancer: a meta-analysis. *J Cancer Res Clin Oncol*. 2013;139:1721–34.
10. Park YK, Yoon HM, Kim YW, Park JY, Ryu KW, et al. Laparoscopy-assisted versus open D2 distal gastrectomy for advanced gastric cancer. *Ann Surg*. 2017;20(20):1–8.
11. Son T, Hyung WJ. Laparoscopic gastric cancer surgery: current evidence and future perspectives. *World J Gastroenterol*. 2016;22(2):727–35.
12. Son T, Kwon IG, Hyung WJ. Minimally invasive surgery for gastric cancer treatment: current status and future perspectives. *Gut Liver*. 2014;8(3):229–36.
13. Shi Y, Xu X, Zhao Y, Qian F, Tang B, et al. Long-term oncologic outcome of a randomized controlled trial comparing laparoscopic versus open gastrectomy with D2 lymph node dissection for advanced gastric cancer. *Surgery*. 2019;165(6):1211–16.

14. Best LMJ, Mughal M, Gurusamy KS. Laparoscopic versus open gastrectomy for gastric cancer (review). *Cochrane Library*. 2016;3:CD011389.
15. Ding J, Liao GQ, Liu HL, Liu S, Tang J. Meta-analysis of laparoscopy-assisted distal gastrectomy with D2 lymph node dissection for gastric cancer. *J Surg Oncol*. 2012;105:297–303.
16. Uyama I, Sugioka A, Matsui H, Fujita J, Komori Y, et al. Laparoscopic D2 lymph node dissection for advanced gastric cancer located in the middle of lower third portion of the stomach. *Gastric Cancer*. 2000;3:50–5.
17. Kayana S, Haruta S, Kawamura Y, Yoshimura F, Inaba K, et al. Video: laparoscopy distinctive technique for suprapancreatic lymph node dissection: medial approach for laparoscopic gastric cancer surgery. *Surg Endosc*. 2011;25(12):3928–9.



# Laparoscopic Living Donor Nephrectomy: Description of a Transabdominal Approach and Our Experience at the Ljubljana University Medical Center

**Milena Taskovska, Simon Hawlina**

*Department of Urology, Ljubljana University Medical Center*

*Department of Surgery, Faculty of Medicine, University of Ljubljana*

## CORRESPONDENCE

Asst. **Simon Hawlina**, MD, FEBU  
simon.hawlina@kclj.si

## KEY WORDS

kidney transplantation, living donor nephrectomy, laparoscopic surgery, minimally invasive surgery

## How I Do It

SURGERY SURG ENDOS 2021; 3(1):  
45-52

## Abstract

Kidney transplantation (KTx) is the most optimal treatment for end-stage renal disease (ESRD). The number of patients with ESRD is increasing globally, and so is the number of candidates for KTx. Because of the high demand for kidney grafts, in addition to cadaveric kidneys, living donor kidney donation is a very valuable option for these patients. Development of minimally invasive surgical techniques such as laparoscopy has made kidney donation from living donors more attractive because of a better cosmetic result after surgery, shorter hospitalization, decreased need for analgesia, and faster recovery after surgery. Minimally invasive procurement techniques are comparable regarding efficacy, graft quality, graft functioning, and complications with open surgery. The European Association of Urology recommends laparoscopic procurement of kidney grafts from living donors only at centers that have experience in laparoscopic renal surgery. Transabdominal laparoscopic living donor nephrectomy (LLDN) is widely accepted due to large working space and excellent anatomical relations. In Slovenia, living donor nephrectomies (LDNs) have been almost nonexistent since 2016. The main factor contributing to this situation was the relatively short waiting list for KTx. In 2016, the new minimally invasive technique, LLDN, was introduced in clinical practice. Since June 2016 we have performed six laparoscopic LDNs. In all cases, a parent donated a kidney to his or her child. The average age of donors was 55 years and the average age of recipients was 26.6 years. The average operation time of LLDN was 130 min, average warm ischemia time was 360 seconds, and average blood loss was less than 50 ml. In all cases, the left kidney was transplanted. In one case the recipient needed revision due to postoperative hemorrhage and other needed transplantectomy due to renal vein thrombosis. In all donors there was no Clavien–Dindo II–IV complication. The hospital stay was 2 days for donors and 7 to 20 days for recipients.



## Introduction

The number of patients with end-stage renal disease (ESRD) is increasing. The most efficient treatment for ESRD is kidney transplantation (KTx). Since the introduction of KTx and the first successful living donor KTx in 1954, the number of KTx has been increasing globally (1).

With an aging population, cadaveric organs are of poor quality and less successful in KTx. In order to improve the survival of transplanted organs, and to decrease the incidence of rejection and complications, KTx from living donors is an ideal scenario for ESRD patients. A kidney from a living donor could be retrieved in a traditional (open) approach or with a minimally invasive (laparoscopic) approach. According to the European Association of Urology (EAU) guidelines on KTx, endoscopic living donor nephrectomy is advised at centers experienced with laparoscopic surgery of the kidney (2).

## Epidemiology

According to data from IRODAT for 2018, Spain is the world leader in KTx from deceased donors, at 64.64 per million population (pmp), and Turkey and the Netherlands are leaders in KTx from living donors, at 37.50 and 32.43 pmp, respectively (3). Different countries have different policies regarding living kidney donation (4).

## Minimally Invasive Living Donor Nephrectomy

There are a few different minimally invasive approaches for minimally invasive living donor nephrectomy: the pure or hand-assisted transperitoneal or retroperitoneal approach, laparo-endoscopic single-site surgery, natural orifice transluminal endoscopic surgery-assisted (used extremely rarely), laparo-endoscopic single-site surgery, and the robotic-assisted transperitoneal or retroperitoneal approach (2).

The most widely accepted technique and the one on which there are the most data is transabdominal laparoscopic living donor nephrectomy (LLDN), which is presented here in greater detail.

## Patient Preparation and Planning

Evaluation of living kidney donors is necessary before considering one for kidney donation. Evaluation of renal function, comorbidities, and previous surgery is essential. Preoperatively, CT angiography is indicated to assess the anatomy of the kidney, renal vessels, and ureter. Complex vascular anatomy is not a contraindication for kidney donation per se. Surgeons should assess the vascular anatomy prior to surgery in order to plan not only kidney procurement but also transplant (1, 5).

During LLDN, a kidney that has “worse” function and simpler vascular anatomy is usually procured. Some surgeons prefer the left kidney over the right one because of the length of the renal vein (1).

The donor is admitted to the hospital 1 day prior to the planned surgery. One day before surgery, surgeons decide on bowel preparation. Fasting starts at midnight before surgery. Every donor receives thromboprophylaxis (compression stockings and low-molecular-weight heparin) until discharge from the hospital; in the case of complications, cardiovascular comorbidities, or obesity, thromboprophylaxis is continued for 30 days (1, 6). Preoperatively every patient receives one shot of antibiotic prophylaxis (guidelines differ regionally) (6).

## Informed Consent

The donor should be informed about the complications regarding the surgical procedure and long-term complications as a consequence of having a single kidney. The major complications during the surgery are uncontrolled bleeding (either arterial or venous), injury to the major vessels, injury to the bowel, injury to the nerves, and anesthesia and positioning-related complications. Minor complications are possible, such as infection (5–7). In the long term, the most common complications are increased blood pressure and proteinuria (6).

During the COVID-19 outbreak, the living donor program at our hospital was suspended because of the increased risk of complications related to possible COVID-19 infection. According to recommendations from the EAU renal transplantation guidelines panel applicable during the COVID-19 pandemic, LLDN is a low-priority procedure and

should be postponed. In the literature, there are no clear recommendations regarding testing potential organ donors for SARS-CoV-2; however, the EAU renal transplantation panel recommends evaluation of risk of exposure to SARS-CoV-2 (medical history and potential contacts with people with proven COVID-19 over the last 28 days) and PCR test for identification of SARS-CoV-2 performed on a naso- and oropharyngeal swab. In the case of a negative history and PCR test, organ retrieval can be performed. In the case of a positive PCR test, the donor and recipient should be informed about the risk of infection (8). If LLDN is considered during the COVID-19 pandemic, the donor and recipient should be informed about possible complications related to COVID-19 infection. Considering that data in this area are relatively scant, donors should be informed that unreported complications are possible (9).

## Patient Positioning

The donor is initially positioned in a supine position for intravenous access, induction of general anesthesia, intubation, insertion of a nasogastric tube, and insertion of a urinary catheter; the donor is then rotated into modified lateral decubitus position (45 to 60 degrees) for a right-sided nephrectomy and a strict lateral decubitus position for a left-sided nephrectomy. The operating table is flexed at the level of the umbilicus to extend the distance between the lower rib cage and anterior superior iliac spine. All potential pressure points are cushioned to prevent pressure-induced injury. To prevent injury to the brachial plexus, an additional axillary role can be positioned. The donor is secured with strips of cloth tape (1, 5, 6).

The operative field is prepped in a standard manner as for laparoscopic nephrectomy: from the mamillary line to the pubis, on the posterior to the posterior axillary line, and in front to the lateral margin of the contralateral rectus muscle (1, 6).

The surgical team is positioned on the abdominal side of the patient. The surgeon stands cranially and the first assistant caudally. The scrub nurse could be positioned on the same side as the surgeons or contralaterally. The laparoscopic cart with the monitor is placed behind the donor's back, facing the surgeons. The assistant is positioned on a step to prevent instrument collision (6).

## Trocars and Instruments

Standard LLDN is done through 5 and 12 mm ports, but there are data in the literature about using 3 or 3.5 mm ports (2). Use of small ports is exclusively for aesthetic reasons.

For a right-sided nephrectomy, five trocars are used: two 12 mm trocars (optic, endoGIA, and bipolar grasper) and three 5 mm trocars (monopolar scissors, suction device, and liver retractor grasper).

For a left-sided nephrectomy, four or five trocars are used: two 12 mm trocars (optic, bipolar grasper, and 10 mm clip applier) and two 5 mm trocars (monopolar scissors and suction device) (6).

## Access

In the case of previous intra-abdominal surgery, open access is preferred. The first trocar is inserted using the open (Hasson) technique.

In case of a "virgin" abdomen, the blind technique of insufflation with a Veress needle is used. A cutaneous incision is made two fingerbreadths below the corresponding costal arch at the level of the lateral border of the corresponding rectus muscle, and the Veress needle is inserted through the incision (6). An alternative is incision and trocar placement (5 mm or 12 mm) 1 to 2 cm above the umbilicus (and lateral from the corresponding rectus muscle in obese patients, depending on the position of the renal hilum) (1). The incision should be a few mm larger than the diameter of the trocar. Pneumoperitoneum of at least 10 mmHg is established (6).

In the majority of cases, we entered the abdominal cavity with a 12 mm optical trocar 5 cm lateral from the umbilicus.

## Trocar Positioning

In the standard LLDN, four ports are usually used (Figure 1); an additional fifth port is required for liver retraction. The positioning of the trocars may differ among patients; for obese patients, all the trocars are moved higher (more lateral from rectus muscle) in order to reduce the space to the target organ and to avoid the problems of instruments being too short.


The first and second ports are inserted: one two fingerbreadths below the corresponding costal arch at the level of the lateral border of the corresponding rectus muscle, and the other 1 to 2 cm above the umbilicus (depending on the position of the renal hilum and obesity) (1). The ports are introduced perpendicularly to the abdominal wall. After the first port is placed, an endoscope is inserted and laparoscopy is performed to assess the condition of intra-abdominal space; the anatomical relations are assessed with emphasis on the locations of the other ports (1, 6). The triangulation rule must be followed. There should be four fingerbreadths between the optic and working trocars and five fingerbreadths between the working trocars. Five-millimeter ports are reserved for a more skilled hand because the movements inside smaller ports are precise. The third port for a left-sided nephrectomy is a 5 mm or 12 mm trocar (monopolar round-tipped scissors) and a 12 mm trocar for a right-sided nephrectomy (endoGIA and bipolar grasper). In this case, we should also follow the triangulation rule. The fourth port (5 mm) is inserted midline between the umbilicus trocar and anterior superior iliac spine on the side of the procedure. The fifth port (5 mm) is inserted when

there is a need for liver retraction in a right-sided nephrectomy. It is inserted two fingerbreadths from and lateral to the level of the second port (6).

### Surgical Technique: Transabdominal LLDN

The procedure is started with mobilization of the colon. On the left side, the plane between the descending colon and Gerota's fascia is developed so that the colon falls medially. The lateral attachments of Gerota's fascia to the abdominal wall are left because they hold the kidney and ease identification of the renal hilum. In the next step, the splenorenal and lienocolic ligaments are incised so that the spleen and pancreas are separated from the upper renal pole. For adequate exposure of the renal hilum, dissection of the colon, spleen, and pancreas must be performed. On the right side, the liver is retracted cranially with either a grasper or liver retractor. The ascending colon is mobilized and Gerota's fascia is dissected. The colon is mobilized to the common iliac vessels. In this step, care is taken not to injure the duodenum (1, 6).

**Figure 1.** Trocar positioning for left-sided LLDN (personal archive).





After mobilization of the colon, the gonadal vessels are identified and the fatty tissue under the lower renal pole is lifted so that the psoas muscle is identified. After exposure of the psoas muscle, the ureter is identified, and dissection is continued cranially to expose the renal hilum. In the caudal direction, the ureter is dissected to the crossing of the ureter with the common iliac vessels (1, 6).

In a left-sided nephrectomy, the renal vein is dissected along with the gonadal, adrenal, and lumbar veins. The lumbar vein(s) usually lie posteriorly, and a few mm below this the gonadal vein and adrenal vein usually drain at the superior margin of the renal vessels. It is important to dissect and divide both the lumbar and adrenal veins to increase the length of the renal vein. The left renal artery is usually exposed posterior to the veins.

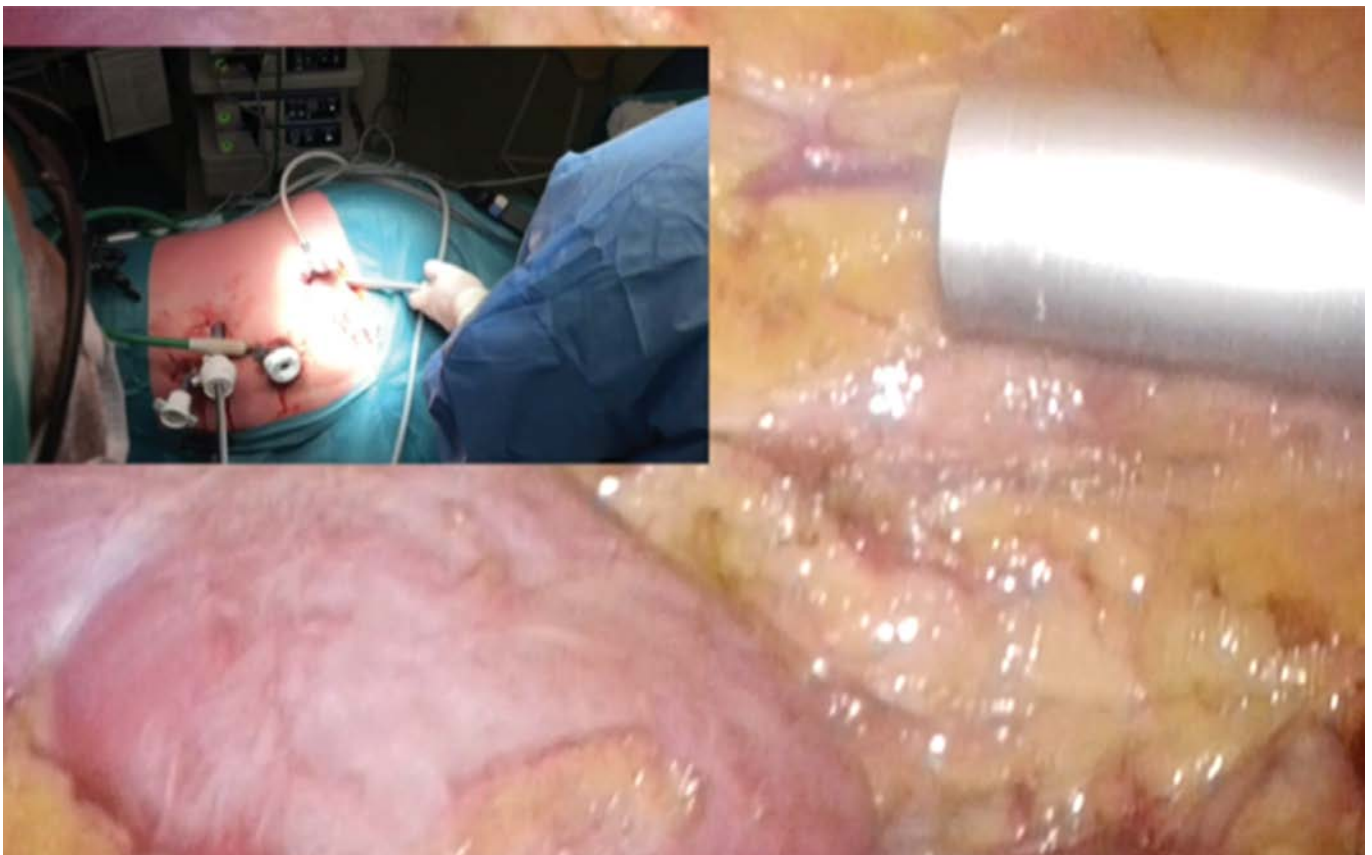
In a right-sided nephrectomy, the duodenum is mobilized by performing a Kocher maneuver and the inferior vena cava is exposed. The renal vein is mobilized up to the inferior vena cava. The renal artery is exposed at its origin, between the aorta and vena cava to maximize the length. In the next step, the kidney is mobilized, starting at the upper

pole, and the adrenal gland is separated. On the right side, the liver should be retracted to expose the upper renal pole and dissect the adrenal gland from the kidney. The posterior and lateral abdominal wall attachments are released by blunt and sharp dissection. Care must be taken to coagulate all the small vessels. In the next step, the ureter is ligated at the most distal point with two large Hem-o-lok clips and then transected. At this point the kidney is mobilized, the only attachments being the renal artery (or arteries) and renal vein.

In the lower ilioinguinal region, a 6 to 8 cm skin and subcutaneous tissue incision is made, and the muscles are bluntly separated so an endobag can be inserted. The kidney, still attached to the renal vessels, is inserted into the endobag. The endobag is partially closed and used as a lever when two Hem-o-lok clips are applied, first to the renal artery then to the renal vein. The vessels are transected, the endobag is closed, the muscles are separated, and the kidney is extracted from the abdominal cavity (Figure 2) (1, 6).

After removing the kidney graft from the abdominal cavity, kidney preparation is started on the side

**Figure 2.** Left lower quadrant incision and insertion of the endobag (personal archive).





bench. The vessels are flushed with normal saline and the kidney is prepared for transplantation (6).

The abdominal wall is closed with a running suture, pneumoperitoneum is reestablished, and hemostasis is checked. An abdominal drain can usually be inserted through one of the 5 mm trocars, pneumoperitoneum is deflated, the trocars are removed, and the incisions are closed with sutures or a stapler (Figure 3) (1, 6).

KTx is usually performed by another surgical team.

## Postoperative Consideration

The nasogastric tube is removed at the end of the procedure. Postoperative analgesia includes NSAID or oral analgesics. Feeding starts on the 1<sup>st</sup> postoperative day. The urinary catheter and drain are removed on the 1<sup>st</sup> postoperative day. Donors are usually discharged on the 2<sup>nd</sup> or 3<sup>rd</sup> postoperative day. They are advised to avoid intensive physical activity for 4 weeks postoperatively. Sutures are removed on the 10<sup>th</sup> postoperative day (6). At our center we follow up donors once per year.

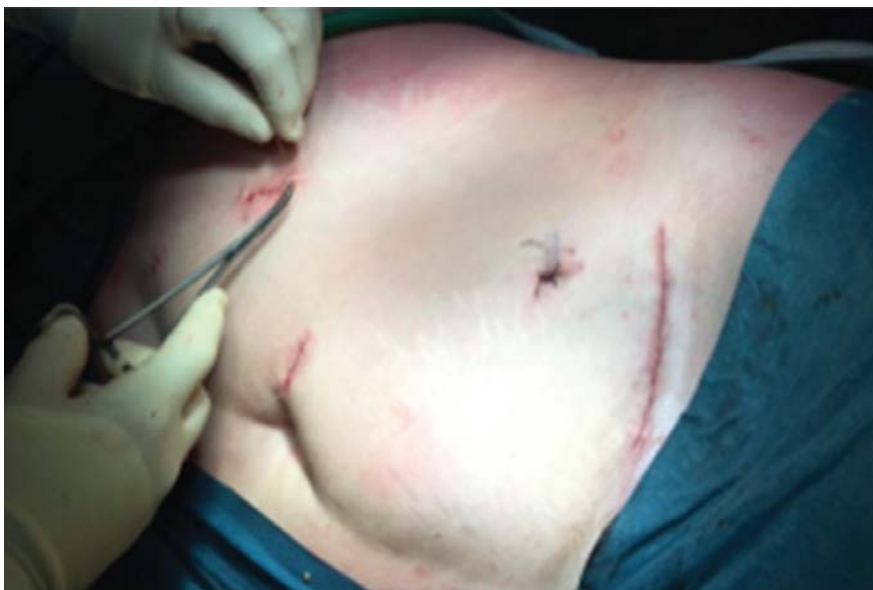## Complications of LLDN

The surgical procedure must be optimized for donors undergoing LLDN because the surgical procedure is not beneficial for the donor, but for the recipient. The surgical team should bear in mind that the surgical procedure is being performed on a

healthy individual that is helping the one with the medical condition for altruistic reasons (7).

According to data from the United States, major complications occur in 1 to 4% of all LLDN, and the death rate connected to the surgical procedure among donors is about 0.03% (7). Because LLDN is a surgical procedure very similar to nephrectomy, the complications are the same, and in the case of LLDN they are even lower. The approach could be either transperitoneal or retroperitoneal. Some authors favor the later because the risk of bowel injury and postoperative adhesions is lower. On the other hand, the transperitoneal approach is superior regarding overview of vessel anatomy, which is crucial (7).

The most serious and life-threatening intraoperative complication is malfunction of the device for securing the artery during LLDN (2). There is no evidence that laparoscopic stapling devices are superior to locking and non-locking clips. Based on a death case after LLDN using locking clips, FDA and manufacturers of locking clips have issued contraindications against their use for securing the artery or arteries during LLDN (2, 10). However, in some European countries locking clips are used for securing arteries during LLDN. Meta-analyses have shown that complications in terms of bleeding from the renal artery are similar when using a stapler and locking clips (11). Other common perioperative complications during LLDN are gastrointestinal (4.4%) injuries, bleeding (3.0%), respiratory injuries (2.5%), and surgical / anesthesia-related injuries (2.4%) (12, 13).



**Figure 3.** Wound closure (personal archive).

The most common postoperative complications are increased blood pressure and proteinuria. The severity of increased blood pressure is comparable to that in the general population in a given country. Proteinuria develops in up to about one-fifth of donors (7).

## LLDN at the Ljubljana University Medical Center: Our Experience

Because the average waiting time for cadaveric KTx in Slovenia is less than 1 year, the demand for living donor nephrectomy is not high. When KTx was introduced as a method of treating patients with ESRD 50 years ago, only open living-donor nephrectomies for KTx were performed, and urologists from our institution were the ones that introduced transplantation activity and organ procurement in Slo-

venia. Twenty years ago, Slovenia became a member of Eurotransplant, which somehow contributed to stagnation of living donor activity (14).

According to data from our national transplantation organization for 2018, our national procurement team procured 79 kidneys. In the same year at our department, we transplanted 56 kidneys (two living-donor and 44 cadaveric: 31 from Eurotransplant and 13 “domestic” ones) (15). On January 4<sup>th</sup>, 2019 there were 137 patients waiting for kidney transplant (two of them in combination with liver transplantation and five of them in combination with pancreas transplantation) (16).

In June 2016, we reintroduced living donor nephrectomy with a minimally invasive laparoscopic approach. Since June 2016, six laparoscopic living donor nephrectomies have been performed. In all cases, a parent donated a kidney to his or her child. In all cases, the left kidney was harvested and transplanted in the right iliac fossa. In five cases we used Hem-o-lok clips for management of the

**Table 1.** Characteristics and outcomes of patients treated in the living donor nephrectomy program at the Ljubljana University Medical Center (2016–2019); M = male, F = female.

Characteristic	Value
Number of procedures	6
Average recipient age (years)	26.6
Average donor age (years)	55
Recipient sex	3 M, 3 F
Donor sex	4 M, 2 F
Left kidney harvested	6
Duration of hospitalization: donor (days)	2
Average duration of procedure (min)	130
Average blood loss (ml)	< 50
Average warm ischemia time (min)	6
Duration of warm ischemia time: range (min)	3.5–7
Transplantation in right iliac fossa	6
Complication: donor (Clavien–Dindo)	none
Complication: recipient (Clavien–Dindo)	
1	4
2	0
3	2
4	0
5	0
6	0

renal vessels, and in one case we used an Endo GIA vascular stapler. Hospitalization of the donor was 2 days. In all cases for donors, the postoperative period was uneventful.

Two major complications occurred in recipients: in one, due to thrombosis of the renal vein and common iliac vein, transplantectomy was needed, and in the other patient postoperative bleeding requiring reoperation occurred (Table 1).

## Conclusion

LLDN is a standard for kidney procurement from a living donor at centers that have experience in laparoscopic kidney surgery. The major advantages are a shorter hospital stay, less analgesic use, faster recovery, faster return to everyday activities, and aesthetic effect. The quality of the kidney graft and its function is not affected. Warm ischemia time is comparable to open surgery. Death due to exsanguination as a consequence of malfunction of devices used for securing the renal artery are rare but fatal. Although the manufacturer and FDA have filed a contraindication on using locking clips for LLDN, they are still used outside the United States, especially at centers that have good experience with using locking clips in renal surgery.

Special consideration is also required in circumstances such as the COVID-19 pandemic. When performing LLDN, one should bear in mind that surgery is performed on a healthy individual that wants to help the patient with ESRD. The surgical technique should be optimized, and the procedure should be performed by an experienced surgeon in order to avoid complications.

## References

- Gritsch HA, Blumberg JM. Renal transplantation. In: Wein AJ et al., editors. *Campbell–Walsh urology*. 11<sup>th</sup> ed. Philadelphia: Elsevier; 2016. p. 1069–89.
- EAU guidelines on renal transplantation 2019 [Internet]. Arnhem: EAU Guidelines Office [cited 2020 Jan 31]. Available from: <https://uroweb.org/guideline/renal-transplantation/>.
- International registry in organ donation and transplantation. Preliminary numbers 2018. [Internet]. Barcelona: IRODaT–DTI Foundation [cited 2020 Jan 31]. Available from: <http://www.irodat.org/img/database/pdf/NEWSLETTER2019-June.pdf>.
- Lennerling A, Lovén C, Dor FJ, Ambagtsheer F, Duerinckx N, et al. Living organ donation practices in Europe—results from an online survey. *Transpl Int*. 2013;26;145.
- Glickman L, Munver R. Laparoscopic living donor nephrectomy. In: Smith JA, et al., editors. *Hinman's atlas of urologic surgery*. 4<sup>th</sup> ed. Philadelphia: Elsevier; 2018. p. 189–97.
- Transperitoneal laparoscopic donor nephrectomy. In: Rosenblatt A et al., editors. *Manual of laparoscopy*. Berlin: Springer Verlag; 2008. p. 165–78.
- Bjurlin MA, Taneja SS. Complications of laparoscopic/robotic nephrectomy and partial nephrectomy. In: Taneja SS, editor. *Taneja's complications of urologic surgery*. 5<sup>th</sup> ed. Edinburg: Elsevier; 2018. p. 349–62.
- COVID-19 recommendations—EAU Guidelines Office Rapid Reaction Group: an organisation-wide collaborative effort to adapt the EAU guidelines recommendations to the COVID era [Internet]. Arnhem: EAU Guidelines Office [cited 2020 Dec 12]. Available from: <https://uroweb.org/wp-content/uploads/Combined-non-oncology-COVID-recommendations.pdf>.
- Raper SE, Clapp JT, Fleisher LA. Let's be reasonable: surgical informed consent in the COVID-19 era. *Ann Surg*. 2020;1(2):e016.
- His RS, Saint-Elie DT, Zimmerman GJ, Baldwin DD. Mechanisms of hemostatic failure during laparoscopic nephrectomy: review of Food and Drug Administration database. *Urology*. 2007;70(5): 888–92.
- Liu Y, Huang Z, Chen Y, Liao B, Luo D, et al. Staplers or clips? A systematic review and meta-analysis of vessel controlling devices for renal pedicle ligation in laparoscopic live donor nephrectomy. *Medicine (Baltimore)*. 2018;97(45):e13116.
- Lentine KL, Lam NN, Axelrod D, Schnitzler MA, Garg AX, et al. Perioperative complications after living kidney donation: a national study. *Am J Transplant*. 2016;16(6):1848–57.
- Hawlina S, Bizjak J. Major complications of laparoscopic and robot assisted urological procedures. In: Komadina R, editor. *Zbornik predavanj XLIX. po-diplomskega tečaja kirurgije za zdravnike, [Portorož]*, 15. in 16. november 2019. Ljubljana: Slovensko zdravniško društvo; 2019. p. 222–31.
- Primc D, Rački S, Arnol M, Marinović M, Fućak-Primc A, et al. The beginnings of kidney transplantation in south-east Europe. *Acta Clin Croat*. 2020;59(1):135–40.
- Statistical data on transplantation activity in year 2018 [Internet]. Ljubljana: Slovenija Transplant [cited 2020 Jan 31]. Available from: [http://www.slovenija-transplant.si/fileadmin/NoviceDokumenti/brosura\\_2019/izpis\\_letno\\_2018.pdf](http://www.slovenija-transplant.si/fileadmin/NoviceDokumenti/brosura_2019/izpis_letno_2018.pdf).
- Statistical data—waiting list for transplant [Internet]. Ljubljana: Slovenija Transplant [cited 2020 Jan 31]. Available from: <http://www.slovenija-transplant.si/index.php?id=statistike&L=2%27A%3D0>.

# Single Anastomosis Duodeno-Ileal Bypass with Sleeve Gastrectomy: A “New” Bariatric Surgery, Presentation of the Surgery, and Our Experiences with the First Cases

**Barbara Rožej, Gregor Kunst, Jure Kovač Myint, Brane Breznikar**

*Department of General and Abdominal Surgery, Slovenj Gradec General Hospital*

## CORRESPONDENCE

**Gregor Kunst, MD**  
gregor.kunst@sb-sg.si

## KEY WORDS

bariatric metabolic surgery, single anastomosis duodeno-ileal bypass with sleeve gastrectomy (SADI-S), surgical techniques, outcomes

## How I Do It

SURGERY SURG ENDOS 2021; 3(1): 53-58

## Abstract

Single-anastomosis duodeno-ileal bypass with sleeve gastrectomy (SADI-S) is a relatively new bariatric procedure in which sleeve gastrectomy is followed by duodeno-ileal anastomosis. This procedure is meant for super-obese patients with a BMI over 50 or failed sleeve gastrectomy with weight regain. It is a modification of biliopancreatic diversion with a duodenal switch (BPD/DS). Preserving the pylorus and creating an enteric bypass with only one anastomosis has several advantages, including reduction of dumping syndrome because of pylorus preservation and because of single-loop reconstruction. Operating time is also shorter and there is no need for closing the mesentery, which reduces the chance of an internal hernia. Reports in the literature on excess weight loss (%EWL), which reaches up to 94% at 1 year, and resolution of comorbidities, especially type 2 diabetes mellitus (74.1%) and hypertension (96.3%), are very promising, although long-term data are lacking. By creating only one anastomosis, the probability of complications is reduced, and the overall complication rate is reported as 4.8%. Last year we started performing SADI-S. We operated on 10 patients, who were preoperatively prepared by a multidisciplinary team. In seven cases, SADI-S was performed as a primary surgery. The mean preoperative BMI was 53.8 kg/m<sup>2</sup>, and the mean weight was 162 kg. Our mean operating time was 100 min, and the mean hospital stay was 4.3 days. In three cases we performed revisional SADI-S after a failed sleeve. The mean preoperative BMI was 48.2 kg/m<sup>2</sup>, and the mean weight was 144 kg. Our mean operating time was 60 min, and the mean hospital stay was 2.3 days. We had no perioperative or early complications, although it is too soon to deny late complications. We adjust the operating technique to our technical knowledge and create hand-sewn duodeno-ileal end-to-side anastomosis. All 10 surgeries were performed laparoscopically and following a “fast track” protocol.



## Introduction

Laparoscopic bariatric surgery has proven to be a safe surgical procedure and the gold standard for the treatment of morbid obesity (1). In the hands of an expert surgeon, the surgeries are followed by very few surgically related complications. According to data published by the International Federation for the Surgery of Obesity and Metabolic Disorders (IFSO) in 2016, the total number of bariatric surgeries performed worldwide was nearly 700,000 procedures per year. The most performed procedure was sleeve gastrectomy (SG; 340,550 or 53.6%), followed by Roux-en-Y gastric bypass (RYGB; 191,326 or 30.1%) and one-anastomosis gastric bypass (OAGB; 30,563 or 4.8%) (2). Because a recent meta-analysis has shown similar long-term outcomes for SG and RYGB, including weight regain and comorbidity relapse, surgeons were prompted to seek modification of currently established surgeries or create new ones (1). Biliopancreatic diversion with duodenal switch (BPD/DS), performed in only 0.5% worldwide according to IFSO data (2), has proven to be the most effective procedure in long-term weight loss and comorbidity resolution, especially type 2 diabetes mellitus and hypertension. However, its technical difficulty and potential adverse events relating to malabsorption of fat-soluble vitamins, micronutrients, and protein as well as steatorrhea (3) have limited its widespread use (1). Thus, Sánchez-Pernate and Torres introduced a modification of BPD/DS called single-anastomosis duodeno-ileal bypass with sleeve gastrectomy (SADI-S) in 2007 (4). This novel technique combines the physiological advantages of pylorus preservation, including a reduction of marginal ulcers by 90% and no dumping syndrome (5), and the technical benefits of single-loop reconstruction (6).

Since 2005 we have performed 2,200 bariatric surgeries altogether, 633 RYGB, 806 OAGB, and 236 SG. Last year we also started performing SADI-S and BPD/DS.

This article presents the SADI-S operation, its technical advantages, and our operating technique and experiences in performing the first cases.

## Methods

In 2020 we operated on 10 patients with SADI-S. Primary operation was performed in seven cases, and in three cases as a secondary operation approximately 1 year after sleeve gastrectomy. We also performed one BPD/DS. All surgeries were performed laparoscopically and following a “fast track” protocol.

Prior to surgery, all patients were treated by a multidisciplinary team. They were recommended to take ADEK multivitamins, calcium citrate 1,800 to 2,400 mg per day, iron 100 mg per day, and protein intake 60 to 80 g per day. The patients signed a consent form detailing the procedure, which included all the benefits and risks associated with it.

### Surgical Technique

The patient is put in the reverse Trendelenburg position, and the surgeon is positioned between the patient's legs. After placing three 12 mm working trocars, one 5 mm working trocar, and a Nathasone liver retractor, and after establishing pneumoperitoneum to a pressure of 15 mmHg with CO<sub>2</sub> gas, we start the surgery with devascularization of the greater curvature of the stomach using a harmonic scalpel. We create a bit thicker sleeve, using a 54 French orogastric tube, which is inserted over the pylorus. We start commencing the sleeve about 2 to 4 cm proximal from the pylorus by using a linear stapler charged with a black, green, and blue cartridge. The preparation begins under the pylorus. In the proximal part of the duodenum, we look for the gastroduodenal artery and follow it to the pars flaccida. After finding the right gastric artery, we usually cut it so we can obtain a more mobile distal stomach for a tension-free anastomosis. Approximately 2 cm distal from the pylorus, the duodenum is divided with a linear blue cartridge. The first part of the operation is finished.

The second part of the operation starts. The patient is put in a horizontal and slightly left position; the surgeon moves to the left side of the patient. The ileocecal valve is identified, and 300 cm of the ileum is carefully measured upwards. A duodeno-ileal termino-lateral manual anastomosis is performed. The anastomosis is created in two layers. The running V-lock suture is used for the first layer of the posterior wall. Then with a monopolar

instrument the bowel and duodenum are opened, and the second layer of the posterior wall is sutured with a running Prolene suture. The same two sutures are used to close the anterior wall of the anastomosis. The anastomosis is tested for watertightness with oral methylene blue installation. The resected stomach is removed through one of the 12 mm incisions. Suction drainage is inserted in all cases.

On the 2<sup>nd</sup> to 4<sup>th</sup> postoperative day, gastrography is routinely performed.

## Results

SADI-S (Figure 1) was performed as a primary surgery in seven cases (five females and two males). In this group the average age was 35 years, the mean preoperative weight was 162 kg, and the mean BMI was 53.8 kg/m<sup>2</sup>. All patients had hypertension, and two had type 2 diabetes mellitus as well. The mean operative time was 100 minutes, and the mean hospital stay was 4.3 days (Table 1).

In three patients (two women and one man) SADI was performed as a secondary operation after “failed” sleeve gastrectomy. In this group, the average age was 53 years, the mean preoperative weight was 144 kg, and the mean BMI was 48.2 kg/m<sup>2</sup>. Prior to primary surgery, all three patients had hypertension, and two also type 2 diabetes mellitus. All comorbidities were improved by the first surgery but not completely resolved. The mean

operative time was 60 minutes, and the mean hospital stay was 2.3 days (Table 1).

We observed no intraoperative or early complications. However, it is too early to discuss late complications.

## Discussion

SADI-S is a “new” bariatric procedure that was introduced in 2007 by Sánchez-Pernaute and Torres (4) and is indicated for super-obese bariatric patients with a BMI above 50 kg/m<sup>2</sup> as a primary surgery. It is a modification of BPD/DS. It was developed to simplify the preexisting surgical technique, to decrease the potential complication rate, and to maintain or to improve the outcomes of the original operation (1).

The first part of the surgery is creating the SG (Figure 1). This is done by using a 40–60 French Bougie orogastric tube, in comparison to the 34 French Bougie usually used in SG. The benefits of preserving the gastric antrum and pylorus were first introduced by Hess et al. (5) as a modification of biliopancreatic diversion to a Roux-en-Y duodenal switch (RYDS) in the late 1980s (4). Preservation of the pylorus in BPD/DS has shown a reduction of marginal ulcers by 90% and decreased the chance of dumping syndrome (5). Other potential benefits of postpyloric vs. prepyloric reconstruction include better absorption of iron, calcium, vitamin B<sub>12</sub>, and proteins (7).

**Table 1.** Our data on SADI-S surgery performed.

	Primary surgery (n = 7)	Revisional surgery after SG (n = 3)
Average age: years	35	53
Mean preoperative weight: kg	162	144
Mean BMI: kg/m <sup>2</sup>	53.8	48.2
Mean operative time: min	100	60
Mean hospital stay: days	4.3	2.3
Comorbidities: patients (%)		
Hypertension	7 (100)	3 (100)
Type 2 diabetes mellitus	2 (29)	2 (67)

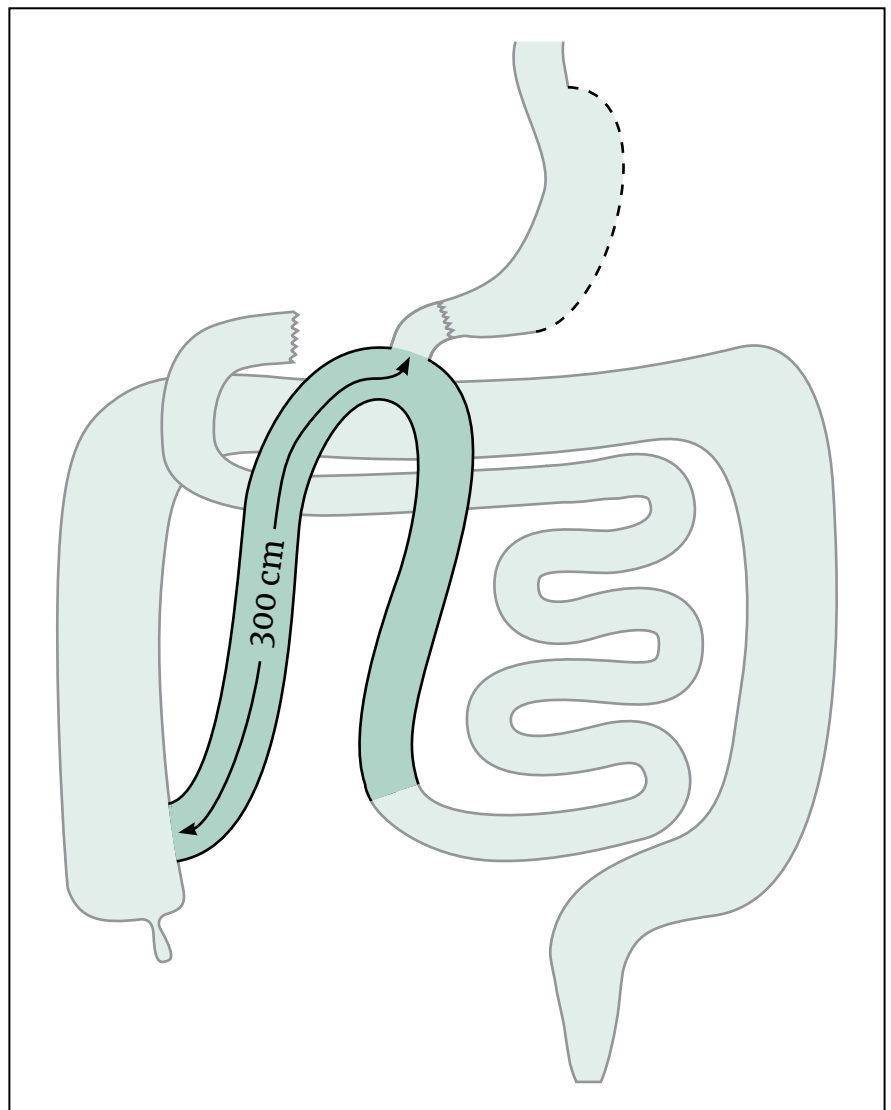
The second step is a single-loop reconstruction, anastomosing the duodenum approximately 2 cm distal from the pylorus directly to an omega loop of ileum 300 cm proximal from the ileocecal valve (Figure 1). With one-loop duodeno-ileostomy we avoid the Roux-en-Y jejunal-ileal, distant anastomosis, which is the standard part of BPD/DS to prevent tension in a distant anastomosis and to protect the gastric mucosa against pancreato-biliary secretion (8). With pylorus preservation there should be no necessity to perform a Roux-en-Y diversion because the pancreatic and biliary juices would have an untouched natural barrier to protect the stomach (4).

There are several advantages of performing only one anastomosis, although the presence of a distal anastomosis is associated with small bowel obstructions secondary to internal hernias. The

reported incidence of internal hernias after RYDS varies from 0.4 to 18% (6). A multicenter study by Surve et al. on 1,328 patients across nine centers that underwent SADI-S showed no incidence of internal hernias or volvulus (9). In addition, elimination of one anastomosis has many more benefits: a reduction in postoperative leak (0.2%) and anastomotic strictures, and a reduction in operating time and consequently fewer anesthetic-derived complications (4).

Sánchez-Pernaute and Torres performed the first anastomosis 200 cm proximal from the ileocecal valve, although they reported short bowel syndrome and malnutrition. Hypoalbuminemia was present in 10%, and hypoproteinemia in 25%. Twenty-two percent had low iron levels and 10% had low hemoglobin (4). The benefits of a longer common limb in reduction of nutrient deficiency

**Figure 1.** Single-anastomosis duodeno-ileal bypass with sleeve gastrectomy.



can be observed in a study by Cottam et al. using a 300 cm loop. The authors reported a significantly lower rate of micronutrient and vitamin deficiency while still achieving an excess weight loss (%EWL) of 86% at 12 months (1). With extending the common limb to 300 cm, Cottam et al. reported normal mean preoperative and postoperative albumin and protein levels at 4 years after surgery (6).

Reports about %EWL are very promising. Sánchez-Pernaute et al. reported 94% EWL at 1 year after surgery (4), although anastomosis was created 200 cm proximal from the ileocecal valve. Cottam et al. reported 77% EWL at 1 year after surgery and 85% EWL 2 to 4 years postoperatively (6).

Saber et al. published a systematic review of the efficacy and safety of SADI-S in which the comorbidity resolution rate was 74.1% for type 2 diabetes mellitus, 96.6% for hypertension, 68.3% for dyslipidemia, 63.3% for obstructive sleep apnea, and 87.5% for gastroesophageal reflux disease (1).

Cottam et al. (6) published a study of 437 patients that underwent a primary SADI-S procedure. The overall early complication rate was 7.7%, and the late complication rate was 10.9%. The most common early complications were nausea (2.2%) and wound infection (2.2%). The mortality rate is reported as 0.2% due to acute renal failure and acute respiratory distress syndrome followed by iatrogenic bowel perforation. The most common late complication was stricture (2.9%), probably as part of the learning curve because this occurred in the early phase (1<sup>st</sup> year) of the start of SADI-S surgery. Seven patients needed common channel lengthening due to severe diarrhea and one due to hypoproteinemia. We had no perioperative or early complications; late complications are still unknown.

To date we have performed SADI-S in 10 patients, in seven cases as a primary procedure (Table 1). First patients were selected, and their characteristics are presented in Table 1. They are comparable to the patients selected by Sánchez-Pernaute and Torres (4), who published a study of their first 50 selected patients, for which the mean preoperative weight was 116 kg, the mean BMI was 44.2 kg/m<sup>2</sup>, 46% had hypertension, and 54% had type 2 diabetes mellitus. Their mean operative time was 90 min for open surgery through median laparotomy and 180 min for laparoscopic surgery, in which duodeno-ileal anastomosis was performed with a linear stapler and the defect was closed with a two-layer running 4/0 polydioxanone suture. Our

mean operative time was 100 minutes; however, we performed all procedures laparoscopically with hand-sewn anastomosis.

Several surgical procedures are currently used as a revisional procedure for weight regain after SG (10) and mainly in patients with a higher BMI before the primary procedure. Therefore, such patients would not sufficiently benefit from a standalone SG and are advised to undergo revisional surgery (10). In the Netherlands, a multicenter cohort study compared SADI-S versus Roux-en-Y after failed SG. Conversion into a SADI-S resulted in significantly more weight loss whereas complications rates and nutritional deficiencies were similar (11). Another study by Doha and Madrid compared SADI-S versus OAGB after failed SG. The short-term weight-loss outcomes and remission of comorbidities were comparable; however, SADI-S is associated with fewer upper gastrointestinal complications and could be a better option for patients suffering from gastroesophageal reflux disease post SG (10).

In three patients, SADI-S was performed as revisional surgery after “failed” primary SG. The patients’ characteristics are presented in Table 1. Prior to the first operation, all of them had hypertension, and two also had type 2 diabetes mellitus. All comorbidities improved after the first operation, but they did not completely resolve. Our mean operating time for this group was 60 minutes.

## Conclusion

SADI-S is safe and technically easy to perform as a primary or revisional bariatric procedure for super-obese patients. It retains the majority of efficacy of BPD/DS, reduces the likelihood of nutritional deficiencies, and is easier to perform than a duodenal switch. It combines restrictive and malabsorptive components. Its short-term weight-loss outcomes and comorbidity resolution rate are very promising. On the other hand, further studies and follow-up are required to assess its effects on malnutrition and quality of life in the long term.



## References

1. Shoar S, Poliakin L, Rubenstein R, Saber AA. Single anastomosis duodeno-ileal switch (SADIS): a systematic review of efficacy and safety. *Obes Surg.* 2018;28(1):104–13.
2. Angrisani L, Santonicola A, Iovino P, Vitiello A, Higa K, et al. IFSO Worldwide Survey 2016: primary, endoluminal, and revisional procedures. *Obes Surg.* 2018;28(12):3783–94.
3. Brown WA, Ooi G, Higa K, Himpens J, Torres A; IFSO-appointed task force for reviewing the literature on SADI-S/OADS. Single anastomosis duodenal-ileal bypass with sleeve gastrectomy / one anastomosis duodenal switch (SADI-S/OADS) IFSO position statement. *Obes Surg.* 2018;28(5):1207–16.
4. Sánchez-Pernaute A, Herrera MAR, Pérez-Aguirre ME, Talavera P, Cabrerizo L, et al. Single anastomosis duodeno-ileal bypass with sleeve gastrectomy (SADI-S). One to three-year follow-up. *Obes Surg.* 2010;20(12):1720–6.
5. Hess DS, Hess DW, Oakley RS. The biliopancreatic diversion with the duodenal switch: results beyond 10 years. *Obes Surg.* 2005;15(3):408–16.
6. Zaveri H, Surve A, Cottam D, Cottam A, Medlin W, et al. Mid-term 4-year outcomes with single anastomosis duodenal-ileal bypass with sleeve gastrectomy surgery at a single US center. *Obes Surg.* 2018;28(10):3062–72.
7. Martini F, Paolino L, Marzano E, D'Agostino J, Lazati A, et al. Single-anastomosis pylorus-preserving bariatric procedures: review of the literature. *Obes Surg.* 2016;26(10):2503–15.
8. Deitel M. César Roux and his contribution. *Obes Surg.* 2007;17(10):1277–8.
9. Surve A, Cottam D, Sánchez-Pernaute A, Torres A, Roller J, et al. The incidence of complications associated with loop duodeno-ileostomy after single-anastomosis duodenal switch procedures among 1328 patients: a multicenter experience. *Surg Obes Relat Dis.* 2018;14(5):594–601.
10. Bashah M, Aleter A, Baazaoui J, El-Menyar A, Torres A, et al. Single anastomosis duodeno-ileostomy (SADI-S) versus one anastomosis gastric bypass (OAGB-MGB) as revisional procedures for patients with weight recidivism after sleeve gastrectomy: a comparative analysis of efficacy and outcomes. *Obes Surg.* 2020;30(12):4715–23.
11. Dijkhorst P, Boerboom AB, Janssen IMC, Swank DJ, Wiezer RMJ, et al. Failed sleeve gastrectomy: single anastomosis duodenoileal bypass or Roux-en-Y gastric bypass? A multicenter cohort study. *Obes Surg.* 2018;28(12):3834–42.

# Minimally Invasive Non-Endoscopic Intracerebral Hematoma Evacuation: An Illustration of the Operative Method

**Tomaž Velnar**

Department of Neurosurgery, Ljubljana University Medical Center

## CORRESPONDENCE

Tomaž Velnar, MD, PhD  
tvelnar@hotmail.com

## KEY WORDS

intracerebral hematoma, hematoma evacuation, brain decompression, minimally invasive surgery

## How I Do It

SURGERY SURG ENDOS 2021; 3(1):  
59-66

## Abstract

Spontaneous intracerebral hemorrhage is frequently encountered in neurological and neurosurgical practice. It is considered one of the most devastating diseases, with a high disability and mortality rate. Intensive medical treatment is the mainstay, which may help improve the prognosis. However, surgery is often needed in order to decompress the brain, reduce cerebral edema, and remove the bleeding. Many surgical approaches have been described so far, from open to minimally invasive techniques. We present a novel minimally invasive non-endoscopic surgical method for the removal of intracerebral hemorrhage.

## Introduction

In clinical practice, spontaneous intracerebral hemorrhage (ICH) is frequently encountered (1). It is regarded as a form of hemorrhagic stroke, sometimes with an extension to the ventricles and the subarachnoid space. In primary hematomas, the bleeding is nontraumatic and spontaneous, and it results from the pathologically altered intraparenchymal vessels. The most frequent bleeding locations comprise the lobar regions, the basal ganglia, the thalamus, the cerebellum, and the brainstem. Despite advances in intensive care treatment and improvements in surgical techniques, morbidity and mortality remain high. About 10 to 15% of these patients remain completely dependent, and the documented mortality reaches up to 40% (2, 3). The incidence is highest in the elderly with accompanying risk factors for cerebrovascular disease, the major ones being uncontrolled and longstanding hypertension or cerebral amyloid angiopathy (4). Other less frequent risk factors for spontaneous ICHs include coagulopathies, vascular malformations, and neoplasms. The ICHs resulting from this pathology are thus regarded as secondary (4, 5).

The symptoms in patients with an acute ICH include focal neurological deficits, which depend on the location of the hemorrhage

and the areas of the brain that are damaged. When bleeding is more extensive, disturbances in consciousness may arise. This is also attributable to the rise in intracranial pressure, as a result of the hematoma mass and the accompanying edema, although the edema becomes more pronounced in the following hours and days. In the next hours after the initial bleeding, the hematoma may grow in size, and this happens in up to 40% of patients. This share is even higher in those with anticoagulant therapy. These patients need special care, observation, an immediate reversal of coagulopathy, and cautious hematoma evacuation, which is often made in a minimally invasive manner in order to limit the chance of intraoperative and postoperative bleeding. For acquiring the diagnosis, an initial clinical assessment is followed by radiological imaging, including CT scan as the first choice, and, in rarer cases, an MRI. A CT-angiography and in some instances a digital subtraction angiography may also help determine the location, extent, and dynamic of bleeding, and it can also act as a tool for treatment (5–7).

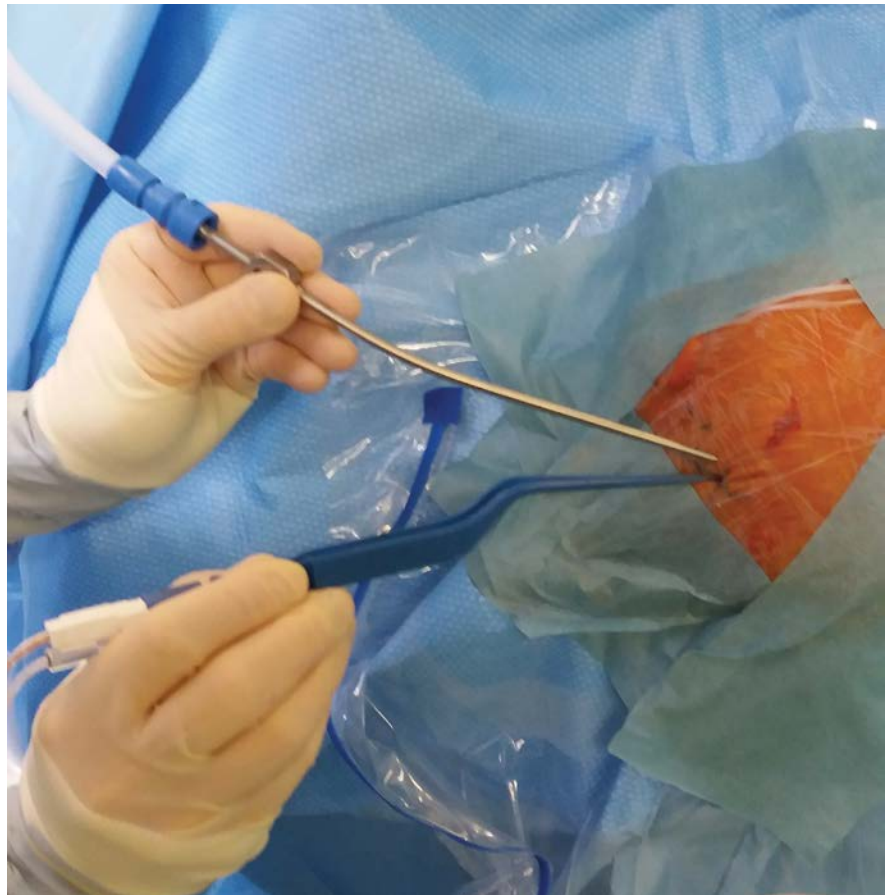
The treatment may include conservative or operative approaches. Conservative treatment requires hospitalization in an intensive care environment with an assessment of the risk factors, close monitoring of the neurological status, optimization of blood pressure, coagulopathy reversal, and measures for reduction of cerebral edema. Patients with hematoma expansion and consciousness deterioration need more advanced supervision, and their management becomes more complex. Intracranial pressure reduction may include the introduction of external ventricular drainage, intracerebral pressure (ICP) monitoring, and mechanical ventilation (7–9). The role of surgery in ICH treatment was a matter of controversy for a long time. Today, the evidence of ICH removal for a better treatment outcome is increasing, especially with advances in neurosurgical techniques, including endoscopy and neuronavigation. In order to improve ICH patients' prognosis and to reduce surgical traumatization, some minimally invasive techniques have been used in hematoma evacuation with minimization of operative injury and maximization of hematoma removal. This is especially important in patients with anticoagulant therapy, in which immediate coagulopathy reversal is essential. In such cases, when surgery is needed, a minimally invasive approach is recommended. These patients may benefit from hematoma evacuation through the minimally invasive proce-

dures mentioned above. Possible surgical options include stereotactic aspiration, endoscopy, and drainage catheter insertion into the hematoma to introduce fibrinolytic drugs for faster hematoma degradation (3, 10–12). A special mode of operation is a non-endoscopic minimally invasive technique, which may be used when an endoscope is not available or in patients at high risk due to concomitant diseases, especially coagulopathies (10, 13). The evacuation of a primary ICH with such a technique is briefly discussed.

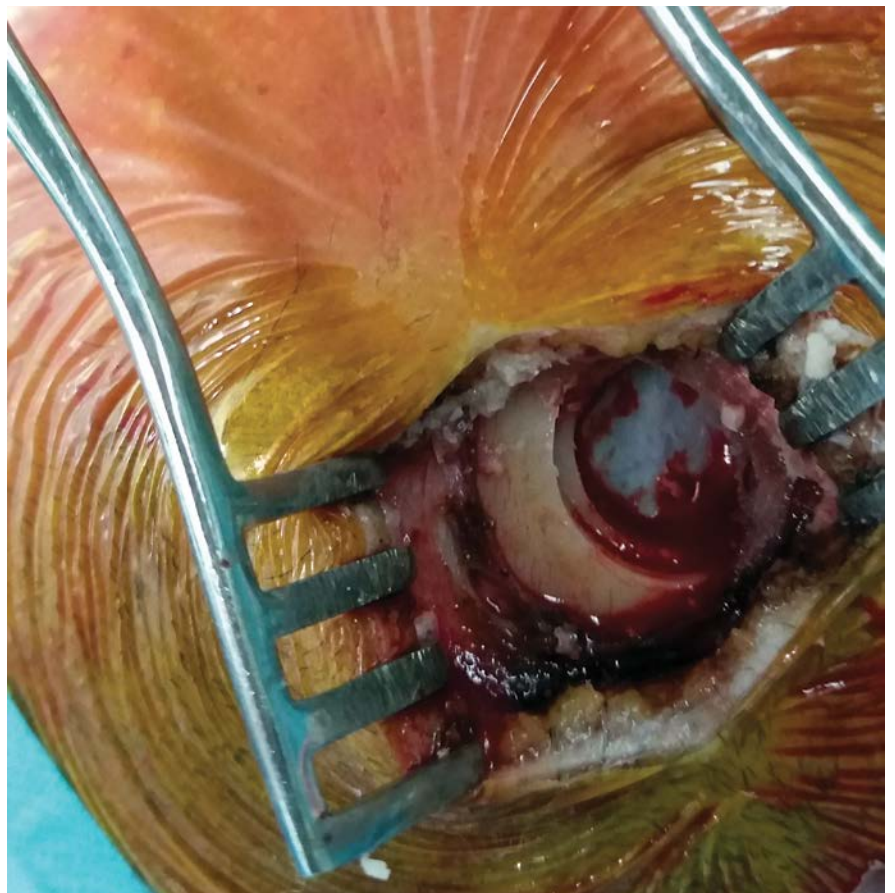
## Operative Technique Description and Outline of Early Results

The patient is placed in the supine position. The head is tilted contralaterally to the lesion (e.g., if the hematoma is on the left, the head is rotated to the right) and the head is fixed in a Mayfield head holder. Neuronavigation can be used to determine the shortest and most optimal surgical trajectory to the hematoma. In emergency settings, the neuronavigational operation can be omitted, especially when the time needed for the surgical preparation may prolong the hematoma removal. After draping and setup, a 1.5 cm skin incision is made just above the hematoma projection, at the shortest distance from the hematoma center (Figure 1). The skull bone is exposed and a burr hole 1 cm in diameter is drilled (Figure 2). The bone chip is harvested and spared. Under a microscope, the brain cortex is coagulated, and an aspirator and bipolar forceps are introduced through the corticotomy into the depth according to the planned trajectory, until reaching the hematoma (Figure 3). The hematoma mass, usually a mixture of blood clots and liquefied blood, is aspirated, and the clots are removed with an aspirator and a bipolar through the approach corridor with gentle aspiration (Figure 4). The hematoma cavity is thereafter rinsed with saline, and any residual bleeding from the brain tissue is coagulated (Figure 5). The hematoma cavum can be lined with an absorbable hemostat (Surgicel, Ethicon). Alternatively, when the bleeding cannot be completely stopped and when small vessels in the hematoma cavity continue to bleed despite the use of bipolar coagulation, Surgiflo (Ethicon) is successfully used at our department. It is introduced into the hematoma cavity,

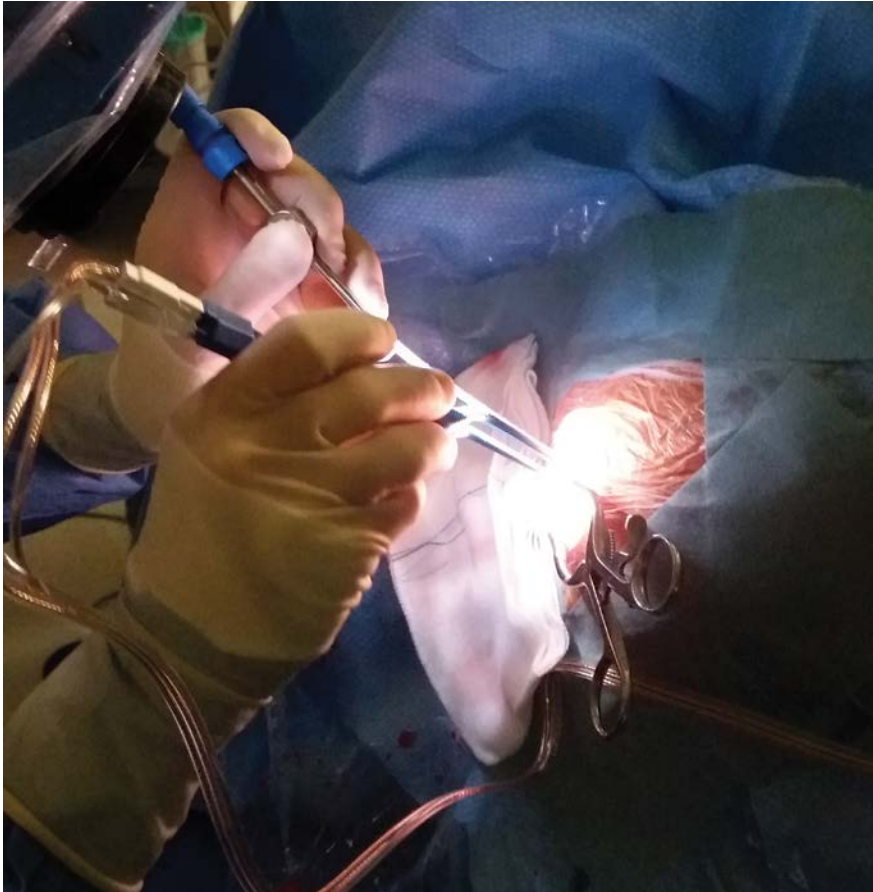
**Figure 1.** The patient is placed supine with the head tilted contralaterally to the lesion. The head is draped and the bipolar is located on the planned skin incision, pointing in the direction of the hematoma.



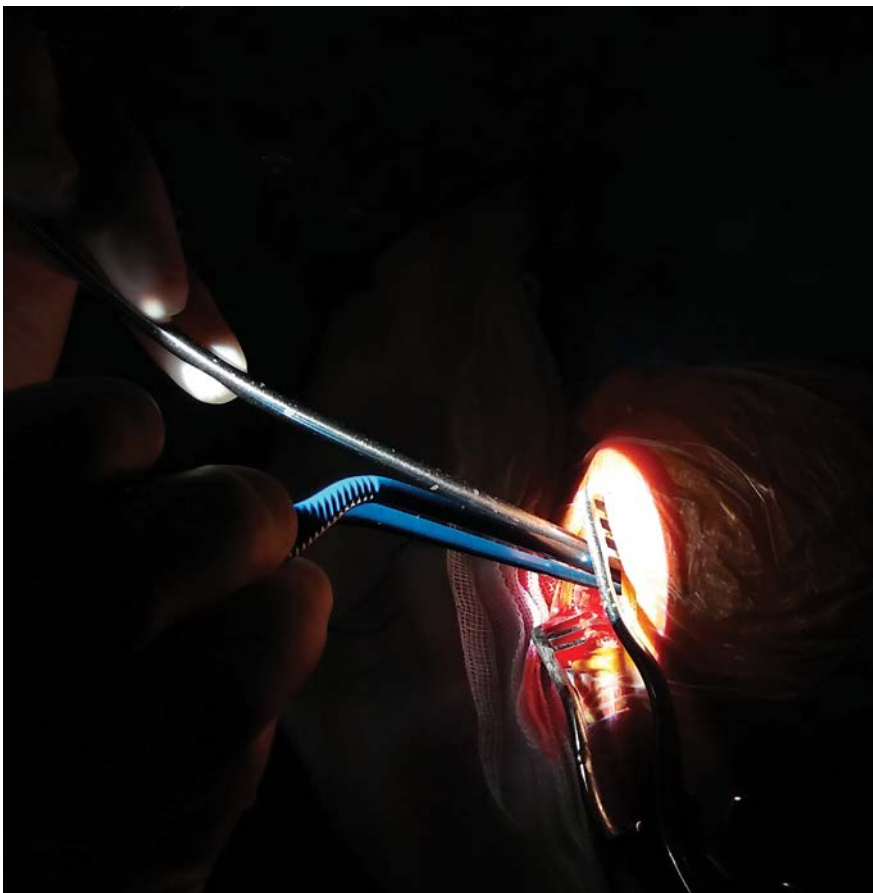
**Figure 2.** The skull bone is exposed and a burr hole 1 cm in diameter is drilled. The dura can be seen and is still not opened.





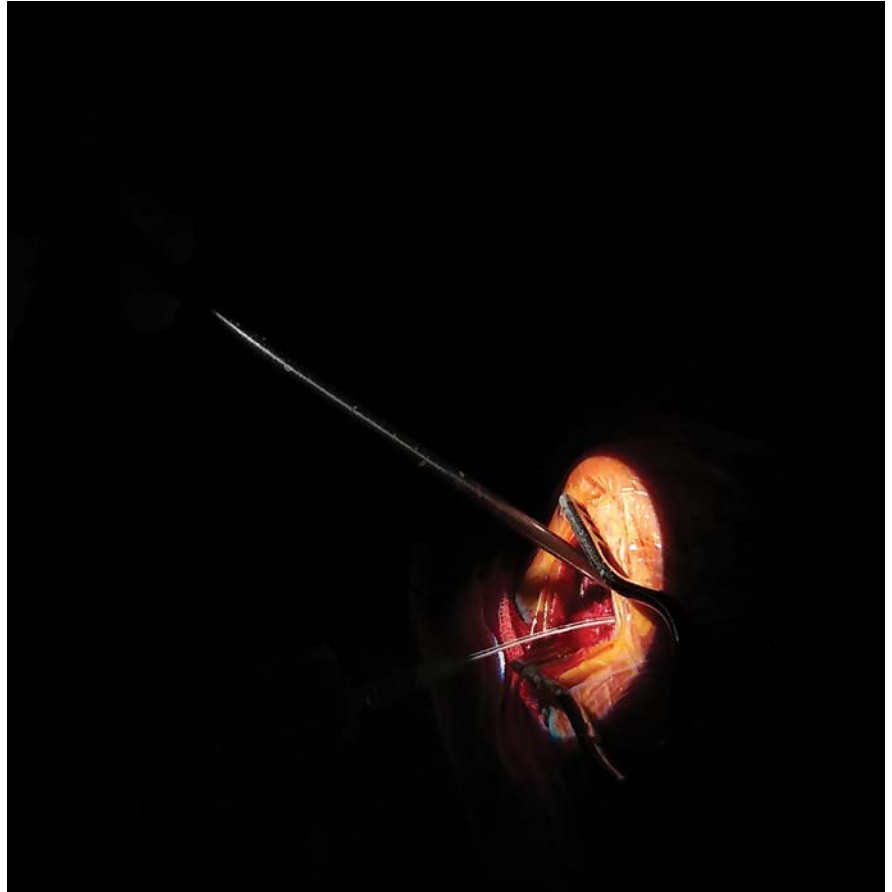

**Figure 3.** Under microscopic vision, the brain cortex is coagulated and penetrated. The aspirator and the bipolar forceps are introduced through this corticotomy into the depth according to the planned trajectory, until reaching the hematoma mass.



**Figure 4.** The hematoma mass is reduced with gentle aspiration through the approach corridor with an aspirator and a bipolar. The operating microscope allows excellent vision and good control over the hematoma cavity.

**Figure 5.** The hematoma cavity is rinsed with saline. The syringe and the aspirator can be seen, introduced in the approach corridor.



left for a minute or two, and then gently aspirated, leaving it only on the hematoma walls, in order to prevent the hemostatic mass from exerting pressure on the brain. Then the dura is closed and usually covered with fibrin glue. The burr hole can be filled with the bone chips that were collected at the beginning of the operation after bone drilling, and the skin is closed in layers.

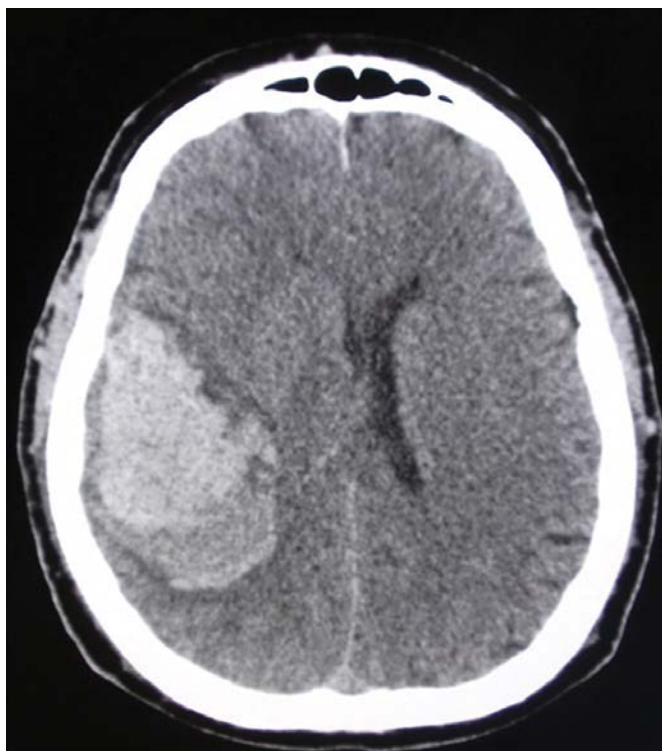
After the operation, the patient is transferred to the intensive care unit and in most cases is kept sedated. If the initial Glasgow coma scale (GCS) rating was 13 or higher, the patient can be awakened immediately after surgery. When kept sedated after surgery, an ICP probe can be inserted to facilitate intensive care treatment. The head CT control imaging is made the next day (Figures 6 and 7). Correction of coagulation and hemostasis is essential before and after the surgery.

This minimally invasive non-endoscopic ICH evacuation was introduced experimentally in clinical practice at our department in 2018, especially for those with anticoagulant treatment. Seven patients were operated on with this approach, and the hematoma removal was successful. The con-

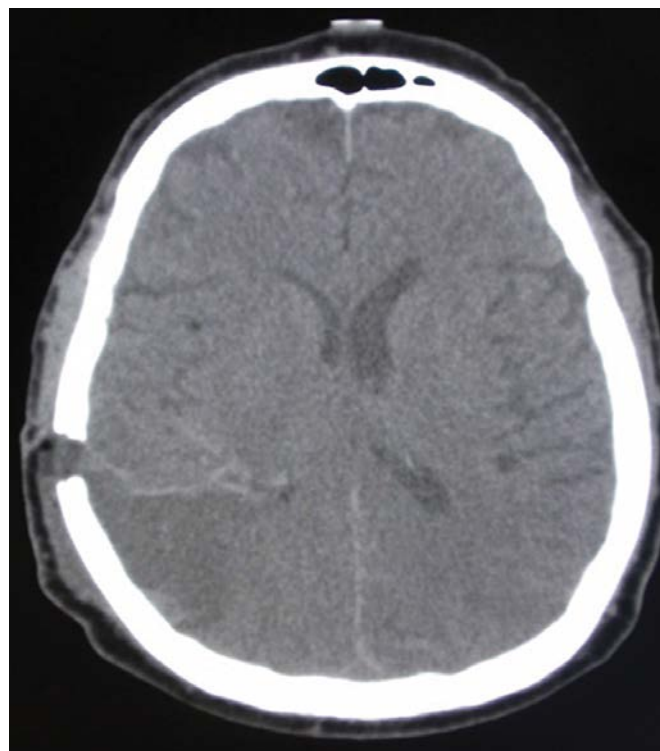
trol CT showed a successfully evacuated hematoma in all patients operated on. Various degrees of neurological disability were observed as a result of bleeding. Of the seven patients, one died within a week after surgery because of fulminant edema. In others, the treatment outcome was favorable. The GCS varied from 9 to 15 after the discontinuation of sedation. At discharge, the outcome was favorable in four patients, and two remained in long-term care. In the case of numerous risk factors and imminent operation, minimally invasive surgery is regarded as an efficient and reasonable treatment option, even though coagulation cannot be normalized.

## Discussion

ICH is a condition with a serious prognosis and is frequently encountered in neurosurgical practice. Numerous factors may influence the prognosis of these patients, such as the condition of the patient, the location and the extent of the hematoma, concomitant diseases, brain edema, and



**Figure 6.** CT before the operation, showing an extensive ICH 5 cm in diameter. The brain shift due to cerebral edema is evident.



**Figure 7.** The control CT after the operation. The ICH has been removed, and no hydrocephalus is present. The burr hole with the approach corridor can be seen.

associated anticoagulation. According to reports, only 48 to 65% of patients survive more than 1 month, and only 10% of these patients can live independently later on. Etiologically, ICHs may be classified as primary or secondary (2, 3). The majority, about 80%, are primary. Here, the main risk factor is a long-lasting and uncontrolled arterial hypertension, causing spontaneous rupture of small vessels. These ICHs are mostly located deep in the brain substance, frequently in the basal ganglia and in the internal capsule. On the other hand, about 20% of the hematomas are secondary (14, 15). Representative locations include the cerebral hemispheres, the pons, and the cerebellum. In comparison to the former, these hematomas are more frequently related to anti-coagulant therapy or coagulation disorders, vascular abnormalities, and tumors (16).

Contemporary treatment approaches include medical, surgical, and combined management with blood pressure reduction and coagulopathy reversal, as well as management of brain edema (11, 17, 18). In the presence of bleeding diathesis of various etiologies, such as trauma, alcoholism, or anticoagulant therapy, the hemorrhage is

accelerated due to disrupted coagulation mechanisms and disturbed aggregation. The blood accumulates rapidly, resulting in cerebral edema and shift of the brain substance with a rise in intracerebral pressure. The natural course of an acute ICH is not static (11, 19). After the initial irreversible brain injury in and near the hemorrhage, a combination of edema, elevated intracerebral pressure, and excitotoxicity lead to additional secondary injury to the brain parenchyma. The perihematomal inflammation that contributes to the mass effect also leads to acute neurological decline and has even been associated with a poor long-term functional outcome (2, 16, 20).

There are many questions and debates regarding when to operate on a patient with an ICH. The discouraging results of conventional hematoma evacuation may be attributed to the type of surgical approach. A standard craniotomy is effective in hematoma evacuation and maintenance of hemostasis. The exposed brain surface is large, which offers a good approach to the hematoma and decent space for instrumental manipulation. However, this approach frequently causes damage to the uninjured brain over the hematoma.



The size of the corticotomy is very important. Care must be taken that the corticotomy be as small as possible, yet effective. Minimally invasive surgical strategies, on the other hand, have been designed to minimize the damage to the cortex (19, 21, 22). They include image-guided and frameless stereotactic procedures. These approaches are frequently combined with employment of thrombolytic agents. Their drawbacks include increased evacuation time and a great deal of preparation before the procedure. In addition, hemostasis is often difficult. The endoscopic-assisted evacuation of ICHs is gaining growing attention as a suitable minimally invasive alternative due to its effectiveness and the ability to evacuate the hematoma immediately and completely with good hemostatic possibilities (13, 19, 23). If an endoscope is not available, a minimal craniotomy or a burr hole is an appropriate choice. The aspiration of blood and hemostasis is possible with the help of the operating microscope, offering good visibility and control over the hematoma through the burr hole and the small corticotomy.

On our opinion, surgery has an advantage over conservative treatment. With brain decompression and removal of the blood clot, the treatment complications are reduced and the recovery times are shorter. When coagulation and aggregation disturbances cannot be reversed completely and rapidly enough, a minimally invasive approach is suggested. However, it must be performed safely. Waiting for hemostasis to be corrected optimally would be at the expense of brain damage. In such cases, the best possible solution is a burr hole and minimally invasive decompression of the brain with ICH removal. With this technique, the wound with potential bleeding is insignificant, the corticotomy is small with minimal injury to the overlying brain, and the operation time is shortened. When an endoscope is not available, the procedure can be performed with an operating microscope, which is a safe option and a good alternative to endoscopic vision. With an operating microscope, it is possible to accompany the steps of evacuation clearly, as well as with the endoscope (13, 23–25). In this operation, the main aim is brain decompression and the removal of blood and its degradation products, which exert a toxic effect on the brain substance. It is not necessary for the decompression be complete. Partial evacuation is also acceptable and can be achieved in most cases. In our experimental group of patients, on average

up to 80% of the hematoma mass was evacuated. In our opinion, a minimally invasive non-endoscopic surgical technique is efficient, especially in patients with coagulopathy and comorbidities, making it a suitable substitution when an endoscope is not available.

## Conclusions

Spontaneous ICHs are a serious and frequent pathology. Prompt action and minimally invasive surgery are important factors offering a satisfactory neurological outcome in patients with ICHs. In the case of patients with imminent operation and numerous risk factors, especially anticoagulant therapy, minimally invasive surgery for ICH is warranted.

## References

1. van Asch CJ, Luitse MJ, Rinkel GJ, van der Tweel I, Algra A, Klijn CJ. Incidence, case fatality, and functional outcome of intracerebral haemorrhage over time, according to age, sex, and ethnic origin: a systematic review and meta-analysis. *Lancet Neurol*. 2010;9(2):167–76.
2. Qureshi AI, Mendelow AD, Hanley DF. Intracerebral haemorrhage. *Lancet*. 2009;373(9675):1632–44.
3. Flaherty ML, Haverbusch M, Sekar P, Kissela B, Kleindorfer D, Moomaw CJ, et al. Long-term mortality after intracerebral hemorrhage. *Neurology*. 2006;66(8):1182–6.
4. Butcher K, Laidlaw J. Current intracerebral haemorrhage management. *J Clin Neurosci*. 2003;10:158–67.
5. Asdaghi N, Manawadu D, Butcher K. Therapeutic management of acute intracerebral haemorrhage. *Expert Opin Pharmacother*. 2007;8:3097–116.
6. Kalita J, Goyal G, Kumar P, Misra UK. Intracerebral hemorrhage in young from a tertiary neurology center in North India. *J Neurol Sci*. 2014;336(1–2):42–7.
7. Velnar T. Non-endoscopic minimally invasive evacuation of intracerebral hematoma (ICH): a case report. *Bosn J Basic Med Sci*. 2018;18(4):375–9.
8. Al-Khaled M, Eggers J. Prognosis of intracerebral hemorrhage after conservative treatment. *J Stroke Cerebrovasc Dis*. 2014;23(2):230–4.
9. Dinger MN, Edwards DF. Admission to a neurologic/neurosurgical intensive care unit is associated with reduced mortality rate after intracerebral hemorrhage. *Crit Care Med*. 2001;29:635–40.



10. Godoy DA, Piñero GR, Koller P, Masotti L, Di Napoli M. Steps to consider in the approach and management of critically ill patient with spontaneous intracerebral hemorrhage. *World J Crit Care Med.* 2015;4(3):213–29.
11. Santalucia P. Intracerebral hemorrhage: medical treatment. *Neurol Sci.* 2008;29(2):271–3.
12. Chan S, Hemphill JC 3rd. Critical care management of intracerebral hemorrhage. *Crit Care Clin.* 2014;30(4):699–717.
13. Zheng J, Li H, Guo R, Lin S, Hu X, Dong W, et al. Minimally invasive surgery treatment for the patients with spontaneous supratentorial intracerebral hemorrhage (MISTICH): protocol of a multi-center randomized controlled trial. *BMC Neurol.* 2014;14:206.
14. Arboix A, Comes E, Garcia-Eroles L, Massons J, Oliveres M, Balcells M, et al. Site of bleeding and early outcome in primary intracerebral hemorrhage. *Acta Neurol Scand.* 2002;105:282–8.
15. Ritter MA, Droste DW, Hegedüs K, Szepesi R, Nabavi DG, Csiba L, et al. Role of cerebral amyloid angiopathy in intracerebral hemorrhage in hypertensive patients. *Neurology.* 2005;64(7):1233–7.
16. Delcourt C, Huang Y, Arima H, Chalmers J, Davis SM, Heeley EL, et al. Hematoma growth and outcomes in intracerebral hemorrhage: the INTERACT1 study. *Neurology.* 2012;79(4):314–9.
17. Andrews CM, Jauch EC, Hemphill JC 3rd, Smith WS, Weingart SD. Emergency neurological life support: intracerebral hemorrhage. *Neurocrit Care.* 2012;17(1):37–46.
18. Steiner T, Bösel J. Options to restrict hematoma expansion after spontaneous intracerebral hemorrhage. *Stroke.* 2010;41(2):402–9.
19. Chen CC, Lin HL, Cho DY. Endoscopic surgery for thalamic hemorrhage: a technical note. *Surg Neurol.* 2007;68(4):438–42.
20. Miller CM, Vespa P, Saver JL, Kidwell CS, Carmichael ST, Alger J, et al. Image-guided endoscopic evacuation of spontaneous intracerebral hemorrhage. *Surg Neurol.* 2008;69(5):441–6.
21. Talukder MM, Islam KM, Hossain M, Jahan MU, Mahmood E, Hossain SS. Surgery for primary intracerebral haemorrhage: is it safe and effective? *Bangladesh Med Res Counc Bull.* 2012;38(3):74–8.
22. Agmazov MK, Bersnev VP, Ivanova NE, Pavlov OA, Nikitin AI, Akhtamov DA, et al. Minimally invasive surgery of patients with hypertensive intracerebral bleedings. *Vestn Khir Im I I Grek.* 2009;168(2):78–82.
23. Yamashiro S, Hitoshi Y, Yoshida A, Kuratsu J. Effectiveness of endoscopic surgery for comatose patients with large supratentorial intracerebral hemorrhages. *Neurol Med Chir (Tokyo).* 2015;55(11):819–23.
24. Delcourt C, Huang Y, Arima H, Chalmers J, Davis SM, Heeley EL, et al. Hematoma growth and outcomes in intracerebral hemorrhage: the INTERACT1 study. *Neurology.* 2012;79(4):314–9.
25. Rennert RC, Signorelli JW, Abraham P, Pannell JS, Khalessi AA. Minimally invasive treatment of intracerebral hemorrhage. *Expert Rev Neurother.* 2015;15(8):919–33.

# Ileocecal Valve Syndrome and Vitamin B<sub>12</sub> Deficiency After Right Hemicolectomy: A Study Protocol

**Jurij Janež**

Department of Abdominal Surgery, Ljubljana University Medical Center

## CORRESPONDENCE

Asst. Prof. **Jurij Janež**, MD, PhD  
jurij.janez@kclj.si

## STUDY PROTOCOL

SURGERY SURG ENDOS 2021; 3(1):  
67-72

## Abstract

**Background:** Right hemicolectomy is a standard operation for right-sided colon cancer and also for some noncancerous lesions. After the surgery, some patients complain about changes in bowel function, bloating, and abdominal discomfort. Because a variable length of terminal ileum is removed during right hemicolectomy, this could have an impact on vitamin B<sub>12</sub> absorption. The aim of this study is to evaluate quality of life and possible vitamin B<sub>12</sub> malabsorption after right hemicolectomy.

**Methods:** The study will be designed as a prospective longitudinal cohort clinical study. Patients 18 or older that are candidates for right hemicolectomy will be included. Serum levels of vitamin B<sub>12</sub> will be evaluated before surgery, and then 3 months and 6 months after surgery. Quality of life will be evaluated with the EORTC QLQ-CR29 questionnaire (European Organisation for Research and Treatment of Cancer Quality of Life Questionnaire) and the GIQLI questionnaire (Gastrointestinal Quality of Life Index) before surgery and after surgery during the follow-up.

**Discussion:** Right hemicolectomy is a standard operation for malignant diseases and also for some benign diseases of the right colon. During the procedure, the ileocecal junction and a variable length of terminal ileum are also removed. This could have an impact on absorption of vitamin B<sub>12</sub>, which is absorbed in the terminal ileum in combination with the intrinsic factor. Many patients complain about changes in bowel habits after surgery, such as abdominal discomfort, diarrhea, bloating, and so on. The aim of this study is to evaluate quality of life and possible changes in vitamin B<sub>12</sub> absorption after right hemicolectomy.

## Introduction

Right hemicolectomy is most often performed due to right-sided colon cancer, but occasionally also due to benign colonic disease. In a standard right hemicolectomy, the right colon with the ileocecal valve and a variable length of terminal ileum (10–20 cm) is resected, both of which play an important role in maintaining normal gastrointestinal function. Ileocolic anastomosis is then performed (1). Vitamin B<sub>12</sub> is a well-known water-soluble vitamin necessary for a number of metabolic reactions and prevention of medical complications, most commonly hematopoietic disorders and spinal cord-related neuropathies (2, 3). Vitamin B<sub>12</sub> bound to protein in foods must undergo an initial or early separation reaction before it can be absorbed in the ileum of the small intestine, whereas most forms found in supplements do not undergo this separation reaction because they are already in the free form. Vitamin B<sub>12</sub> is absorbed in the terminal ileum bound to the intrinsic factor, which is released from the gastric cells. The aim of this study is to evaluate possible changes in vitamin B<sub>12</sub> absorption in patients after right hemicolectomy and to evaluate quality of life in patients after surgery because right hemicolectomy can result in changes in bowel function (4, 5).

## Methods

The study will be designed as a prospective longitudinal cohort clinical study that will be conducted at the Department of Abdominal Surgery, Ljubljana University Medical Center. Patients at least 18 years old, with cancer or inflammatory/ischemic diseases that are candidates for right hemicolectomy, will be included in the study. The aim of the study will be explained to them, and they will have to sign an informed consent to participate in the study. Patients with chronic inflammatory bowel disease, metastatic cancer, palliative surgery, stoma, short gut, or a major surgical complication (Clavien–Dindo classification grade IIIb), will be excluded from the study. Patients that decline to participate will also not be included in the study. The study will be conducted in accordance with GCP and with the Helsinki Ethical Principles for Medical Research. The study has been approved by the Slovenian National Medical Ethics Committee.

Medical record analysis will be performed for patients that will undergo right hemicolectomy. All resected specimens will be sent for histopathological examination, and measurement of macroscopic anatomopathological parameters (length of the resected small intestine and colon) will be performed. Patients will be asked to answer questionnaires (already documented in the literature) about their quality of life.

The EORTC QLQ-CR29 (European Organisation for Research and Treatment of Cancer Quality of Life Questionnaire) will be used for patients that have undergone colon resection because of oncological disease. Patients with gastrointestinal disease not necessarily cancerous will complete the GIQLI questionnaire (Gastrointestinal Quality of Life Index). Patients will be asked to complete the EORTC QLQ-CR29 before the surgery and at the follow-ups 3 and 6 months after surgery. Questions from the GIQLI will be answered before the procedure and at 2 and 6 weeks after the surgery. Serum levels of Vitamin B<sub>12</sub> will be evaluated before the surgery, and then 3 and 6 months after surgery to identify possible deficiency.

## Database compilation

- Patient initials
- Patient number (01, 02, 03, etc.)
- Age
- Sex: male or female
- Pathology: malignant or benign/inflammatory disease
- T: 0, Tis, 1, 2, 3, 4a, 4b
- N: 0, 1, 2
- Stage AJCC: 0, I, IIa, IIb, IIc, IIIa, IIIb, IIIc
- Adjuvant chemotherapy: yes or no
- Technique: open or laparoscopic
- Date of procedure
- Types of surgery: ileocecal resection, right hemicolectomy, wide right hemicolectomy
- Length of ileum resection in cm
- Length of colon resection in cm
- Vitamin B<sub>12</sub> dosage: in pg/ml (range: 145.0–980.0) before surgery, and 3 and 6 months after surgery.

Figure 1. EORTC QLQ-CR29 questionnaire.

<b>EORTC QLQ – CR29</b>				
<ul style="list-style-type: none"> <li>● BEFORE SURGERY</li> <li>● AFTER 3 MONTHS</li> <li>● AFTER 6 MONTHS</li> </ul>				
<b>During the past week:</b>				
	Not at all	A little	Quite a bit	Very much
31. Did you urinate frequently during the day?	1	2	3	4
32. Did you urinate frequently during the night?	1	2	3	4
33. Have you had any unintentional release (leakage) of urine?	1	2	3	4
34. Did you have pain when you urinated?	1	2	3	4
35. Did you have abdominal pain?	1	2	3	4
36. Did you have pain in your buttocks/anal area/rectum?	1	2	3	4
37. Did you have a bloated feeling in your abdomen?	1	2	3	4
38. Have you had blood in your stools?	1	2	3	4
39. Have you had mucus in your stools?	1	2	3	4
40. Did you have a dry mouth?	1	2	3	4
41. Have you lost hair as a result of your treatment?	1	2	3	4
42. Have you had problems with your sense of taste?	1	2	3	4
43. Were you worried about your health in the future?	1	2	3	4
44. Have you worried about your weight?	1	2	3	4
45. Have you felt physically less attractive as a result of your disease or treatment?	1	2	3	4
46. Have you been feeling less feminine/masculine as a result of your disease or treatment?	1	2	3	4
47. Have you been dissatisfied with your body?	1	2	3	4
48. Have you had unintentional release of gas/flatulence from your back passage?	1	2	3	4
49. Have you had leakage of stools from your back passage?	1	2	3	4
50. Have you had sore skin around your anal area?	1	2	3	4
51. Did frequent bowel movements occur during the day?	1	2	3	4
52. Did frequent bowel movements occur during the night?	1	2	3	4
53. Did you feel embarrassed because of your bowel movement?	1	2	3	4
<b>During the past week:</b>				
	Not at all	A little	Quite a bit	Very much
<b>For men only:</b>				
56. To what extent were you interested in sex?	1	2	3	4
57. Did you have difficulty getting or maintaining an erection?	1	2	3	4
<b>For women only:</b>				
58. To what extent were you interested in sex?	1	2	3	4
59. Did you have pain or discomfort during intercourse?	1	2	3	4



Figure 2. GIQLI questionnaire.

GIQLI					
<ul style="list-style-type: none"> <li>● BEFORE SURGERY</li> <li>● AFTER 2 WEEKS</li> <li>● AFTER 6 WEEKS</li> </ul>					
	All of the time	Most of the time	Some of the time	A little of the time	Never
1. How often during the past 2 weeks have you had pain in the abdomen?	4	3	2	2	1
2. How often during the past 2 weeks have you had a feeling of fullness in the upper abdomen?	4	3	2	2	1
3. How often during the past 2 weeks have you had bloating (sensation of too much gas in the abdomen)?	4	3	2	2	1
4. How often during the past 2 weeks have you been troubled by excessive passage of gas through the anus?	4	3	2	2	1
5. How often during the past 2 weeks have you been troubled by strong burping or belching?	4	3	2	2	1
6. How often during the past 2 weeks have you been troubled by gurgling noises from the abdomen?	4	3	2	2	1
7. How often during the past 2 weeks have you been troubled by frequent bowel movements?	4	3	2	2	1
8. How often during the past 2 weeks have you found eating to be a pleasure?	4	3	2	2	1
9. Because of your illness, to what extent have you restricted the kinds of food you eat?	4	3	2	2	1
10. During the past 2 weeks, how well have you been able to cope with everyday stresses?	4	3	2	2	1
11. How often during the past 2 weeks have you been sad about being ill?	4	3	2	2	1
12. How often during the past 2 weeks have you been nervous or anxious about your illness?	4	3	2	2	1
13. How often during the past 2 weeks have you been happy with life in general?	4	3	2	2	1
14. How often during the past 2 weeks have you been frustrated about your illness?	4	3	2	2	1
15. How often during the past 2 weeks have you been tired or fatigued?	4	3	2	2	1
16. How often during the past 2 weeks have you felt unwell?	4	3	2	2	1
17. over the past week, have you woken up in the night?	4	3	2	2	1

18. Since becoming ill, have you been troubled by changes in your appearance?	4	3	2	2	1
19. Because of your illness, how much physical strength have you lost?	4	3	2	2	1
20. Because of your illness, to what extent have you lost your endurance?	4	3	2	2	1
21. Because of your illness, to what extent do you feel unfit?	4	3	2	1	1
22. During the past 2 weeks, how often have you been able to complete your normal daily activities (school, work, household)?	4	3	2	2	1
23. During the past 2 weeks, how often have you been able to take part in your usual patterns of leisure or recreational activities?	4	3	2	2	1
24. During the past 2 weeks, how much have you been troubled by the medical treatment of your illness?	4	3	2	2	1
25. To what extent have your personal relations with people close to you (family or friends) worsened because of your illness?	4	3	2	2	1
26. To what extent has your sexual life been Unpaired (harmed) because of your illness?	4	3	2	2	1
27. How often during the past 2 week, have you been troubled by fluid or food coming up into your mouth (regurgitation)?	4	3	2	2	1
28. How often during the past 2 weeks have you felt uncomfortable because of your slow speed of eating?	4	3	2	2	1
29. How often during the past 2 weeks have you had trouble swallowing your food?	4	3	2	2	1
30. How often during the past 2 weeks have you been troubled by urgent bowel movements?	4	3	2	2	1
31. How often during the past 2 weeks have you been troubled by diarrhoea?	4	3	2	2	1
32. How often during the past 2 weeks have you been troubled by constipation?	4	3	2	2	1
33. How often during the past 2 weeks have you been troubled by nausea?	4	3	2	2	1
34. How often during the past 2 weeks have you been troubled by blood in the stool?	4	3	2	2	1
35. How often during the past 2 weeks have you been troubled by heartburn?	4	3	2	2	1
36. How often during the past 2 weeks have you been troubled by uncontrolled stools?	4	3	2	2	1

- The EORTC QLQ-CR29 incorporates all the items with four possible answers: not at all (1), a little (2), quite a bit (3), very much (4). The patient will be asked to complete this questionnaire before surgery, and then 3 and 6 months after surgery.
- The GIQLI incorporates all the items with five possible answers: all of the time (4), most of the time (3), some of the time (2), a little of the time (1), never (1). The patient will be asked to complete this questionnaire before surgery, and then 2 and 6 weeks after surgery.

## Discussion

The ileocecal valve, also defined as the ileocecal junction, is a sphincter valve that separates the small intestine from the large intestine, regulating the passage of the chyme under influence of hormones and nerve fibers. Removal of the ileocecal valve can lead to displacement of bacteria from the colon into the ileum, and it may result in severe intestinal bacteria overgrowth, characterized by alteration in the number of bacteria in the upper gastrointestinal tract (6). Symptoms are usually nonspecific, such as abdominal discomfort and diarrhea, but this can sometimes lead to malabsorption, malnutrition, and vitamin B<sub>12</sub> deficiency (5). Vitamin B<sub>12</sub> is actively absorbed exclusively in the terminal ileum, but a small amount is passively absorbed throughout the small intestine. Accordingly, ileal resection shorter than 20 cm generally does not put patients at risk of developing vitamin B<sub>12</sub> deficiency (4). Studies have shown that the majority of cases after ileocecal valve removal were reported to be satisfactory (7). However, approximately 20% of patients complain following right-sided colectomy, usually about loose stool, increased bowel frequency, and/or nocturnal defecation. The aim of this study is to evaluate quality of life in patients after right hemicolectomy and to evaluate possible malabsorption of vitamin B<sub>12</sub>.

## References

1. Hope C, Reilly J, Lund J, Andreyev HJN. Systematic review: the effect of right hemicolectomy for cancer on postoperative bowel function. *Support Care Cancer*. 2020;28:4549–59.
2. Jayaprakash A, Creed T, Stewart L, Colton B, Mountford R, Standen G, et al. Should we monitor vitamin B<sub>12</sub> levels in patients who have end-ileostomy for inflammatory bowel disease? *Int J Colorectal Dis*. 2004;19:316–8.
3. Wolffenbittel B, Wouters H, Heiner-Fokkema MR, Van der Klauw MM. The many faces of cobalamin (vitamin B<sub>12</sub>) deficiency. *Mayo Clin Proc Inn Qual Out*. 2019;3(2):200–14.
4. Duerksen DR, Fallows G, Bernstein CN. Vitamin B<sub>12</sub> malabsorption in patients with limited ileal resection. *Nutrition*. 2006;22:1210–3.
5. Williams A, Carter J, Basu P, Hughes L, Nair D, Williams EM, et al. Vitamin B<sub>12</sub> status after right hemicolectomy in bowel cancer patients: a feasibility study. *Colorec Cancer*. 2017;3:2.
6. Germani P, Zucca A, Giudici F, Terranova S, Troian M, Samardzic N, et al. Ileocecal valve syndrome and vitamin B<sub>12</sub> deficiency after surgery: a multicentric prospective study. *Updates Surg*. 2020; doi: 10.1007/s13304-020-00845-z. [Online ahead of print].
7. Palmisano S, Silvestri M, Troian M, Germani P, Giudici F, de Manzini N. Ileocecal valve syndrome after surgery in adult patients: myth or reality? *Colorectal Dis*. 2017;19(8):e288–95.

# The ENSEAL™ X1 Tissue Sealers offer more than LigaSure™



**More secure<sup>1\*</sup>**

**More efficient<sup>2,3\*\*</sup>**

The ENSEAL™ X1 Tissue Sealers are advanced bipolar devices designed for use in open or laparoscopic surgical procedures.<sup>#</sup> We have and will further redesign our Ethicon Energy Advanced Bipolar Portfolio, to provide secure sealing with more intuitive and simplified steps-for-use.<sup>4,5</sup>

\*Preclinical test of distal tip bleeding (ENSEAL® vs. Impact-LF4318) in thick porcine mesentery base (p=0.001). \*\*ENSEAL X1 Curved Jaw Tissue Sealer can capture, seal and transect a longer length of tissue per single activation due to a 16% (or 3.4mm) longer jaw (p < 0.001) and a 19% (or 3.5mm) longer cut length (p < 0.001) compared to LigaSure™ Maryland (LF1937).ures #ENSEAL™ X1 Large Jaw is intended for use in open surgical procedures

REFERENCES: 1. Ethicon, PSP005173A, Final Report- 2017 Brick Claims: Comparison of Distal Tip Sealing Performance Between ENSEAL™ X1 Large Jaw (NSLX120L) with Algorithm and Ligasure™ Impact (LF4318), Sept. 2016, Data on File (154862-201002) 2. Ethicon, Project Floyd: Claims Metrology Report, June 2018, PRC079564B (145163-200630) 3. Ethicon, Floyd Relaunch Claims Metrology, June 2020, PRC095763A (145163-200630) 4. Ethicon, DOC023555A, A Floyd Claims Memo Industrial Design, July 2018, Data on File (155321-201009) 5. Ethicon, PRC095915A, Curved Design Validation 2 Completion Report, June 2020, Data on File (155321-201009)



# Instructions for Authors

Surgery and Surgical Endoscopy is the official journal of the Slovenian Society of Endoscopic Surgery. It is a multidisciplinary journal devoted to publishing original and high-quality scientific papers, pertinent to surgery, surgical oncology as well as surgical endoscopy.

The Editorial Board requires that the paper has not been published or submitted for publication elsewhere. The authors are responsible for all statements in their papers. Accepted articles become the property of the journal and, therefore, should not be published elsewhere without the written permission of the editors.

## 1. SUBMISSION OF THE MANUSCRIPT

The journal accepts *review articles, research articles, case reports, letters to the editors, study protocols* and "How I do it" submissions.

*The manuscript written in English should be submitted to Editors-in-Chief, Tomaž Jagrič or Jan Grosek (tomaz.jagric@gmail.com; jangrosek@gmail.com).*

All articles are subjected to the editorial review. The editorial board reserves the right to ask authors to make appropriate changes of the contents as well as grammatical and stylistic corrections when necessary.

Articles are published printed and on-line as the open access ([www.zeks.si/journal](http://www.zeks.si/journal)). There is no publication fee.

When manuscripts are submitted under multiple authorship, it is the corresponding author who has the authority to act on behalf of all the authors in all matters pertaining to publication. Submitted manuscripts are reviewed by the editorial board on the assumption that all listed authors concur in the submission and are responsible for its content.

## 2. PREPARATION OF MANUSCRIPTS

The manuscript should be submitted as .doc or .docx file. It should be written in grammatically and stylistically correct language. Abbreviations should be avoided. If their use is necessary, they should be explained when first mentioned in the text. The chapter headings should not contain abbreviations. The technical data should conform to the SI system. Each section should be started on a new page, and each page should be numbered consecutively with Arabic numerals.

The Title page should include a concise and informative title, followed by the full name(s) of the author(s); the institutional affiliation of each author; the name and address of the corresponding author (including telephone, fax and E-mail). Authors should be qualified for authorship. They should contribute to the conception, design, analysis and interpretation of data, and they should approve the final version of the contribution.

This should be followed by the abstract page, summarizing in less than 250 words the reasons for the study, experimental approach, the major findings (with specific data if possible), and the principal conclusions. Three to six key words should

be provided for indexing purposes. Structured abstracts are required for research articles only.

### Review Articles

The Editorial Board encourages submission of review articles on topics of current interest. The manuscript should be restricted to 5000 words and up to 50 references. An abstract of no more than 250 words and up to six key words should be provided.

### Research Articles

The abstract of the research article should be structured (Background, Methods, Results, Conclusions) and of no more than 250 words (Slovenian language abstracts are limited to 400 words).

Research article should be structured as well, divided into sections: Introduction, Methods, Results and Discussion. Manuscript should be restricted to 4000 words.

Introduction should summarize the rationale for the study or observation, citing only the essential references and stating the aim of the study.

Materials and methods should provide enough information to enable experiments to be repeated. New methods should be described in detail.

Results should be presented clearly and concisely without repeating the data in the figures and tables. Emphasis should be on clear and precise presentation of results and their significance in relation to the aim of the investigation.

Discussion should explain the results rather than simply repeating them as well as interpret their significance and draw conclusions. It should discuss the results of the study in the light of previously published work.

### Case Reports

This section presents reports on rare or otherwise interesting case report or case series. Articles must be authentic, ethical, educational and clinically interesting to an international audience of surgeons, trainees and researchers in all surgical subspecialties, as well as clinicians in related fields.

The manuscript should be in the format:

- Introduction
- Case report/case presentation
- Discussion

Submissions to this section should carry no more than 2500 words, two figures and 20 references. An unstructured abstract of up to 200 words and six key words should be provided.

### Letters to the Editor

Comment on papers recently published in the Journal. The letters should be restricted to up to 500 words and three references and should not carry any figures.

## Study Protocol

Study protocol articles can be for proposed or ongoing prospective clinical research, and should provide a detailed account of the hypothesis, rationale and methodology of the study. Study protocols for pilot or feasibility studies will be treated on a case by case basis. Study protocols without ethics approval will generally not be considered. The manuscript should be structured the same way as a research article.

### How I Do It?

Submissions to this section should provide description of a well-established procedure focussing on its technical aspects. The manuscript should be in the format:

- Introduction
- Preoperative preparation
- Operative steps
- Postoperative care

The operative steps should be illustrated with high-quality figures. The manuscript should be restricted to 1500 words, a 150-word abstract, six key words and may carry up to 10 figures and 10 references.

## 3. DECLARATIONS

All manuscripts must contain the following sections under the heading "Declarations".

- Ethics approval and consent to participate
- Consent for publication
- Competing interests
- Authors contributions
- Funding
- Acknowledgements

If any of the sections are not relevant to your manuscript, please include the heading and write "Not applicable" for that section.

### a) Ethics approval and consent to participate

Manuscripts reporting studies involving human participants, human data or human tissue must:

- include a statement on ethics approval and consent (even where the need for approval was waived), and
- include the name of the ethics committee that approved the study and the committee's reference number if appropriate.

Studies involving animals must include a statement on ethics approval. If your manuscript does not report on or involve the use of any animal or human data or tissue, please state "Not applicable" in this section.

### b) Consent for publication

If your manuscript contains any individual person's data in any form (including any individual details, images or videos), consent for publication must be obtained from that person, or in the case of children, their parent or legal guardian. All presentations of case reports must have consent for publication. You should not send the form to us on submission, but we may request to see a copy at any stage (including after publication). If your manuscript does not contain data from any individual person, please state "Not applicable" in this section.

## 4. REFERENCES

References must be numbered in the order in which they appear in the text and their corresponding numbers quoted in the text. Authors are responsible for the accuracy of their references. References to the Abstracts and Letters to the Editor must be identified as such. Citation of papers in preparation or submitted for publication, unpublished observations, and personal communications should not be included in the reference list. If essential, such material may be incorporated in the appropriate place in the text. References follow the style of Index Medicus, DOI number (if exists) should be included. All authors should be listed when their number does not exceed six; when there are seven or more authors, the first six listed are followed by "et al.". The following are some examples of references from articles, books and book chapters:

1. Dent RAG, Cole P. In vitro maturation of monocytes in squamous carcinoma of the lung. *Br J Cancer* 1981; 43: 486–95. doi:10.1038/bjc.1981.71
2. Chapman S, Nakielny R. A guide to radiological procedures. London: Bailliere Tindall; 1986.
3. Evans R, Alexander P. Mechanisms of extracellular killing of nucleated mammalian cells by macrophages. In: Nelson DS, editor. *Immunobiology of macrophage*. New York: Academic Press; 1976. p. 45–74.

## 5. CHARTS, ILLUSTRATIONS, IMAGES AND TABLES

Charts, Illustrations, Images and Tables must be numbered and referred to in the text, with the appropriate location indicated. Each of them should contain a title and an explanation of all the abbreviations and non-standard units used. Charts, Illustrations and Images, provided electronically, should be of appropriate quality for good reproduction and should be submitted as separate files. Illustrations and charts must be vector image, created in CMYK colour space, preferred font "Century Gothic", and saved as .AI, .EPS or .PDF format. Colour charts, illustrations and Images are encouraged, and are published without additional charge. Image size must be 2.000 pixels on the longer side and saved as .JPG (maximum quality) format. In Images, the identities of the patients should be masked. Tables should be typed double-spaced. The files with the figures and tables can be uploaded as separate files.

## 6. PAGE PROOFS

Page proofs will be sent by E-mail to the corresponding author. It is their responsibility to check the proofs carefully and return a list of essential corrections to the editorial office within three days of receipt. Only grammatical corrections are acceptable at that time.

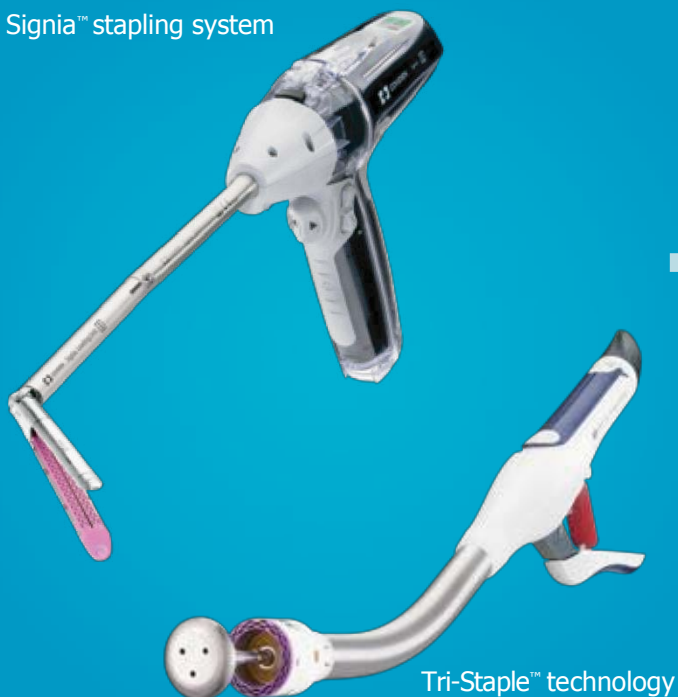## 7. OPEN ACCESS

Papers are published electronically as open access on [www.zeks.si/journal](http://www.zeks.si/journal).

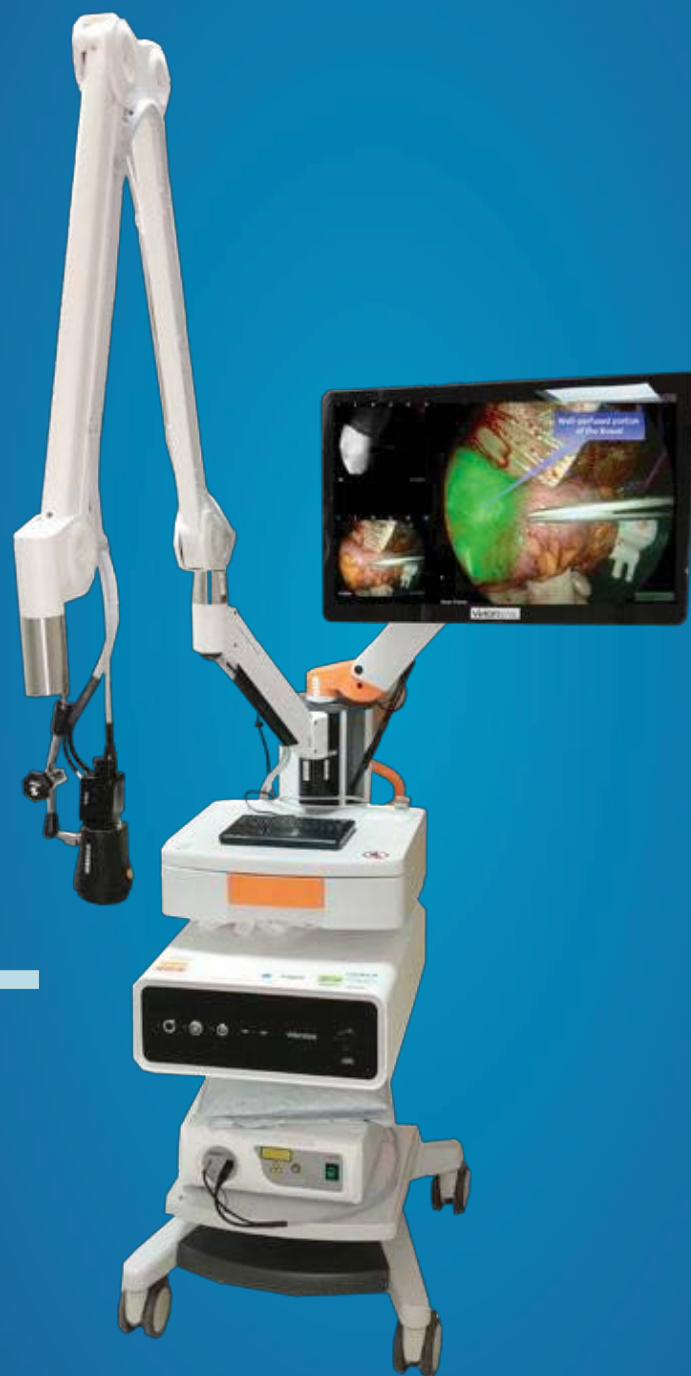# EVIDENCE-BASED TECHNOLOGY. DATA-BASED DECISIONS.

Our vision is to reduce the risks  
of leaks in colorectal surgery

Signia™ stapling system



Tri-Staple™ technology



Visionsense™ VS3 iridium system



## MM SURGICAL

MM Surgical d.o.o., Ulica ob hrastih 24, 1291 Škofljica, SLOVENIJA  
Tel.: +386 (0)1 236 21 56, 236 21 57, Fax: +386 (0)1 436 00 39

E-mail: [mm.surgical@siol.net](mailto:mm.surgical@siol.net)  
[www.mmsurgical.si](http://www.mmsurgical.si)

**Medtronic**  
Further. Together





