

SURGERY **and** **SURGICAL** **ENDOSCOPY**

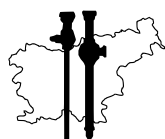
Vol. 2, No. 2, Oct. 2020

Official Journal of the Slovenian Society for Endoscopic Surgery



Surgery and Surgical Endoscopy

Official Journal of the Slovenian Society for Endoscopic Surgery



Slovenian Society
for Endoscopic Surgery

Surgery and Surgical Endoscopy is a fully open access, peer-reviewed journal that aspires to publish articles relevant to surgery, surgical oncology as well as surgical endoscopy from researchers worldwide. The journal accepts review articles, research articles, case reports, letters to the editors, study protocols and "How I do it" submissions.

Editors-in-Chief

Tomaž Jagrič, Jan Grosek

Editorial Board

Matej Cimerman, Vojko Flis, Štefan Grosek, Tine Hajdinjak, Simon Hawlina, Bojan Krebs, Gregor Norčič, Peter Popovič, Stojan Potrč, Tomaž Smrkolj, Tomaž Štupnik, Aleš Tomažič, Blaž Trotovšek

Technical Editor

Hana Zavrtanik

Publisher

Slovenian Society for Endoscopic Surgery

Address of the Editorial Office and Administration

Zaloška cesta 7, 1000 Ljubljana, E-mail: info@zeks.si

Reader for English

DEKS, d.o.o.

Layout

Jan Grosek

Graphic Design

GALdesign

Printed by

Tiskarna Januš, Ljubljana

Issue Frequency

2 issues/year

Circulation

100

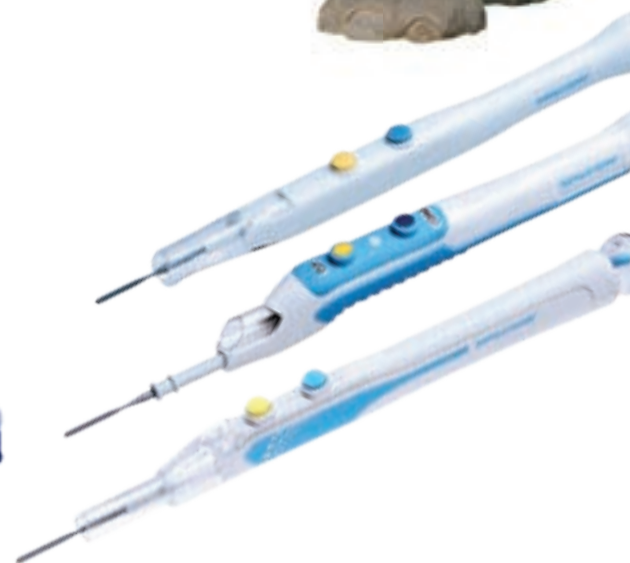Indexed and/or Abstracted

Digitalna knjižnica Slovenije (dLib)



Stop ignoring the elephant in the room

There are dangers in Surgical Smoke Plume
Together, we can help eliminate them



Surgical Smoke Evacuation Solutions **Clearing the Air for a Healthy OR**

➤ The **LEADER** in Surgical Smoke Management

Endosurgical | Šmartinska cesta 152, 1000 Ljubljana
dsemrov@endosurgical.si | +386 41 799 123

Contents

LETTER TO THE EDITOR

- 7 **Mesh Fixation in Laparoscopic Transabdominal Preperitoneal (TAPP) Inguinal Hernia Repair**
Jurij Gorjanc

RESEARCH ARTICLES

- 11 **Adhesive Techniques for Mesh and Peritoneum Fixation in Laparoscopic Inguinal Hernia Repair**
Radenko Koprivica, Sanjanin Perišić, Manuela Kuhar Makoter
- 17 **Standardization and Safety in Bariatric Surgery: Preventing Liver Failure**
Tadeja Pintar

CASE REPORTS

- 23 **Surgical Management of Spontaneous Intracerebral Hematomas: An Overview and Our Results**
Lina Iskra Vugdelija, Roman Bošnjak, Tomaž Velnar
- 31 **Microsurgical Replantation of Traumatic Total Scalp Avulsion: The First Reported Case in Slovenia**
Luka Emeršič, Matevž Hlačer

- 39 **Single-Port Laparoscopic Resection of Intraductal Papillary Neoplasm of the Bile Duct with an Associated Invasive Carcinoma: A Case Report and Literature Review**
Gašper Horvat, Rada Đokić, Mihajlo Đokić

- 45 **Liver Magnetic Resonance Imaging and the Histological and Clinical Picture of a Neonatal Near-Miss Case of a Term Newborn with Gestational Alloimmune Liver Disease Treated with Extracorporeal Membrane Oxygenation, Plasmapheresis, and Liver Transplantation**
Primož Herga, Gorazd Mlakar, Darja Urlep Žužej, Jernej Breclj, Petja Fister, Rafael Ponikvar, Branislava Ranković, Domen Plut, Ezio Bonanomi, Lorenzo D'Antiga, Štefan Grosek

- 55 **Laparoscopically Assisted Foreign Body Removal from the Cecum: A Case Report**
Aleksander Göntér, Primož Sever

HOW I DO IT

- 61 **Right Colectomy with the Da Vinci Xi Robotic Platform**
Jan Grosek

Editorial

Aleš Tomažič

President of the Slovenian Society for Endoscopic Surgery

CORRESPONDENCE

Prof. **Aleš Tomažič**, MD, PhD
ales.tomazic@kclj.si

Dear Colleagues,

I am pleased to present the fourth issue of *Surgery and Surgical Endoscopy*. With great personal effort, the editors have inspired a good number of colleagues to publish their articles in our journal. The number of quality articles submitted is so large that we have no concerns about preparing the issues for the coming year. One might think that the circumstances with the coronavirus spreading also contributed to this. During these times we are tending to remain at home, there are no conferences in our own countries or abroad, and consequently we have more time to dedicate to writing articles.

In theory, matters are as described—but reality is far from that. At the Ljubljana University Medical Center's Department of Abdominal Surgery, during the epidemic we realized more than 90% of our operative program, we organized and conducted lectures remotely, and we also conducted additional programs to shorten waiting times, among other efforts. The situation was presumably similar at other Slovenian hospitals. It is clear that these contributions are not the result of Slovenian surgeons having extra time on their hands, but the result of individuals' inner drive and enthusiasm. This is nothing new: this is how surgical research and surgical articles have been created for many years—and that is also why this journal is so valuable.

Laparoscopic hernioplasty for inguinal hernia has become established in many hospitals in Slovenia in the last 10 years. In this issue of the journal you will find a contribution by Radenko Koprivica on laparoscopic inguinal hernioplasty plus an excellent comment on this topic by Jurij Gorjanc. Obesity is a disease of modern times, and the journal has published an article by Tadeja Pintar on the importance of standardization

in bariatric surgery and the related prevention of liver failure in these patients. A review of the treatment of spontaneous intracerebral hematomas and a presentation of his own results was contributed to the journal by the neurosurgeon Tomaž Velnar. In addition to these articles, you will find three interesting case reports in the journal: microsurgical replantation of a complete traumatic scalp avulsion, single-port laparoscopic resection of an intraductal papillary mucinous neoplasm of the bile duct, and treatment of a newborn with gestational alloimmune liver disease.

Robotic surgery is gaining ground around the world, and Slovenia is no exception. At the Ljubljana University Medical Center, after initial steps in the field of urology, abdominal surgeons are gaining experience with robotic surgery this year. Jan Grosek describes in detail the special features of robotic right hemicolectomies with the da Vinci Xi robotic system.

In conclusion, I encourage you to write and send professional contributions of all kinds: original research articles, meta-analyses, case studies, and more. We will do our best to publish high-quality contributions as promptly as possible. Stay healthy during the uncertain period ahead!

Prof. Aleš Tomažič



Letter to the Editor: Mesh Fixation in Laparoscopic Transabdominal Preperitoneal (TAPP) Inguinal Hernia Repair

Jurij Gorjanc

President of the Slovenian Hernia Society

CORRESPONDENCE

Jurij Gorjanc

jurij.gorjanc@mf.uni-lj.si

LETTER TO THE EDITOR

SURGERY SURG ENDOS 2020; 2(2):
7-9

Dear Editor,

It was interesting to read the article about mesh fixation in transabdominal preperitoneal (TAPP) inguinal hernia repair (the comparison of a stapling device and glue in this issue). The fact is that there are still departments or individuals today that fixate mesh in TAPP with staple devices or even close the peritoneum with tackers. Indeed, the stapling technique in TAPP was long (1990–2005) a gold standard, and after 2005 good studies emerged that persuaded us to the contrary. So, should we really just forget the staples? Are they so wrong? And, last but not least, what about very large hernia defects? Should we not tack at least in these cases to prevent mesh migration (repositioning)?

This topic was actually cleared in the International Endohernia Society (IEHS) guidelines in 2011, and it is summarized in the text and tables below:

Recurrence

There are no more recurrence cases after non-fixation in comparison to fixation. In L1, M1, L2, and M2 hernias, we may consider non-fixation (1).

In the case of fixation, the recurrence rate in the stapling device group compared to the glue group is even higher (0.6% vs. 0.4%). The results are summarized in Table 1.

Acute Pain

There are advantages in favor of glue fixation concerning post-operative pain (Table 2).

Table 1. Recurrences after fixation with staples versus fixation with fibrin glue (2).

Study	Follow-up	Type of repair	Recurrence		Level of evidence
			Stapling device	Fibrin glue	
Olmi et al. (2007) [13]	26 months ^a	TAPP	0/581	0/222	1b
Lau et al. (2005) [44]	1.2 years ^a	TEP	0/94	0/92	1b
Lovisetto et al. (2007) [14]	11.7 months	TAPP	0/98	1/99	1b
Ceccarelli et al. (2008) [20]	19 (4-40) months ^b	TAPP	0/87	0/83	3b
Santoro et al. (2007) [22]	13.2 (5-24) months ^b	TAPP	0/245	0/250	3b
Schwab et al. (2006) [23]	23.7 (11-47) months ^b	TEP	5/87	2/86	3b
Novik al (2006) [24]	1, 16, 40 months	TEP	0/96	0/9	3b
Toprat et al. (2005) [25]	28.3 ± 10.9 months ^b	TEP	3/117	1/81	3b
	23.9 ± 11.3 months ^b				
Total			8/1405	4/922	
			0,6%	0,4%	

^a Median; ^b mean (range)

Table 2. Acute pain after fixation with staples versus fixation with fibrin glue (2).

Study	Repair	Acute pain		P-value	Level of evidence
		Staples	Fibrin glue		
Lau et al. (2005) [44]	TEP	=	=	n.s.	1b
Olmi et al. (2007) [13]	TAPP	↑	↓	<0.05	1b
Boldo et al. (2008) [12]	TAPP	↑	↓	<0.05	2b

Table 3. Chronic pain after fixation with staples versus fixation with fibrin glue (2).

Study	Pain score	Repair	Chronic pain		P-value	Level of evidence
			Stapling device	Fibrin glue		
Lau et al. (2005) [44]	Linear scale	TEP	=	=	n.s.	1 b
Lovisetto et al. (2007) [14]	VAS (6 mo)	TAPP	↑	↓	<0.001	1 b
Boldo et al. (2008) [12]	VAS (1 week)	TAPP	=	=	n.s.	2b
Topart et al. (2005) [25]	Chronic pain	TEP	↑	↓	0.037	3b
Schwab et al. (2006) [23]	Chronic pain	TEP	↑	↓	0.002	3b
Ceccarelli et al. (2008) [20]	Chronic pain	TAPP	=	=	n.s.	3b

Chronic Pain

There are strong data for omitting staple fixation in order to reduce chronic pain (Table 3).

Costs

Costs were analyzed in three randomized controlled trials. Only one study included not only the costs for endoscopic equipment but also for hospitalization and surgery, including anesthesia, time spent in the operating room, and materials (3). In various randomized controlled trials, the costs due to the use of fibrin glue ranged from \$120 to \$517. Today, the use of acryl glue makes these procedures much cheaper.

As can be seen, the statements are unequivocal: in order to prevent acute and chronic pain, adhesive materials (“glue”) are superior to stapler fixation devices (“tacks”). There is also no need to repeat similar studies with tacks (or staples) in local general hospitals because it is clear that we can (unintentionally) cause acute or chronic pain by tacking. Surgeons should especially be warned against (blind) peritoneal closure with tacks because they can harm the vascular and neural structures lying behind. The peritoneum should be closed in an atraumatic way for deeper structures (suturing or sticking with glue).

Is stapling for TAPP nowadays an absolute no-go? Yes. Patients with large hernias (L3, M3), who—according to old school—would be candidates for mesh fixation with one or more tacks in “permitted” spots (close to the iliopubic tract medially), may profit as much or even more from a slightly larger mesh (17 × 12 cm) that is fixed with glue.

References

1. Taylor C, Layani L, Liew V, et al. Laparoscopic inguinal hernia repair without mesh fixation: early results of a large randomized clinical trial. *Surg Endosc.* 2008;22:757–62.
2. Bittner R, Arregui ME, Bisgaard T, et al. Guidelines for laparoscopic (TAPP) and endoscopic (TEP) treatment of inguinal hernia [International Endohernia Society (IEHS)]. *Surg Endosc.* 2011;25:2773–843.
3. Moreno-Egea A, Torralba Martinez JA, Morales Cuenca G, et al. Randomized clinical trial of fixation vs nonfixation of mesh in total extraperitoneal inguinal hernioplasty. *Arch Surg.* 2004;139:1376–9.



LAP 68 4.1 10/2019/A-SL

 **EndoCAMeleon**[®]



Adjustable in Every Aspect

The *NEW* ENDOCAMELEON[®]

- Variable direction of view 0° – 90°
- Optimized illumination
- Extremely beneficial for anatomically narrow working spaces
- Displays various anatomical structures without exchanging trocars

KARL STORZ SE & Co. KG, Dr.-Karl-Storz-Straße 34, 78532 Tuttlingen/Germany
KARL STORZ Endoskopija d.o.o., Cesta v Gorice 34b, 1000 Ljubljana/Slovenia
www.karlstorz.com

STORZ
KARL STORZ – ENDOSKOPE
THE DIAMOND STANDARD

75
Years

Adhesive Techniques for Mesh and Peritoneum Fixation in Laparoscopic Inguinal Hernia Repair

Radenko Koprivica, Sanjanin Perišić, Manuela Kuhar Makoter

Department of Abdominal Surgery, Murska Sobota General Hospital

CORRESPONDENCE

Radenko Koprivica, MD, PhD
koprivica.radenko@gmail.com

KEY WORDS

TAPP, mesh fixation, adhesive technique, cyanoacrylate, peritoneal closure, pain

RESEARCH ARTICLE

SURGERY SURG ENDOS 2020; 2(2):
11-16

Abstract

Background. Standard hernia repair methods employ open or laparoscopic techniques involving mesh fixation with tissue-perforating methods, mesh fixation with adhesive, and non-fixation methods. The European Hernia Society Guidelines state that the use of glue adhesives for mesh fixation and peritoneal closure reduces acute and chronic postoperative pain compared to mesh fixation with tissue-perforating methods.

Methods. Between February 1st, 2018 and August 31st, 2018 we prospectively monitored 20 patients that underwent laparoscopic transabdominal preperitoneal (TAPP) inguinal hernia repair. In Group 1, patients underwent mesh fixation and peritoneum closure with tacks. In Group 2, mesh fixation and peritoneum closure were performed with a laparoscopic instrument using the adhesive *n*-butyl-2-cyanoacrylate (NBCA). There were 10 patients in each group. For both groups we used a light polypropylene titanium mesh measuring 10 × 15 cm. Analgesic therapy after surgery was the same for all patients. All patients were discharged on postoperative day 1. We recorded the performance of mesh and peritoneum fixation, and postoperative pain, measured with a visual analogue scale (VAS). We also followed early postoperative complications: hematomas, wound infections, and recurrent hernias. Follow-up visits were performed on postoperative days 1, 6, and 30. In the statistical analysis we used standard descriptive statistics, single- and two-factor analyses of variance, a multiple ranking test, Mood's median test, and Tukey's test.

Results. The average age of patients was 53.7 years without significant differences between the groups. During the 30-day follow-up there were no recurrent hernias, wound infections, or hematomas in either of the groups. A two-factor analysis of variance, multiple range test (LSD), and Tukey's test showed that there was no statistically significant difference between the two groups. A single-factor analysis of variance showed that the difference between the three samples in Group 1 was not statistically significant. A multiple range test (LSD) showed that only the difference between the first and third sample in

Group 1 was statistically significant. A single-factor analysis of variance for Group 2 showed that the difference between the three samples in Group 2 was statistically significant. Mood's median test showed that the difference between all three samples in Group 2 was statistically significant. Multiple range tests showed that, of the fifteen possible comparisons, the difference was statistically significant between seven sample comparisons and was not significant in nine comparisons. The test also showed that the pain on the VAS scale was the same in patients in Group 1 at 30 days as in Group 2 patients at 6 days. The pain intensity was the same in patients in Group 1 (tacks) on postoperative day 30 and patients in Group 2 (glue) on postoperative day 6.

Conclusion. Adhesive techniques are a better option than penetrant fixation techniques for preventing and reducing postoperative chronic pain after TAPP repair.

Introduction

Inguinal hernia surgery is the most commonly performed operation in Europe and the United States (1, 2). Standard methods of operation are open or laparoscopic techniques involving mesh fixation with tissue-perforating methods, mesh fixation with adhesive, and, finally, non-fixation methods (3–5). Non-fixation mesh methods are simple, with little postoperative pain, but there are complications such as large mesh mobility, lower tensile strength, and a high percentage of hernia recurrence (6). Fixation methods in laparoscopic techniques in a meta-analysis compared to non-fixation have shown that there is no statistically significant difference in the percentage of hernia relapse (7). The current International Endohernia Society (IEHS) guidelines recommend the use of non-fixation techniques in transabdominal preperitoneal (TAPP) hernia repair, which should be considered as types: lateral (L1 and L2) and medial (M1 and M2) inguinal hernias (European Hernia Society (EHS) classification) (8). There are three categories of adhesives for fixation: synthetic adhesives, biological adhesives, and genetically engineered polymeric adhesives (9, 12). The use of adhesive for mesh fixation decreases postoperative complications compared to tissue-perforating methods (3, 10, 12). According to EHS guidelines, the use of glue adhesives

for mesh fixation and peritoneal closure reduces acute and chronic postoperative pain compared to mesh fixation with tissue-perforating methods (5, 11, 12).

Methods

Between February 1st, 2018 and August 31st, 2018 we prospectively monitored 20 patients divided into two groups: Group 1 consisted of patients undergoing the TAPP procedure with mesh and peritoneum closure with tacks, and Group 2 consisted of patients undergoing the TAPP procedure with mesh and peritoneum closure with glue. There were 10 patients in each group. The inclusion criteria were the following: male, adult, and classified by the American Association of Anesthesiologists (ASA) class I–III. Patients with direct, indirect, or bilateral inguinal hernia to L1–3 or M1–3 were enrolled according to the EHS classification. Exclusion criteria were the following: female; large inguinoscrotal hernia; severe comorbidity; use of an anticoagulant, corticosteroid, or immunosuppressive; and psychiatric therapy. In Group 1, mesh and peritoneum fixation was performed with tacks (Ethicon™ SecureStrap®, an absorbable strap fixation device, Johnson & Johnson). In Group 2 the mesh and peritoneum were fixed with a laparoscopic instrument using the adhesive *n*-butyl-2-cyanoacrylate (NBCA; LiquiBand® Fix8™ by Advanced Medical Solutions). In both groups, we used a light polypropylene titanium mesh measuring 10 × 15 cm (TiLENE® Blue, pfm medical). All patients were operated on by the same surgeon. In Group 1 we fixed the mesh with an average of five to seven tacks, and the peritoneum was fixed with an average of seven or eight tacks. In Group 2, fixation with adhesive was performed in approximately the same number of focal points as in Group 1. In Group 2, after fixation of the mesh, the intra-abdominal pressure dropped from 14 mmHg to 6 to 8 mmHg, and then the peritoneum was fixed with glue. After that we released the gas from the abdomen, and after 5 minutes we again performed pneumoperitoneum at 8 mmHg and performed an inspection for the success of peritoneum fixation. Analgesic therapy after surgery was the same for all patients: paracetamol 1 gram intravenously four times/day on the 1st day, and paracetamol 500 mg orally three times daily for another 3 days. The patients were discharged on postoperative day 1. We recorded

the performance of mesh and peritoneum fixation, and postoperative pain, measured with a visual analogue scale (VAS). We also followed early postoperative complications: hematomas, wound infection, and recurrent hernias. Controls were performed on postoperative days 1, 6, and 30. In the statistical analysis we used standard descriptive statistics, single- and two-factor analyses of variance, a multiple ranking test, Mood's median test, and Tukey's test.

Results

The average age of patients was 53.7 years without significant differences between the groups. There were four patients with bilateral inguinal hernias, nine with right-sided inguinal hernias, and seven with left-sided inguinal hernias. There was no difference in the distribution of hernias by group. The distribution of hernia size in both groups was similar in 50% of cases of L2 or M2, in 30% of L1 or M1, and in 20% of L3 or M3 according to the EHS classification. During the 30-day follow-up, there were no recurrent hernias, wound infection, or hematomas in both groups. In Group 1, the mesh and peritoneum were fixed with tacks. In Group 2 the peritoneum and mesh were fixed with glue. Compared by the parameters tested, the groups were similar (Table 1). The average time of surgery in Group 1 was 45 minutes, and in Group 2 it was 51 minutes.

In Group 1, on postoperative day 1, the average pain measured by the VAS scale was 2.1, on postoperative day 6 it was 1.3, and on postoperative day 30 it was 0.8. In Group 2, the average pain on postoperative day 1 was 2, on postoperative day 6 it was 0.8, and on postoperative day 30 it was 0.4. (Table 2).

A two-factor analysis of variance showed that there was no statistically significant difference between the two groups. However, the difference between samples in groups, or the time of pain assessment, was statistically significant at $p < 0.0001$ (Table 3). A multiple range test (least significant difference, LSD) and Tukey's test confirm that there was no statistically significant difference between the two groups.

A single-factor analysis of variance showed that the difference between the three samples in Group 1 was not statistically significant because $p > 0.05$. A multiple range test (LSD) showed that only the difference between the first and third samples in Group 1 was statistically significant.

Mood's median test also showed that the difference between all three samples was not statistically significant. However, in this case, there was only about an 8% probability that the difference could be random ($p = 0.0785$).

A single-factor analysis of variance for Group 2 showed that the difference between the three samples in Group 2 was statistically significant because $p < 0.0001$ (F ratio = 15.6). The difference

Table 1. Distribution by group. BIH = bilateral inguinal hernia, RIH = right-sided inguinal hernia, LIH = left-sided inguinal hernia, L = lateral, M = medial, EHS = European Hernia Society classification

Condition	Group 1		Group 2	
	n	%	n	%
BIH	2	20	2	20
RIH	4	40	5	50
LIH	4	40	3	30
L1, M1 (< 1.5 cm) EHS	3	30	3	30
L2, M2 (1.5–3 cm) EHS	5	50	5	50
L3, M3 (> 3 cm) EHS	2	20	2	20
Hematoma	0	0	0	0
Wound infection	0	0	0	0
Recurrent inguinal hernia	0	0	0	0
Mesh fixation	10	100	10	100
Peritoneum closure	10	100	10	100

Group 1				Group 2			
Patient	Day 1	Day 6	Day 30	Patient	Day 1	Day 6	Day 30
1	3	2	1	1	2	1	0
2	2	0	0	2	2	0	0
3	1	0	0	3	2	1	1
4	0	0	0	4	2	0	0
5	0	0	0	5	2	1	0
6	4	1	1	6	3	2	1
7	3	2	2	7	3	1	1
8	3	3	2	8	2	1	0
9	2	2	1	9	2	1	1
10	3	3	1	10	0	0	0
Average	2.1	1.3	0.8	Average	2	0.8	0.4

Table 2. Postoperative pain measured by a visual analogue scale (VAS), distribution by group and time.

Source	Sum of squares	Df	Mean square	F ratio	p-value
Main effects					
A: group	1.66667	1	1.66667	1.90	0.1732
B: days	22.0333	2	11.0167	12.58	0.0000
Residual	49.0333	56	0.875595		
Total (corrected)	72.7333	59			

Table 3. Two-factor analysis of variance for both groups.

between the first and second samples, and between the first and third samples in Group 2 was statistically significant. The difference between the second and third samples was not statistically significant. Mood's median test showed that the difference between all three samples in Group 2 was statistically significant ($p < 0.0001$).

The variance analysis showed that the difference between all six samples from both groups of observations together was statistically significant ($p < 0.0001$).

Multiple range tests showed that, of the 15 possible comparisons, the difference was statistically significant between seven sample comparisons and was not significant in nine comparisons. The test also showed that the pain in the VAS scale was the same in patients in Group 1 on postoperative day 30 as in Group 2 on postoperative day 6. The pain was much less when the adhesive was used,

and in practice patients that underwent the adhesive technique reached a condition with less pain much faster (Table 4, Figure 1).

Discussion

In order to avoid injury to nerves, blood vessels, and adhesions, penetrating agents for mesh fixation in hernioplasty should not be used (9, 10, 12). According to IEHS recommendations, fibrin glue should be used for retinal fixation in TAPP hernioplasty (8). There are some advantages of NBCA over fibrin glue, including stronger mesh fixation, gluing the peritoneal flap, and the possibility of adhesion of incisions on skin. The drawback of NBCA is that it is not bioresorbable (9). In all cases, we fixed the mesh with adhesive. There was no difference in the percentage of mesh and perito-

Table 4. Multiple range test for six samples at the same time. G1 = Group 1, G2 = Group 2.

Group, day	Count	Mean	Homogenous groups
G2, day 30	10	0.4	X
G1, day 30	10	0.8	XX
G2, day 6	10	0.8	XX
G1, day 6	10	1.3	XX
G2, day 1	10	2.0	X
G1, day 1	10	2.1	X

Figure 1. Least significant difference multiple range test.

Contrast	Sig.	Difference	+/- limits
G1, day 1 – G1, day 6		0.8	0.8506
G1, day 1 – G1, day 30	*	1.3	0.8506
G1, day 1 – G2, day 1		0.1	0.8506
G1, day 1 – G2, day 6	*	1.3	0.8506
G1, day 1 – G2, day 30	*	1.7	0.8506
G1, day 6 – G1, day 6		0.5	0.8506
G1, day 6 – G2, day 1		-0.7	0.8506
G1, day 6 – G2, day 6		0.5	0.8506
G1, day 6 – G2, day 30	*	0.9	0.8506
G1, day 30 – G2, day 1	*	-1.2	0.8506
G1, day 30 – G2, day 6		0	0.8506
G1, day 30 – G2, day 30		0.4	0.8506
G2, day 1 – G2, day 6	*	1.2	0.8506
G2, day 1 – G2, day 30	*	1.6	0.8506
G2, day 6 – G2, day 30		0.4	0.8506

neum fixation, hernia recurrence, and wound infection between groups. Tissue adhesives cause a small inflammatory response, improve wound healing, and are bacteriostatic (13–15). Reduction of postoperative pain in laparoscopic hernioplasty using adhesive is faster than in laparoscopic hernioplasty using penetrating fixation methods (16, 17). The analysis of the results in this article showed that patients with TAPP procedures with adhesive fixation have less postoperative pain. On average, on the VAS scale, a patient that underwent adhesive fixation had the same pain on postoperative day 6 as a patient that underwent a fixation tacker on postoperative day 30. Such a patient recovers much faster because pain reduction is an important determinant of the duration

of convalescence (16, 17). Recovery duration and chronic postoperative pain are an important socioeconomic problem because inguinal hernioplasty is the most commonly performed procedure in general surgery (17–19). Good results in the reduction of chronic postoperative pain and a lower percentage of recurrent operations are resulting in increasing use of NCBA adhesive for mesh fixation, with an increasing number of published publications on the topic (10). Ileus after TAPP repair due to poor closure of the peritoneum may occur in the early postoperative period (20). Peritoneal closure using NBCA is a safe and secure method that, at a clinical follow-up of 12 months, showed no serious complications associated with the application technique. In 90% of cases, Dauser et al.

achieved peritoneal adhesion by using LiquiBand® Fix8™ adhesive (12). In this article, in all 10 cases we achieved closure of the peritoneum with adhesive. According to literature data, peritoneal adhesive closure is feasible in many cases, with restrictions related to anatomical conditions that prevent adhesion (e.g., adhesions of the sigmoid colon with strong traction to the distal peritoneal flap) (12). Of course, there are no recommendations for the exclusive use of NBCA for peritoneal closure (12, 21).

Conclusion

NBCA adhesive is a perfect method for fixing the mesh and peritoneum in TAPP repair. The method is simple, safe, and very feasible. Adhesive techniques are a better option than penetrant fixation techniques for preventing and reducing postoperative chronic pain after TAPP repair.

References

1. Matthews RD, Neumayer L. Inguinal hernia repair in the 21st century: an evidence-based review. *Curr Probl Surg*. 2008;45:261–312.
2. Primatesta P, Goldacre MJ. Inguinal hernia repair: incidence of selective and emergency, readmission and mortality. *Int J Epidemiol*. 1996;25:835–9.
3. Fortelny RH, Petter-Puchner AH, Glaser KS, et al. Use of fibrin sealant (Tisseel/Tissucol) in hernia repair: a systematic review. *Surg Endosc*. 2012;26:1803–12.
4. Petter-Puchner AH, Brunner W, Gruber-Blum S, et al. A systemic review of hernia surgery in SIL (single-incision laparoscopy) technique. *Eur Surg*. 2014;46:113–4.
5. Fischer S, Zechmeister-Koss I. Is day surgery safe? A systematic literature review. *Eur Surg*. 2014;46:103–12.
6. Katkhouda N, Mavor E, Friedlander MH, et al. Use of fibrin sealant for prosthetic mesh fixation in laparoscopic extraperitoneal inguinal hernia repair. *Ann Surg*. 2001;233:18–25.
7. Sajid MS, Ladwa N, Kalra L, et al. A meta-analysis examining the use of tacker fixation versus no-fixation of mesh in laparoscopic inguinal hernia repair. *Int J Surg*. 2012;10:224–31.
8. Bittner R, Montromery MA, Arregui ME, et al. International Endohernia Society. Update of guidelines on laparoscopic (TAPP) and endoscopic (TEP) treatment of inguinal hernia (International Endohernia Society). *Surg Endosc*. 2015;29:289–321.
9. Fortelny RH, Petter-Puchner AH, Walder N, et al. Cyanoacrylate tissue sealant impairs tissue integration of macroporous mesh in experimental hernia repair. *Surg Endosc*. 2007;21:1781–5.
10. Fortelny RH, Petter-Puchner Ah, May C, et al. The impact of a traumatic fibrin sealant vs. staple mesh fixation in TAPP hernia repair on chronic pain and quality of life. Results of a randomized controlled study. *Surg Endosc*. 2012;26:249–54.
11. Kuketa JF, Freytag C, Weber M, et al. Efficiency and safety of mesh fixation in laparoscopic inguinal hernia repair using n-butyl-cyanoacrylate: long-term biocompatibility in over 1,300 mesh fixations. *Hernia*. 2012;16:153–62.
12. Dauser B, Syszkowitz A, Seitingner G, et al. A novel glue device for fixation of mesh and peritoneal closure during laparoscopic inguinal hernia repair: short and medium-term results. *Eur Surg*. 2017;49:27–31.
13. Lee MGM, Jones D. Applications of fibrin sealant in surgery. *Surg Innov*. 2005;12:203–13.
14. Ryou M, Thompson CC. Tissue adhesives: a review. *Tech Gastrointest Endosc*. 2006;8:33–7.
15. ASGE Technology Committee, Bhat YM, Banerjee S, Barth BA, et al. Tissue adhesives: cyanoacrylate glue and fibrin sealant. *Gastrointest Endosc*. 2013;78:209–15.
16. Bay-Nielsen M, Thomsen H, Andersen FH, et al. Convalescence after inguinal herniorrhaphy. *Br J Surg*. 2004;91:362–7.
17. Callesen T, Klarskov B, Bech K, Kehlet H. Short convalescence after inguinal herniorrhaphy with standardised recommendations: duration and reasons for delayed return to work. *Eur J Surg*. 1999;165(3):236–41.
18. Kehlet H, Jensen TS, Woolf CJ. Persistent postsurgical pain. Risk factors and prevention. *Lancet*. 2006;367:1618–25.
19. McCormack K, Wake B, Perez J, et al. Laparoscopic surgery for inguinal hernia repair: systematic review of effectiveness and economic evaluation. *Health Technol Assess*. 2005;9(14):1–203.
20. Helvind NM, Andersen K, Rosenberg J. Lower reoperation rates with the use of fibrin sealant versus tacks for mesh fixation. *Surg Endosc*. 2013;27:4184–91.
21. Matthews RD, Neumayer L. Inguinal hernia in the 21st century: an evidence-based review. *Curr Probl Surg*. 2008;45:261–312.

Standardization and Safety in Bariatric Surgery: Preventing Liver Failure

Tadeja Pintar

Department of Abdominal Surgery, Ljubljana University Medical Center

CORRESPONDENCE

Asst. Prof. Tadeja Pintar, MD, PhD
tadeja.pintar@kclj.si

KEY WORDS

bariatric surgery, standard procedures, complications, liver deterioration

RESEARCH ARTICLE

SURGERY SURG ENDOS 2020; 2(2):
17-22

Abstract

Introduction. Anatomical configurations of bariatric surgery procedures must be standardized for surgical practice, patient outcomes, and research. Standardization offers clinical safety and importantly reduces the overall complication rate; that is, surgical and metabolic complications that significantly increase morbidity and mortality. The primary characteristics of the procedures, dimensions, and volumes of the final anatomy created influence the bariatric and metabolic outcomes.

Methods and results. Twenty-two types of bariatric surgery procedures and 50 surgical anatomical variations have been described. Different grades of non-alcoholic fatty liver disease (NAFLD) and non-alcoholic steatohepatitis (NASH) are present in obese patients that are candidates for bariatric surgery. Standard and implemented patient preparation for surgery is the key point in avoiding common causes of mortality for liver disease after bariatric surgery, such as alcohol abuse, viral infection, autoimmunity, and psychosocial behavior with developed anorexia leading to liver insufficiency due to a prolonged state of severe malnutrition. Routine nutritional screening and supplementation according to the surgical technique after bariatric surgery is mandatory.

Conclusions. Algorithms in bariatric surgery are mandatory to prevent life-threatening postoperative complications. The individual bariatric procedure must include precise anatomical measurements; that is, a definitive anatomic reconfiguration standard. This also includes re-do procedures and a description of the naive abdominal anatomical situation and preexisting abdominal pathology. This can improve targeting treatment for particular complications and aspects of metabolic disease. Procedure variants should vary from a single definition standard among the range of surgical interventions recognized. Long-term postoperative follow-up importantly reduces morbidity and is a primary requirement for early diagnosis of pathology. Diagnostic and therapeutic procedures must be performed at highly experienced tertiary centers with multidisciplinary and intensive-care treatment capacities.

Introduction

Metabolic surgery was defined as the “operative manipulation of a normal organ or organ system to achieve a biological result for a potential health gain” by Buchwald and Varco in 1978 (1). Surgical interventions for morbid obesity address impairments and mostly weight-independent regulatory mechanisms in the neurohormonal network and microbiome; treatment of obesity-related diseases reconfigures essentially normal organs. To date, 50 different operations have been described and offered to manage the critical global threat of obesity and metabolic syndrome. Recent data presented by Bhandari et al. in the World Consensus Meeting Statement show that 579,517 bariatric metabolic operations and 14,725 endoluminal procedures are performed annually worldwide for reducing body weight and improving or resolving a wide range of comorbid diseases (2). Thus, in the long term, these surgical interventions are the only effective, safe, and durable therapeutic option for most patients with obesity.

The wide range of different procedures also reflects the understanding of surgeons and bariatric teams. Globally, the most frequent surgical interventions for morbid obesity are sleeve gastrectomy (SG, 45.9%), Roux-en-Y gastric bypass (RYGBP, 39.6%), laparoscopic adjustable gastric banding (LAGB, 7.4%), and biliopancreatic diversion (duodenal switch, BPD/DS, 1.1%). Novel techniques have been introduced in the last decade, both surgical and endoluminal, but are currently only associated with short-term evidence.

The procedure’s finished anatomic configuration (i.e., precise measurements and reconfiguration) will improve procedure safety and weight-loss effectiveness, and it will reduce short- and long-term complications. Severe liver dysfunction may occur after bariatric procedures due to a combination of restriction, malabsorption, and primary malabsorptive procedures. The length of the alimentary and biliary limb should be adapted to the length of the small intestine to prevent life-threatening malabsorptive conditions and organ failure.

Discussion

Bariatric surgeries trigger different adaptive mechanisms responsible for reestablishment of liver function as well as deterioration. The underlying mechanisms inducing impairment are a) rapid and drastic weight loss, b) protein-calorie malnutrition, and c) gut microbiota alteration and bacterial overgrowth. Progression of preexisting liver inflammation is regulated by the gut-liver axis; modulation of the metabolic and immune system is triggered by intestinal flora, which importantly contribute to energy homeostasis and metabolism and to the intestinal barrier function. The state of dysbiosis in the liver represents the first filtrating system for the mesenteric system adapted after obesity surgery interventions. Mechanisms involved in liver function deterioration include the systemic load of inflammatory cytokines involved in liver fibrosis, dietary choline metabolism change, impaired bile flow and acid metabolism, endogenous ethanol production, and increased intestinal permeability triggered by small intestinal bacterial overgrowth (SIBO).

SIBO and subsequent liver damage are encouraged by the long length of bypassed intestine in predominantly malabsorptive procedures, the dysmotility of the Roux limb after standard Roux-en-Y bypass surgery (3) and impaired bile circulation, distal bypass techniques with a long biliary limb and gastric acid reduction in small pouch size techniques typical for restrictive surgeries, and small anastomosis with bowel obstruction.

Severe calorie and protein deficiency due to malabsorption resulting from bariatric surgery technique also triggers reduced apolipoprotein liver synthesis and as a consequence weakens the liver’s antioxidative capacity. This also accelerates liver fibrosis under the circumstances of excessive weight loss (EWL%) and worsens steatosis (4, 5). Combining hybrid bariatric techniques also has an impact. Among many factors, the following are significant for liver damage following bariatric surgery: metabolic syndrome, diabetes, hyperlipidemia, and arterial hypertension. Among metabolic comorbidities, a major role is associated with non-alcoholic fatty liver disease (NAFLD), which is evaluated as a high risk for liver failure in combination with an extended-length limb.

Both non-alcoholic steatohepatitis (NASH) and NAFLD have been shown to be effective in weight

loss and improvement in liver pathology (5, 6). To obtain optimal clinical and long-term results, appropriate patient selection for bariatric surgery combined with a meticulous surgical technique may allow patients with liver failure to undergo mainly sleeve gastrectomy with an acceptable low rate of complications and effective weight loss and related improvement of liver histology. It has been proven by Diwan et al. that a lower body mass index at the time of liver transplantation could decrease the risk of wound complications in the short term and recurrent NASH in the long term (7). In contrast, Keleidari et al. (5) showed that the incidence of liver failure after bariatric surgery is higher after a history of revisional bariatric surgery, mainly in malabsorptive procedures. Thus, for prior malabsorptive procedures and especially all revisional surgeries, evaluation of liver histology should be a standard procedure to avoid worsening of preexisting liver damage due to obesity-related metabolic liver disease. Moreover, all non-operative measures should be implemented—including nutritional treatment, and metabolic and non-surgical support—to prevent exacerbation of liver disease.

To prevent life-threatening complications of obesity surgery, some strong recommendations play a key role in current surgical practice: the length of the biliary limb, the length of the alimentary limb, a common channel, and the total length of the small bowel (2, 5, 8). Factors that can slightly influence the proposed criteria are sex, age, height, stomach size, and type of anastomosis.

Malabsorption is the consequence of extended restriction and malabsorptive component (5). The result is hypoalbuminemia, which is the leading cause of NASH. NASH has also resulted in portal hypertension reducing intestinal absorption, representing a vicious cycle. The only treatment modality in this clinical situation is revisional surgery, i.o. re-establishment of the natural anatomy and supportive parenteral nutrition. The timing is crucial to prevent liver failure and irreversible clinical circumstances. Postoperative follow-up is important to prevent post-bariatric liver failure: physical examination, routine serologic screening, metabolic screening, and a liver biopsy. A hydrogen breath test is suggested for any suspicious SIBO, and radiologic and endoscopic evaluation is suggested in cases of gastrointestinal obstruction that can suddenly cause deterioration in the liver's metabolic condition (5, 9).

Small intestinal bacterial overgrowth is indicated by flatulence, bloating, nausea, abdominal discomfort and cramps, weight loss, and steatorrhea; the exact diagnostic pool is a ¹⁴C-D-Xylose test and a urinary or serum test; anemia may be macrocytic or microcytic, and associated with lymphopenia, low serum prealbumin and transferrin, depletion of fat-soluble vitamins, and elevated levels of folate and vitamin K. Prompt management of nutritional deficiencies induced by bariatric surgery suppresses the effect of SIBO. An immune enteral formula will restore the intestinal barrier and decrease translocation and the related systemic effect of bacterial overgrowth. Attention should be directed toward a total parenteral nutrition (TPN) formula; enteral feeding is highly recommended to prevent TPN-related additional liver steatosis and catheter-related complications (3, 5, 8). Among restrictive recommendations are fructose enteral load; protein supplementation and pancreatic enzymes should be balanced, and thiamine deficiency diagnosed as the most frequent source of SIBO. The benefit from early digestion in the upper bowel by introducing a nasogastric tube into the remnant stomach promotes the immune-enhancing capacity, biliopancreatic limb recovery, and SIBO reduction.

Importantly, screening for nutritional deficiencies after surgery prevents the hypoalbuminemia and subsequent liver insufficiency described after malabsorptive bariatric procedures and in other clinical circumstances described with poor patient follow-up and non-standard surgical procedures with unpredictable metabolic effects (10). Extensive hypoalbuminemia and bacterial overgrowth trigger the production of hepatotoxic macromolecules with additional liver damage. In a state of starvation and extensive malabsorption, liver insufficiency might be caused by acute cell necrosis due to autophagy, dehydration in extensive diarrhea with hypovolemia, and poor blood circulation through the liver.

All measurements should be oriented toward patient selection for type of surgery in both primary and re-do bariatric surgery for treatment failure. Very mild clinical and pathological liver disease can deteriorate into clinically critical liver disease even in standard procedures with mild malabsorption procedures. Restoration of anatomy and nutritional support are the first treatment modalities.

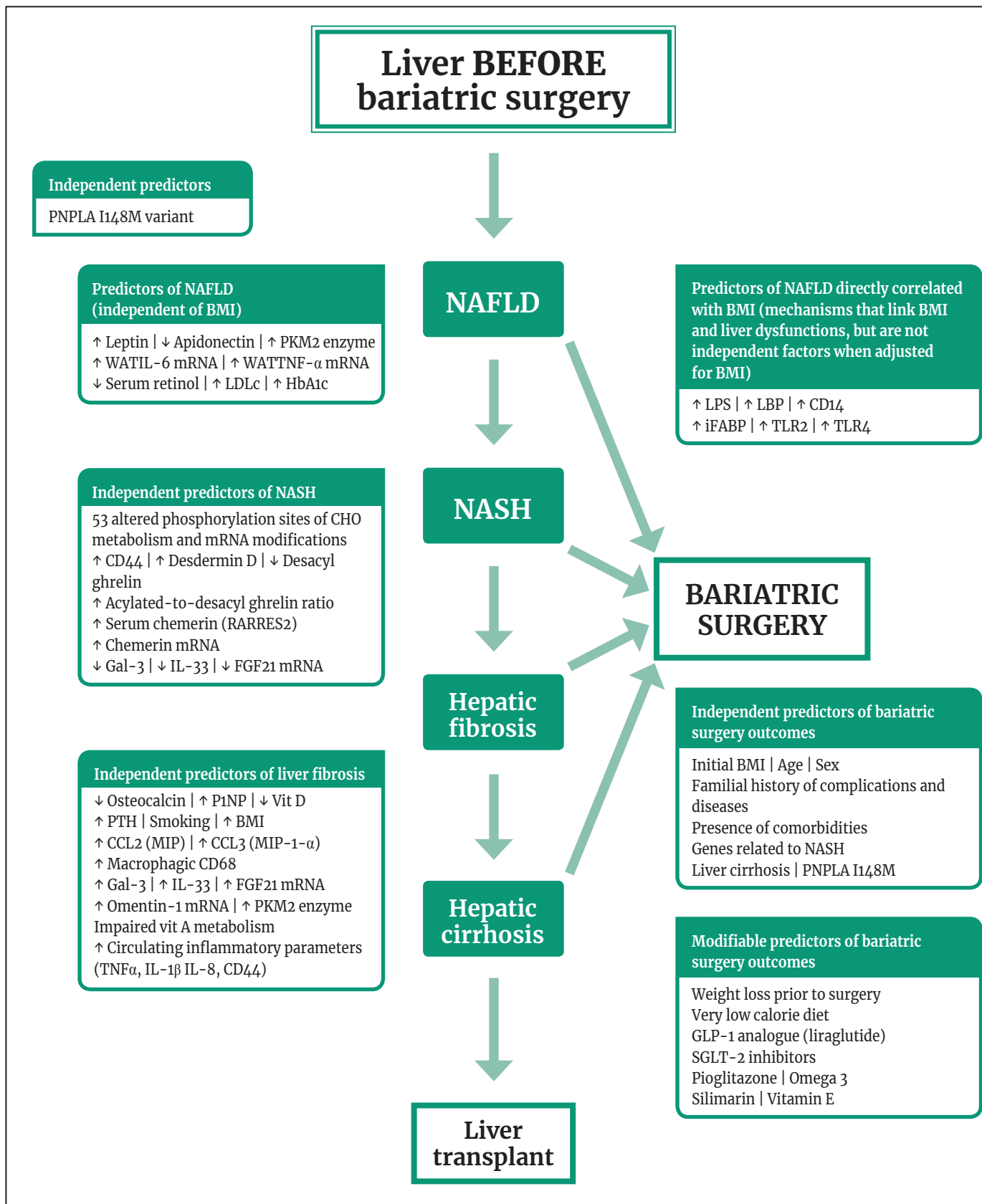


Figure 1. Liver before and after bariatric surgery (4). BMI = body mass index, CCL = chemokine ligand, CD = cluster of differentiation, CHO = carbohydrate, FGF = fibroblast growth factors, Gal = galactin, GLP = glucagon-like peptide, iFABP = intestinal-type fatty acid binding protein, IL = interleukin, LBP = lipopolysaccharide-binding protein, LPS = lipopolysaccharides, MIP = macrophage inflammatory protein, NAFLD = non-alcoholic fatty liver disease, NASH = non-alcoholic

Liver AFTER bariatric surgery

Improvements independent of weight loss
Improvements last for several years

As fast as 3 to 6 months after surgery
Improvements are highly heterogeneous

Useful evaluation methods

Improved liver histology

Intraoperative liver biopsy

Biochemical markers

- ↑ Leptin (adjusted for body fat)
- ↓ Intrahepatic fat (biopsy)
- ↑ Resistin = ↓ NASH
- ↑ Adiponectin = ↑ HDLc
- ↑ VCAM-1 = ↑ Liver fibrosis
- ↑ BA = multiple metabolic improvement

Liver fibrosis:
reduction up to 70%
Improvements in up to 100%
a. Hepatocellular ballooning
b. Lobular inflammation
c. steatosis

MRI

High correspondence with liver biopsy
21,7% liver volume reduction
83,7% NAFLD remission (PDF criteria)

Improved markers, proteins, enzymes and gene expressions

Fibro-scan

Overall almost 50% improvement of LSM and CAP

Normalization of ALT / GGT
↑ FGF19 | ↑ FGF21 | ↑ BA
↓ Desacyl ghrelin
↑ Acylated-to-desacyl ghrelin ratio
↓ VCAM-1 | ↓ PTP1B
↓ ACC mRNA | protein
↓ FASN mRNA | protein
↓ G6Pasc | ↓ PEPCK
↑ *Proteobacteria* | ↑ *Bacteroidetes*
↓ *Firmicutes*

Biomarkers, proteins and enzymes

ELF

HA +TIMP1 + PIIINP
Accuracy: 72% to predict NASH

BARD

99% NPV for liver fibrosis; low accuracy

ICG

Strict correlation with liver histology

Multi-component classification for NAFLD

Combination of genome, proteome and phenome panels
Predicts 93,5% of the liver function in BS

↑ Omega 6 metabolism
↓ Inflammatory pathways
↓ CYP7A1 | ↑ mitofusins
↓ CD 36 | ↓ PAI1
↑ APOB | ↑ PPARA | ↑ SCARB1

Gene expressions

94% when mild
70% when moderate/severe

Remission of NASH

+

Improvement of liver fibrosis

+

Prevention of liver transplant

steatohepatitis, P1MP = procollagen type I propeptide, PK = pyruvate kinase, PNPLA = patatin-like phospholipase domain-containing, RARRES = retinoic acid receptor responder protein, SGLT = sodium-glucose linked transporter, TLR = toll-like receptors, TNF = tumor necrosis factor, WAT = white adipose tissue.

Conclusion

Reversal of bariatric procedures or lengthening the common channel is the first approach in patients with liver deterioration. Due to metabolic disease, bariatric surgery reversal and liver transplantation are treatment options; hepatic pathology may return more intensely after any surgical intervention. To avoid the clinical situations described, it is mandatory to respect a set of anatomical measurements and standardize the techniques targeting metabolic disease. Evidence-based standard procedures are necessary to prevent life-threatening complications, including liver failure due to deterioration of pre-existing metabolic liver disease.

References

1. Buchwald H, Varco RL. *Metabolic surgery*. New York: Grune & Stratton, 1978. 317 p.
2. Bhandari M, Fobi MAL, Buchwald JN, Bariatric Metabolic Surgery Standardization (BMSS) Working Group. Standardization of bariatric metabolic procedures: World Consensus Meeting Statement. *Obes Surg*. 2019;29(Suppl 4):309–45.
3. Mahawar KK, Parmar C, Graham Y, et al. Monitoring of liver function tests after Roux-en-Y gastric bypass: an examination of evidence base. *Obes Surg*. 2016;26(10):2516–22.
4. Lammers WJ, van Tilburg AJP, Apers JA, Wiebolt J. Liver failure caused by prolonged state of malnutrition following bariatric surgery. *World J Hepatol*. 2018;10(3):396–99.
5. Keleidari B, Mahmoudieh M, Gorgi K, et al. Hepatic failure after bariatric surgery: a systematic review. *Hepat Mon*. 2019;19(1):e86078.
6. Cadegiani F. The liver before and after bariatric surgery. In: Watson RR, Preedy VR, editors. *Dietary interventions in liver disease*. London: Academic Press; 2019. p. 39–58.
7. Diwan TS, Rice TC, Heimbach JK, Schauer DP. Liver Transplantation and Bariatric Surgery: Timing and Outcomes. *Liver Transpl*. 2018 Sep;24(9):1280–1287. doi: 10.1002/lt.25303. PMID: 30080949.
8. Eilenberg M, Langer FB, Beer A, et al. Significant liver-related morbidity after bariatric surgery and its reversal—a case series. *Obes Surg*. 2018;28(3):812–9.
9. Sharpton SR, Yong GJM, Terrault NA, Lynch SV. Gut microbial metabolism and nonalcoholic fatty liver disease. *Hepatol Commun*. 2018;3(1):29–43.
10. de Castro Pereira Martins T, Duarte TC, Mosca ER, et al. Severe protein malnutrition in a morbidly obese patient after bariatric surgery. *Nutrition*. 2015;31:535–8.

Surgical Management of Spontaneous Intracerebral Hematomas: An Overview and Our Results

Lina Iskra Vugdelija, Roman Bošnjak, Tomaž Velnar

Department of Neurosurgery, Ljubljana University Medical Center

CORRESPONDENCE

Asst. Prof. **Tomaž Velnar**, MD, PhD
tvelnar@hotmail.com

KEY WORDS

intracerebral hemorrhage, surgical evacuation, endoscopy, open surgery

CASE REPORT

SURGERY SURG ENDOS 2020; 2(2):
23-30

Abstract

Spontaneous intracerebral hemorrhage is an acute life-threatening form of stroke with a high mortality and disability rate. Small intracerebral hemorrhages, not causing mass effect and elevated intracranial pressure, can be treated conservatively according to basic principles of acute hemorrhagic stroke management. Selected patients with a large intracerebral hemorrhage, a high probability of hematoma expansion, and subsequent neurological deterioration or signs of elevated intracranial pressure benefit from surgical evacuation. This article presents the treatment results for supra- and infratentorial intracerebral hematomas at the Ljubljana University Medical Center from 2014 to 2018. The mortality rate in patients that were treated conservatively was 43%, versus 26% in those treated with surgical intracerebral hemorrhage evacuation. Intensive treatment aims to prevent secondary brain injury caused by hematoma mass effect, brain edema, and toxic blood lysis products.

Introduction

Patients with acute onset intracerebral hemorrhage (ICH) comprise 10 to 20% of all stroke patients worldwide, which makes ICH the second most common form of stroke (1). ICH is characterized by a high rate of mortality during the initial hospitalization period, as well as 3 months after hospital treatment, and significant long-term functional disability (2, 3).

Primary ICH refers to spontaneous nontraumatic bleeding from pathologically altered intraparenchymal vessels, with the bleeding possibly extending into the ventricles and subarachnoid space. The incidence rate is highest in older adults with associated risk factors for cerebrovascular disease, the major ones being long-standing hypertension and cerebral amyloid angiopathy (1). The most common sites of bleeding in ICH are the basal ganglia, lobar regions, thalamus, cerebellum, and

brainstem (4). Many of these locations are related to the areas of vessels affected by hypertension, whereas recurrent lobar ICH, especially in older adults, might be indicative of amyloid angiopathy (5). It should be noted, however, that the etiology could only be definitely determined by tissue pathology, which is, on the other hand, only rarely performed in clinical practice for ICH. Other risk factors for spontaneous ICH include vascular malformations, neoplasms, and coagulopathies. The later comprise hereditary and acquired clotting factor deficiencies, thrombocytopenia, and iatrogenic coagulopathy caused by anticoagulants or antiplatelet drugs. These events are referred to as secondary ICH and comprise approximately 10 to 20% of all ICH events (6).

The characteristics of ICH differ between older patients and young adults. There has been considerably less investigation done on the younger population 18 to 50 years old. Nevertheless, it is known that the risk factors for ICH may be common in older and young adults. The most frequent ones are tobacco use, hypercholesterolemia, hypertension, and alcohol abuse. Some are considered cryptogenic, and a small percentage include cerebral venous thrombosis and sympathomimetic drug use (7, 8).

Clinically, the symptoms of acute ICH can present as focal neurological deficits, depending on the location of the hemorrhage. In the case of extensive bleeding, the clinical signs and symptoms also depend on an increase in intracranial pressure. The patients that are mostly at risk of a poor treatment outcome are those in whom ICH primarily presents as an acute disturbance of consciousness. In the process of acquiring a diagnosis, basic clinical assessment is followed by emergency radiological imaging, including computer tomography and in rarer cases magnetic resonance imaging and angiography, which help determine the location, extent, and dynamics of bleeding as well as acting as a tool for treatment (6, 8).

Conservative treatment requires hospitalization in an intensive care unit where precise optimization of blood pressure, possible coagulopathy management, and reduction of brain edema are the main goals of treatment (9, 10). Due to the high incidence of early hematoma enlargement following conservative treatment, it is essential to assess the risk factors and closely monitor the neurological status for any changes. Poor prognostic factors are a hematoma volume of more than 30 ml, an ini-

tial Glasgow Coma Scale (GCS) below 8, intraventricular hemorrhage (IVH), age over 80 years, and infratentorial location of the hemorrhage. Early neurological deterioration occurs in the first 48 hours in 40% of patients and is most commonly a consequence of early hematoma expansion and the onset of brain edema (11–13). Deteriorating patients need more advanced supervision, and their treatment becomes more complex. Regarding intracranial pressure reduction, the introduction of external ventricular drainage, intracerebral pressure (ICP) monitoring, and mechanical ventilation are important. Studies have shown that the treatment outcomes of these critically ill patients are significantly better when they are treated in specialized neurointensive care units (10, 14).

Surgical treatment is considered in selected patients with extensive supratentorial infratentorial hemorrhage or IVH with a progressive neurological deterioration and after consideration that the potential for improvement outweighs the potential risks of an invasive surgical procedure. Surgical evacuation of an intracerebral hematoma is not indicated in patients for whom the location and extensiveness of the hematoma inevitably indicates a poor functional outcome despite all additional therapy (14).

The purpose of this article is therefore to present the surgical and conservative management of supra- and infratentorial hemorrhage, to stress the importance of treatment trials, and to present our surgical results at the Ljubljana University Medical Center.

Surgical Evaluation of Spontaneous Intracerebral Hemorrhage

When considering the surgical approach to ICH treatment, the outcomes of several clinical trials are available. Results considering the surgical evacuation of supratentorial hemorrhages in the available literature are lacking proof of benefit. There are no clearly defined clinical guidelines prescribing a universal treatment algorithm. The study results in the case of infratentorial hemorrhage evacuation, on the other hand, are more solid. In patients with infratentorial ICH, early surgical evacuation, in accordance with the rec-

ommendations, is indicated and has proven beneficial (15, 23).

Supratentorial Hemorrhages

In 2015, the first multicenter randomized prospective controlled trial to determine the benefit of early surgical intervention in ICH (Surgical Trial in Intracerebral Hemorrhage, STICH) was published (16). In this trial, the researchers recruited 1,033 patients and divided them into two groups. One group was considered for early surgery (within 96 hours after the initial onset of symptoms) and the other one was considered for initial conservative treatment. The findings showed that there was no statistically significant difference between the two groups in survival rate and functional outcome at 6 months of follow-up. Additional analysis showed that patients that arrived in a comatose state (GCS \leq 8) had a poorer treatment outcome. A better outcome was recorded in patients with superficial, lobar hemorrhages, who were treated surgically, compared to those that were treated conservatively. The clinical findings in these subgroups led to the STICH II trial (17). It was designed to determine the effect of early surgery on the improvement of clinical outcome compared to the initial conservative treatment or delayed surgical treatment in these patients, who presented with a supratentorial superficial lobar hemorrhage with a volume of 10 ml to 100 ml, without IVH. It was concluded that the outcome in patients with a poorer prognosis (considering the prognostic model that included the GCS score, age, and volume of ICH) had a better outcome when treated with early surgery, although the mortality was statistically insignificantly lower. One criticism of this study included a large number of transitions from initial conservative treatment to delayed surgery after the patients decompensated, which could have lowered the mortality rate in the group of patients treated conservatively. Another criticism was that surgical treatment was used for patients that were not considered severely impaired (17).

The use of decompressive craniectomy (DC) in ICH can rapidly decrease the mass effect and lower the ICP (18–20). This method with a concurrent hematoma evacuation is probably safe and can improve the outcome. The data on the use of DC without hematoma evacuation are scant, and the trials performed so far were based on a small number of patients (18, 21). However, their results show that

the treatment outcome was better compared to the outcome of conservatively treated patients with spontaneous ICH that were admitted for treatment in the same period. The mortality rate was 20% in a group of patients with DC compared to 60% in the control group. In addition, 40% of the patients treated with DC had a good outcome (Modified Rankin Score 0 to 3 points) compared to 20% of those in the control group. A retrospective study from 2013, published in the *British Journal of Neurosurgery*, showed an increased survival rate in 253 patients that underwent surgical evacuation of extensive deep ICH located in the basal ganglia (22). In that study, the decision for DC combined with hematoma evacuation was based on clinical intraoperative findings, such as brain pulsation, rigidity, herniation, and high intraoperative ICP, or subsequently in cases of deterioration due to secondary hemorrhage, diffuse edema, or malignant cerebral infarction. Apart from that, there are no clear indications for DC in spontaneous ICH. It has been found that the group of patients treated with DC had a lower ICP and better survival rates after 30 days despite the initial poor prognosis (GCS \leq 8, ICH score \geq 3, volume of hematoma \geq 50 ml). An American uncontrolled retrospective trial carried out in 74 patients treated with DC and/or hematoma evacuation observed that patients with extensive ICH of the non-dominant hemisphere had a greater benefit from the surgical procedure (21).

The most recent guidelines for the management of spontaneous ICH were published in 2016 by the American Heart Association and American Stroke Association (AHA/ASA) (23). These guidelines suggest that patients with ICH be admitted to an intensive care unit or dedicated stroke unit (Class I, level of evidence B, based on a study of 86 hospitals in Sweden). However, there are no clear guidelines for ICP monitoring in spontaneous ICH due to lack of data on the incidence of increased ICP and its effect on the outcome in spontaneous ICH. In the case of progressive hydrocephalus, an external ventricular drainage (EVD) may be considered, especially in patients with a decline in consciousness. With an EVD in place, continuous ICP monitoring can be performed without the need for ICP electrode insertion, which can pose an additional risk of hemorrhage or infection. In all other cases of ICH, the decision whether to monitor and treat elevated ICP is unclear. Hence, the management principles are usually generalized from those for traumatic brain injury, in which current guidelines recommend placement of an ICP monitor in pa-

tients with a GCS score below 8 (presumed to be the result of hematoma mass effect) in those with clinical evidence of transtentorial herniation or extensive IVH or hydrocephalus, as mentioned earlier (24). The goal is to maintain the ICP values under 20 mmHg and central perfusion pressure (CPP) in the range of 50 to 70 mmHg (depending on the status of cerebral vessel autoregulation). In the case of ICP elevation, the treatment measures range from simple mechanical ones (head elevation and avoiding neck vein constriction) to early pharmacological (sedation, mannitol, or hypertonic solutions, and mild hyperventilation) and surgical interventions (EVD placement and decompressive craniectomy with hematoma evacuation). In addition, barbiturate coma and mild hypothermia may be considered (23, 24). The use of corticosteroids in increased ICP due to ICH has not been indicated because of drug inefficiency and increased risk of complications (25).

Minimally invasive methods of ICH evacuation are less traumatic compared to the standard craniectomy procedure. Studies have shown a better patient outcome in minimally invasive procedures. However, these surgeries may be technically more demanding and time consuming than standard craniotomy (26–28).

The MISTIE II study (*Minimally Invasive Surgery Plus Recombinant Tissue Plasminogen Activator in Intracerebral Hemorrhage Evacuation*) demonstrated that the insertion of a minimally invasive catheter into the area of bleeding and additional blood clot thrombolysis resulted in more efficient hematoma evacuation compared to the use of standard surgical approaches. In addition, it showed a higher survival rate and better functional outcome after 6 months of follow-up (28).

The third phase of this study (MISTIE III) was conducted on 506 patients and published in 2019 (29). It showed that in patients with moderate to large supratentorial hemorrhage there was no significant difference in functional outcome between the groups. However, the study did not consider differentiation based on locations of the ICH or between moderate and very large hemorrhages.

Infratentorial Hemorrhages

Posterior cranial fossa (PCF) hemorrhages are considered life-threatening when left to their natural course because they can lead to compli-

cations such as compression of the pons and medulla, acute hydrocephalus due to obstruction of the fourth ventricle, and herniation of the PCF contents. This can result in impaired consciousness, lower cranial nerve dysfunction, and, when severe, respiratory failure. Treatment includes suboccipital decompressive craniectomy, hematoma evacuation, EVD placement, and conservative treatment (30). A few non-randomized controlled trials have shown that surgical evacuation of infratentorial hematomas greater than 3 cm or with significant compression of the brain stem (obliteration of the fourth ventricle or prepontine cistern, hydrocephalus) may improve survival (23, 34–36). However, to date no large randomized controlled trials have been carried out to define an evidence-based protocol for acute PCF hemorrhage treatment (30). Several treatment algorithms have been suggested, considering the GCS score, presence of hydrocephalus, fourth ventricle compression, and hematoma size (30–33). Patients with a high GCS score (14 to 15) and small hematomas may initially be treated conservatively (15, 30). In the case of clinical deterioration, invasive measures should be reconsidered in line with the causes of deterioration. In comatose patients with medullary reflexes present, an urgent decompressive craniectomy and hematoma evacuation within 2 hours must be considered. However, EVD placement in the expansive processes of the PCF remains controversial due to potential ascending transtentorial herniation (30).

Intraventricular Hemorrhages

Intraventricular hemorrhages occur in up to 45% of all spontaneous ICH and are a poor prognostic sign, with a high expected morbidity and mortality (37). Primary IVH refers to bleeding from an intraventricular source and is uncommon, whereas secondary IVH occurs more frequently and refers to bleeding extending from the brain parenchyma or subarachnoid space into the ventricles (38). The presence of blood in the ventricles may result in obstructive hydrocephalus and increased ICP, which in the case of an associated decrease of consciousness ($GCS \leq 8$) and signs of transtentorial herniation require EVD placement. In an early phase, ICP management is often complicated by clot formation and obstruction of the catheter, which by itself does not promote clot resolution. Intraventricular administration of fibrinolytic

agents may accelerate the clearing of a ventricular blood clot and may have a favorable outcome according to several smaller trials. However, a systematic review of the literature demonstrated that additional research is warranted to clarify its effects on ventriculitis, long-term functional outcomes, and re-hemorrhage (39–41). The results of CLEAR-IVH (Clot Lysis Evaluation of Accelerated Resolution of Intraventricular Hemorrhage), published in 2012, revealed that the clearance of IVH depended on the dose of the thrombolytic agent and was more efficient in the central parts of the ventricles (42). The patients treated had lower ICP and less flow obstructions of the EVD catheter. The third phase (CLEAR-IVH III) of the trial showed that intraventricular thrombolysis in comparison to placebo increased the number of patients with a higher degree of disability (modified Rankin Scale (mRS) was 5 points) and made no contribution to a favorable functional outcome (mRS 0 to 3 points). However, the mortality rate was 10% lower (43). Although intraventricular administration of recombinant tissue plasminogen activator (rtPA) in IVH appears to have a sufficiently low complication rate, the efficacy and safety of this treatment are still uncertain (Class IIb; Level of Evidence B), and no clear recommendations exist so far (23).

There have been some encouraging results from trials with endoscopic surgery for IVH and ventriculostomy performed because fewer patients were in need of ventriculoperitoneal shunt insertion and one of the trials showed a better outcome after 2 months of follow-up (44). However, there are no clear recommendations in favor of this procedure so far (23).

Patients and Methods

We conducted a retrospective study and reviewed medical records of patients with nontraumatic spontaneous ICH treated at the Ljubljana University Medical Center from 2014 to 2018. The study included 251 patients, of whom 142 were male (57%) and 109 were female (43%). The overall mean age of the patients was 65 years after the exclusion of patients with traumatic brain injury or vascular malformations (consequently excluding most young adults).

As indications for surgical intervention, many factors were taken into account. We considered

the preoperative clinical condition of the patient and clinical deterioration, size of the ICH, ICH expansion, presence of IVH, location of hemorrhage, pre-morbid functional status, and rehabilitation potential of patients. In patients with extensive ICH, for whom the best treatment outcome was a vegetative state, surgical intervention was not indicated.

Results

The majority of patients (65%) suffered hemispheric ICH. Coinciding IVH occurred in one-third of the cases, 10% had a cerebellar hemorrhage, and 5% isolated IVH. A neurosurgical intervention was carried out in 104 patients, 95 interventions being a surgical hematoma evacuation via classical craniotomy and 14 interventions concomitant decompressive craniectomies. Hemispheric hematomas were thus treated surgically in 41% of patients. The majority of patients were treated within the first 24 hours after admission. The average age of surgically treated patients did not significantly differ from those that were treated conservatively. Furthermore, there were no significant differences in the male-to-female ratio. Cerebellar hematomas were treated surgically in 70%. The remaining patients were treated conservatively.

Within our group of patients, we observed that surgical evacuation of the ICH contributed to improved survival. The mortality rate in patients that were treated conservatively was 43%, versus 26% in those treated with surgical ICH evacuation. However, it must be taken into account that in the group of conservatively treated patients there were those with an anticipated poor surgical treatment outcome, and thus surgical intervention was not indicated. We also concluded that the average time of mechanical ventilation in surgically treated patients was significantly shorter (207 hours) in comparison to the conservatively treated patients on mechanical ventilation (266 hours), which indicated a faster recovery in patients treated with surgical intervention. The average length of hospital stay in the selected patients was 14.3 days.

Discussion

Surgical evacuation of ICH is indicated in patients with an acute onset of large lobar and cerebellar hemorrhage and associated progressive decrease in consciousness (15–17). The only efficient course of management of these patients is intensive care treatment in a specialized neurological intensive care unit and early hematoma evacuation with the goal of reducing the mass effect on the surrounding brain (14). After reviewing our data, we concluded that the following approach significantly increases survival of patients, facilitates recovery, and improves the probability of favorable functional outcome. One must be aware, on the other hand, that the treatment of extensive ICH with surgical evacuation is particularly complex and requires a well-coordinated collaboration between different medical specialties (i.e., neurologists, neurointensivists, neurosurgeons, and experts in neurorehabilitation). Finally, it offers favorable results only in selected patients, in whom the potential for improvement outweighs the potential risks of an invasive surgical procedure. This kind of treatment can only be carried out at specialized tertiary health centers that have adequate capacity and expertise for a complex multidisciplinary approach (i.e., hospitals that meet the requirements of the European Stroke Organisation (ESO) for an ESO Stroke Centre) (45).

Preferably, all patients with acute ICH that are potentially eligible for immediate and specific treatment should be transferred to a corresponding institution. To assist the decision about patient transfer, we have a consultation system available called Telestroke (Telekap) that offers rapid transfer of data from remote hospitals to centers specializing in strokes, ICH, and optimal treatment. Telestroke has been designed to provide patients with symptoms and signs of acute neurosurgical pathology a quick expert clinical evaluation, a review of diagnostic findings, a diagnosis, decision-making, emergency treatment recommendations, and postoperative advice.

In conclusion, ICH is still a disease with a poor outcome (46). However, in patients with extensive hemispheric or infratentorial hemorrhage, urgent surgical intervention is justified. In our series of patients treated with craniotomy, the outcome has been statistically significantly bet-

ter than the outcome in patients that were treated only with an EVD and/or ICP placement. Regardless of the statistics, we approach all patients individually, and decisions about their treatment are made in a multidisciplinary manner, in consideration of their associated diseases, possible coagulation disorders, neurological condition, and possible clinical outcome.

References

- Butcher K, Laidlaw J. Current intracerebral haemorrhage management. *J Clin Neurosci*. 2003;10:158–67.
- Hemphill JC 3rd, Farrant M, Neill TA Jr. Prospective validation of the ICH Score for 12-month functional outcome. *Neurology*. 2009;73(14):1088–94.
- Weimar C, Weber C, Wagner M, et al. Management patterns and health care use after intracerebral hemorrhage. A cost-of-illness study from a societal perspective in Germany. *Cerebrovasc Dis*. 2003;15:29–36.
- Bogousslavsky J, Van Melle G, Regli F. The Lausanne Stroke Registry: analysis of 1,000 consecutive patients with first stroke. *Stroke*. 1988;19(9):1083–92.
- Woo D, Sauerbeck LR, Kissela BM, et al. Genetic and environmental risk factors for intracerebral hemorrhage: preliminary results of a population-based study. *Stroke*. 2002;33(5):1190–5.
- Asdaghi N, Manawadu D, Butcher K. Therapeutic management of acute intracerebral haemorrhage. *Expert Opin Pharmacother*. 2007;8:3097–116.
- Ruiz-Sandoval JL, Cantú C, Barinagarrementeria F. Intracerebral hemorrhage in young people: analysis of risk factors, location, causes, and prognosis. *Stroke*. 1999;30(3):537–41.
- Kalita J, Goyal G, Kumar P, Misra UK. Intracerebral hemorrhage in young from a tertiary neurology center in North India. *J Neurol Sci*. 2014;336(1–2):42–7.
- Al-Khaled M, Eggers J. Prognosis of intracerebral hemorrhage after conservative treatment. *J Stroke Cerebrovasc Dis*. 2014;23(2):230–4.
- Steiner T, Kaste M, Forsting M, et al. Recommendations for the management of intracranial haemorrhage—part I: spontaneous intracerebral haemorrhage. *Cerebrovasc Dis*. 2006;22(4):294–316.
- Dowlatshahi D, Demchuk AM, Flaherty ML, Ali M, Lyden PL, Smith EE; VISTA Collaboration. Defining hematoma expansion in intracerebral hemorrhage: relationship with patient outcomes. *Neurology*. 2011;76:1238–44.
- Brott T, Broderick J, Kothari R, et al. Early hemorrhage growth in patients with intracerebral hemorrhage. *Stroke*. 1997;28:1–5.
- Cheung RTF, Zou LY. Use of the original, modified, or new intracerebral hemorrhage score to predict mortality and morbidity after intracerebral hemorrhage. *Stroke*. 2003;34(7):1717–22.
- Diringer MN, Edwards DF. Admission to a neurologic/neurosurgical intensive care unit is associated with reduced mortality rate after intracerebral hemorrhage. *Crit Care Med*. 2001;29:635–40.
- Kirollos RW, Tyagi AK, Ross SA, et al. Management of spontaneous cerebellar hematomas. *Neurosurgery*. 2001;49(6):1378–87.
- Mendelow A, Gregson B, Rowan E, et al. Early surgery versus initial conservative treatment in patients with spontaneous supratentorial intracerebral haematomas in the international Surgical Trial in Intracerebral Hemorrhage (STICH): a randomised trial. *Lancet*. 2005;365:387–97.
- Mendelow AD, Gregson BA, Rowan EN, et al. Early surgery versus initial conservative treatment in patients with spontaneous supratentorial lobar intracerebral haematomas (STICH II): a randomised trial. *Lancet*. 2013;382(9890):397–408.
- Heuts SG, Bruce SS, Zacharia BE, et al. Decompressive hemicraniectomy without clot evacuation in dominant-sided intracerebral hemorrhage with ICP crisis. *Neurosurg Focus*. 2013;34(5):E4.
- Fung C, Murek M, Z'Graggen WJ, et al. Decompressive hemicraniectomy in patients with supratentorial intracerebral hemorrhage. *Stroke*. 2012;43:3207–11.
- Takeuchi S, Wada K, Nagatani K, et al. Decompressive hemicraniectomy for spontaneous intracerebral hemorrhage. *Neurosurg Focus*. 2013;34(5):E5.
- Esquenazi Y, Savitz SI, El Khoury R, et al. Decompressive hemicraniectomy with or without clot evacuation for large spontaneous supratentorial intracerebral hemorrhages. *Clin Neurol Neurosurg*. 2015;128:117–22.
- Li Q, Yang CH, Xu JG, et al. Surgical treatment for large spontaneous basal ganglia hemorrhage: retrospective analysis of 253 cases. *Br J Neurosurg*. 2013;27(5):617–21.
- Hemphill JC, Greenberg SM, Anderson CS, et al. Guidelines for the management of spontaneous intracerebral hemorrhage: a guideline for health-care professionals from the American Heart Association / American Stroke Association. *Stroke*. 2015;46(7):2032–60.
- Bratton SL, Chestnut RM, Ghajar J, et al. Guidelines for the management of severe traumatic brain injury, VI: indications for intracranial pressure monitoring. *J Neurotrauma*. 2007;24(Suppl 1):S37–44.
- Poungvarin N, Bhoopat W, Viriyavejakul A, et al. Effects of dexamethasone in primary supratentorial intracerebral hemorrhage. *N Engl J Med*. 1987;316:1229–33.
- Zhou H, Zhang Y, Liu L, et al. Minimally invasive stereotactic puncture and thrombolysis therapy improves long-term outcome after acute intracerebral hemorrhage. *J Neurol*. 2011;258:661–9.
- Zhou X, Chen J, Li Q, et al. Minimally invasive surgery for spontaneous supratentorial intracerebral hemorrhage: a meta-analysis of randomized controlled trials. *Stroke*. 2012;43:2923–30.
- Hanley DF, Thompson RE, Muschelli J, et al. Safety and efficacy of minimally invasive surgery plus recombinant tissue plasminogen activator in intracerebral haemorrhage evacuation (MISTIE): a randomised, phase 2 trial. *Lancet Neurol*. 2016;15(12):1228–37.
- Hanley DF, Thompson RE, Rosenblum M, et al. Efficacy and safety of minimally invasive surgery with thrombolysis in intracerebral haemorrhage evacuation (MISTIE III): a randomised, controlled,

- open-label, blinded endpoint phase 3 trial. *Lancet*. 2019;393(10175):1021–32.
30. Witsch J, Neugebauer H, Zweckberger K, Jüttler E. Primary cerebellar haemorrhage: complications, treatment and outcome. *Clin Neurol Neurosurg*. 2013;115(7):863–9.
 31. Taneda M, Hayakawa T, Mogami H. Primary cerebellar hemorrhage. Quadrigeminal cistern obliteration on CT scans as a predictor of outcome. *J Neurosurg*. 1987;67:545–52.
 32. Kobayashi S, Sato A, Kageyama Y, et al. Treatment of hypertensive cerebellar hemorrhage—surgical or conservative management? *Neurosurgery*. 1994;34:246–50, discussion 250–41.
 33. Mathew P, Teasdale G, Bannan A, Oluoch-Olunya D. Neurosurgical management of cerebellar haematoma and infarct. *J Neurol Neurosurg Psychiatry*. 1995;59:287–92.
 34. Da Pian R, Bazzan A, Pasqualin A. Surgical versus medical treatment of spontaneous posterior fossa haematomas: a cooperative study on 205 cases. *Neurol Res*. 1984;6:145–51.
 35. Firsching R, Huber M, Frowein RA. Cerebellar haemorrhage: management and prognosis. *Neurosurg Rev*. 1991;14:191–4.
 36. Van Loon J, Van Calenbergh F, Goffin J, Plets C. Controversies in the management of spontaneous cerebellar haemorrhage: a consecutive series of 49 cases and review of the literature. *Acta Neurochir (Wien)*. 1993;122:187–93.
 37. Mustanoja S, Satopää J, Meretoja A, et al. Extent of secondary intraventricular hemorrhage is an independent predictor of outcomes in intracerebral hemorrhage: data from the Helsinki ICH study. *Int J Stroke*. 2015;10(4):576–81.
 38. Ojemann RG, Heros RC. Spontaneous brain hemorrhage. *Stroke*. 1983;14(4):468–75.
 39. Dunatov S, Antoncic I, Bralic M, Jurjevic A. Intraventricular thrombolysis with rt-PA in patients with intraventricular hemorrhage. *Acta Neurol Scand*. 2011;124:343–8.
 40. Huttner HB, Tognoni E, Bardutzky J, et al. Influence of intraventricular fibrinolytic therapy with rt-PA on the long-term outcome of treated patients with spontaneous basal ganglia hemorrhage: a case-control study. *Eur J Neurol*. 2008;15:342–9.
 41. Van Solinge TS, Muskens IS, Kavouridis VK, et al. Fibrinolytics and intraventricular hemorrhage: a systematic review and meta-analysis. *Neurocrit Care*. 2020;32:262–71.
 42. Webb AJS, Ullman NL, Mann S, et al. Resolution of intraventricular hemorrhage varies by ventricular region and dose of intraventricular thrombolytic: the Clot Lysis: Evaluating Accelerated Resolution of IVH (CLEAR IVH) program. *Stroke*. 2012;43(6):1666–8.
 43. Hanley DF, Lane K, McBee N, et al. Thrombolytic removal of intraventricular haemorrhage in treatment of severe stroke: results of the randomised, multicentre, multiregion, placebo-controlled CLEAR III trial. *Lancet*. 2017;389(10069):603–11.
 44. Zhang Z, Li X, Liu Y, et al. Application of neuroendoscopy in the treatment of intraventricular hemorrhage. *Cerebrovasc Dis*. 2007;24:91–6.
 45. Ringelstein EB, Chamorro A, Kaste M, et al. European Stroke Organisation recommendations to establish a stroke unit and stroke center. *Stroke*. 2013;44:828–40.
 46. Zahuranec DB, Lisabeth LD, Sánchez BN, et al. Intracerebral hemorrhage mortality is not changing despite declining incidence. *Neurology*. 2014;82(24):2180–6.
 47. Hwang BY, Appelboom G, Kellner CP, et al. Clinical grading scales in intracerebral hemorrhage. *Neurocrit Care*. 2010;13(1):141–51.

Microsurgical Replantation of Traumatic Total Scalp Avulsion: The First Reported Case in Slovenia

Luka Emeršič¹, Matevž Hlačer²

¹ Department of General and Abdominal Surgery, Jesenice General Hospital

² Department of Plastic and Reconstructive Surgery, Maribor University Medical Center

CORRESPONDENCE

Luka Emeršič, MD
lukaemersic10@gmail.com

KEY WORDS

amputation, scalp avulsion, scalp replantation, microsurgery

CASE REPORT

SURGERY SURG ENDOS 2020; 2(2):
31-37

Abstract

Total scalp avulsion is a rare but serious, even life-threatening, injury often resulting in defects of the hair-bearing skin. Microsurgical replantation is considered the first choice of treatment in scalp avulsions. Avulsion usually incorporates the entire scalp and forehead. Before microsurgical replantation, cranial and spinal injuries must always be excluded. Ischemia time of the avulsed scalp is important for replantation to be successful and should be as short as possible. When performing scalp replantation, one arterial anastomosis is sufficient for replant survival. Avoiding venous congestion is crucial, and there should be as many venous anastomoses as possible. Nevertheless, just one venous anastomosis may also be enough, and pending venous congestion can be treated with in situ heparin injections. If the vessels are too damaged, vein grafts may be used. There are new methods developing that will better predict replant survival, especially in scalp avulsions with prolonged ischemic time. Our case report shows the first successful scalp replantation in our country.

Introduction

Total scalp avulsion is quite rare (only 2% of all amputations), but it is a serious injury (1-5). The most common mechanism is entanglement of factory workers' long hair in a high-speed rotary machine (1, 3, 5, 6). Due to shearing forces, avulsion usually happens at the loose areolar tissue layer between the galea aponeurotica and the periosteum (7, 8). The situation can be life-threatening due to possible intracranial injuries, cervical spine injuries, and hemorrhagic shock (1, 4). Since 1976, when Miller et al. successfully carried out the first scalp replantation (1-6, 8, 9, 11, 12), microsurgical replantation has been considered the first choice of treatment in scalp avulsion (1, 11). Prior to 1976, these kinds of injuries were treated with secondary reconstruction, which had poor aesthetic results (8).

The only contraindication for replantation of an avulsed scalp in its anatomical site is associated life-threatening injury. In such cases, temporary ectopic implantation is necessary (3).

This article presents the first case of total scalp avulsion injury at our hospital, the Maribor University Medical Center, and also the first reported such case in Slovenia.

Case Report

A 28-year-old woman was brought to the emergency department via ambulance after a robotic arm in a factory caught her hair, resulting in avulsion of the entire hairy scalp, forehead, part of the right ear, right eyelid, and bilateral eyebrows (Figure 1a). There was no loss of consciousness. The avulsed scalp was stored properly in cold conditions and brought with her. On the site she was given opioids and antiemetics. The examination ruled out associated life-threatening cervical and intracranial injuries. It showed only a small wound on her left shoulder, without bleeding. Before she was brought to the operating room through the department of plastic surgery for replantation under general anesthesia, a computed tomography angiography of the head was taken.

First, we prepared the avulsed scalp. It was placed on the underside, carefully shaved, thoroughly irrigated, and debrided (Figure 1b). Superficial temporal arteries on both sides were identified and prepared. No veins were seen because of ischemia. During revision we found laceration of her right ear with damage to the cartilage (Figure 1d), and compression damage of the avulsed scalp in the left occipital part and of the right supraorbital part in the right eyebrow region of the avulsed scalp that was partially torn away.

Then we prepared the recipient site of the patient's head (Figure 1c). We made a debridement and revision. We identified the superficial temporal artery (STA) on the right side and we made two microsurgical anastomoses with two branches of the STA. The scalp appeared well perfused. Intraoperatively we observed thrombosis of one arterial anastomosis and dehiscence of the other. We made a reanastomosis at the dehiscence site on the right side. On the left side we identified the superficial temporal vein (STV) and made an anastomosis. Perfusion was established and the

total cold ischemia time was only 8 hours. The patient received five units of blood transfusion during surgery and was postoperatively transferred to the intensive care unit intubated and under sedation.

The dressing was changed daily. To avoid thrombosis of the venous anastomosis, subcutaneous heparin injections around the anastomosis were performed. Necrosis of the right supraorbital part and left temporooccipital part of the replanted skin developed (Figure 2a) due to compression injury, and possibly also due to venous congestion from the compression or venous stasis. On the 16th postoperative day we had to do a debridement of devitalized tissue (Figure 2b). The supraorbital defect on the right side was covered with a full-thickness skin graft, which we took from a medial side of the right upper arm; the donor site was closed directly as in brachioplasty. The temporooccipital defect was covered with a split-thickness skin graft (Figure 2c). All of the defects healed after skin transplantation and there were no further problems with the replanted scalp. Thirty-five days after the accident, the entire remaining scalp was viable, and hair gradually developed. The patient was satisfied with the eventual outcome and was discharged from the hospital.

During outpatient visits we additionally made an excision and Z-plastic of the scar in the medial part of the right upper eyelid. Otherwise the patient did not seem to have any problems. One year after the accident anterior, lateral and posterior views revealed that the scalp had survived well (Figures 3a–c). The patient was offered transplantation of hair follicles in the left occipital part and transplantation of part of the left eyebrow to the right side, but she declined this. At the last outpatient visit, 5 years after the accident, we could still see mild ptosis on her right side and an abundance of hair on the replanted scalp (Figure 3d).

Discussion

Total scalp avulsion is an infrequent but disfiguring injury, mostly the result of high-speed rotating machinery coming in contact with the patient's hair (1–3, 5, 6, 10, 12). Avulsion usually takes place between the galea aponeurotica and the periosteum (7, 8) and incorporates the entire

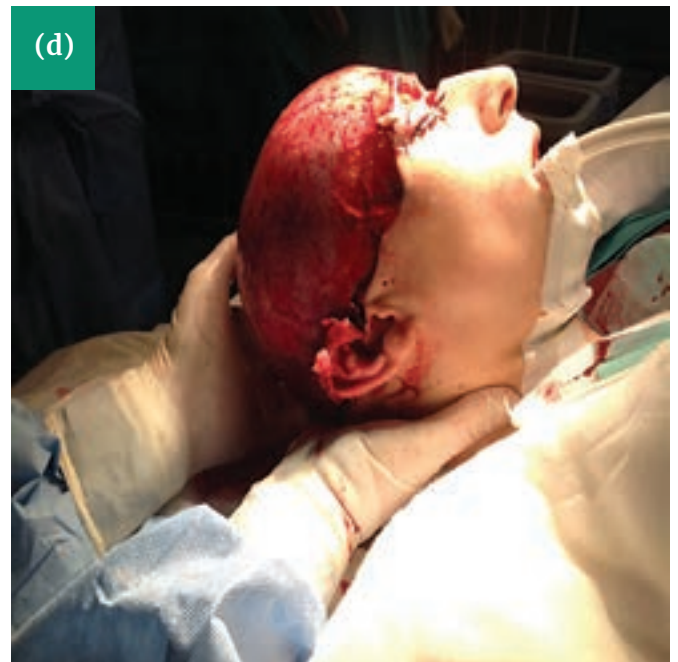
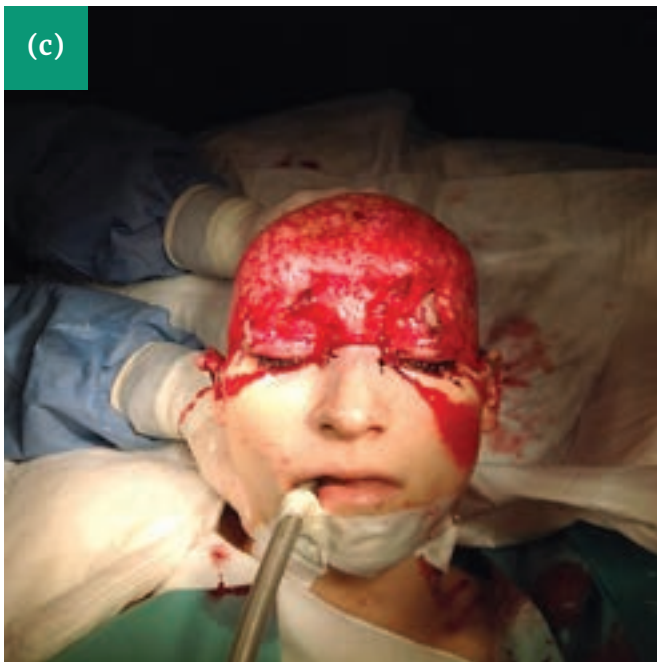
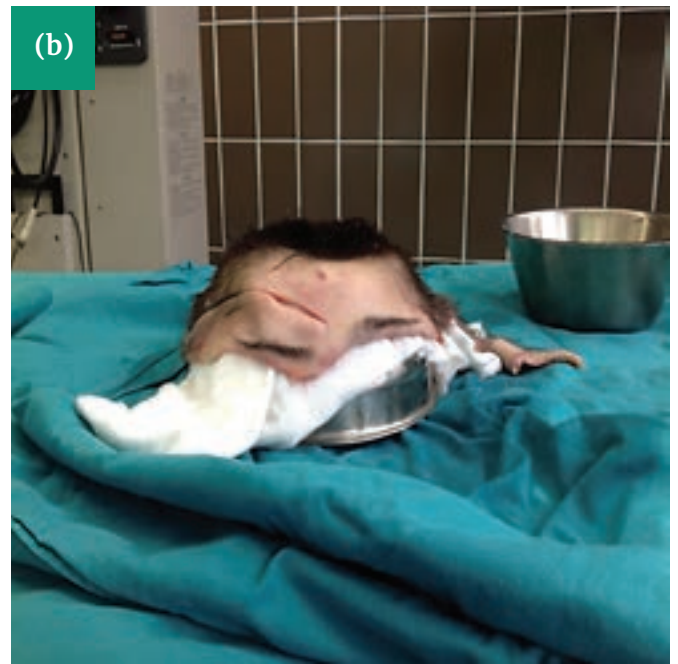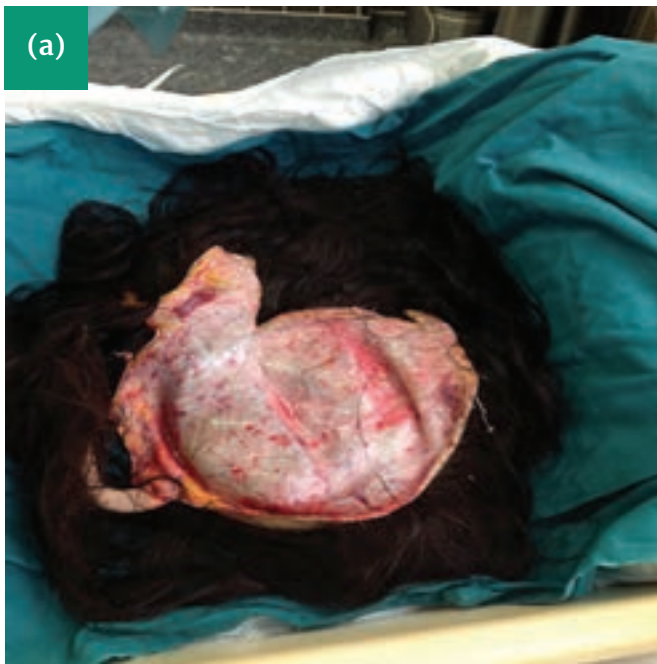Figure 1. (a) The scalp that was brought to the emergency department. The total scalp was avulsed, including the right part of the ear, right eyelid, and both eyebrows. (b) Shaving of the long hair and irrigating the scalp. (c) Preparing the recipient site. (d) Laceration of the patient's right ear with damage to the cartilage.

scalp and forehead (1–3, 6, 7, 9, 10). In most cases it also includes one or both eyelids, one or both eyebrows, and part of the left or right ear (1, 3, 6, 7, 9), as was also seen in our case. Before definite treatment, intracranial and cervical spine injuries must be excluded and development of hemorrhagic shock prevented (1, 3). Xu et al. carried

out temporary ectopic implantation of an avulsed scalp due to a patient's spinal injury because it is a contraindication for replantation of the scalp at its anatomical site (3). Replantation is the best possible form of treatment following total scalp avulsions (13) and should still proceed even if the avulsed scalp is crushed (9). Despite 60 to 70 suc-

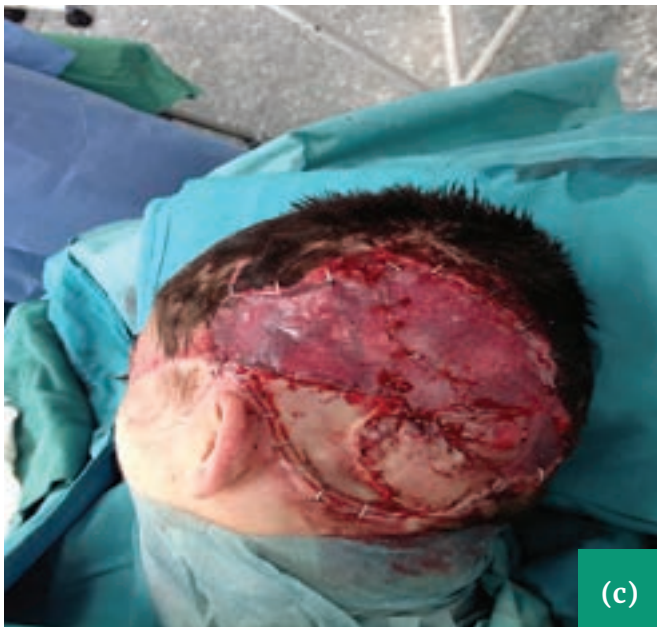
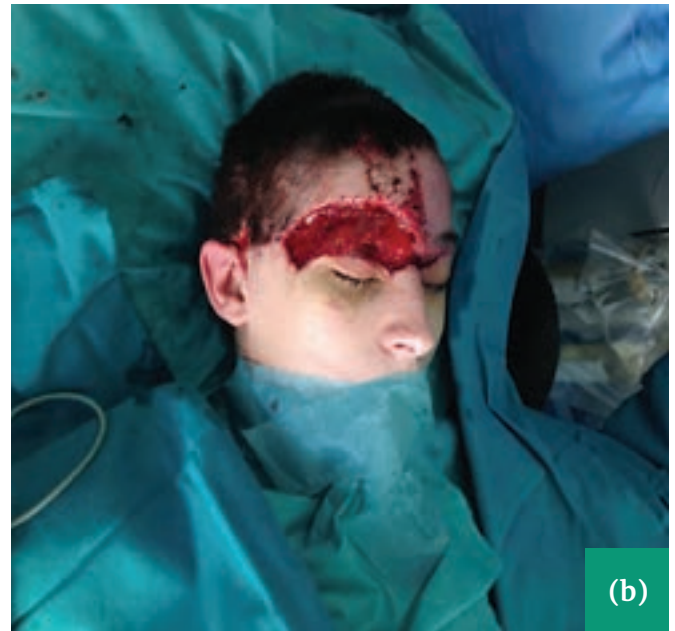
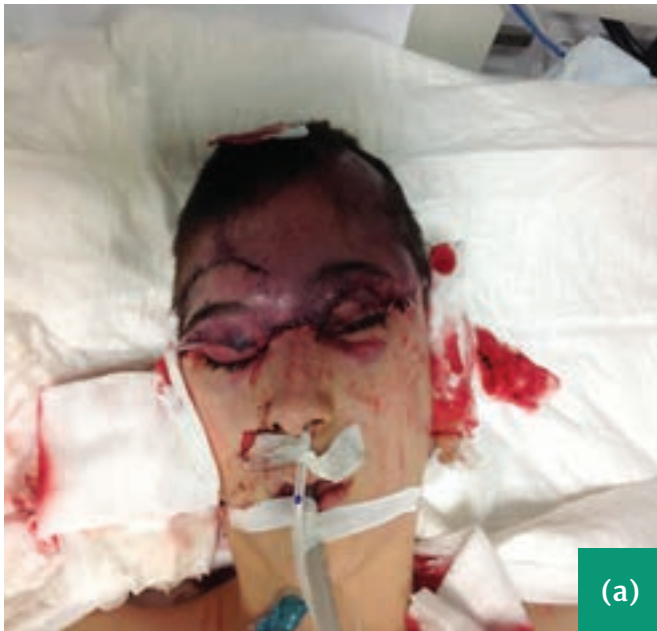Figure 2. (a) Replanted scalp with venous congestion. (b) Debridement of the right supraorbital part because of necrosis. (c) Split-thickness skin graft in the temporooccipital region because of necrosis.

successful scalp replantation cases published in the world (9), this case was our first at our department and also first in our country.

When encountering scalp avulsion injuries, one must always take into consideration ischemia time of the avulsed or amputated part (7). According to some literature, ischemia time of 5 to 6 hours is

the maximum sustainable time before the chances of success are drastically reduced (7); however, others have demonstrated that a scalp can withstand 17 hours of warm ischemia and 22 hours of cold ischemia (6). Huang et al. showed that scalp replantation can also be successful after 35 hours of warm ischemia time, which is the longest ever reported in the literature (10). There are no studies



Figure 3. (a) One year after microsurgery, good form and function of almost all hair-bearing scalp, right ear, right eyelid, and forehead. Only mild ptosis on her right side is seen due to eyelid laceration. (b) Almost 1 year after placing a split-thickness skin graft in the temporooccipital defect, we can see a good aesthetic result. (c) Reconstructed right ear 1 year after the accident. (d) Five years after the accident. Remaining mild ptosis on her right side and abundance of hair on the replanted scalp.

in the literature describing the precise length of ischemia in which replantation would be successful (6). In our case, 8 hours of cold ischemia passed from the accident until the scalp was successfully replanted without major problems.

Once the avulsed scalp is shaved, thoroughly washed, and cleaned (1, 6, 13), preparation and

identification of the vessels for the anastomosis begins (6, 13). The major blood supply of the scalp comes from a superficial temporal artery (4) and posterior auricular arteries (12, 14). There is still no agreement on the optimal number of arteries or veins that should be anastomosed for replantation to be successful (2, 11). Most authors say that the best surgical results are achieved with a

greater number of sutured arteries and veins (9, 12), especially if scalps are multifragmented or severely torn (4, 13). However, Sabapathy et al. advised that two arterial and two venous anastomoses are sufficient (2, 13). On the other hand, Nahai in 1978 and Demir in 2019 successfully replanted a total avulsed scalp with only one artery and one vein (4, 9).

In our case, we used one artery and one vein; specifically, the STA and STV. We had a problem with venous congestion, which is one of the most common causes of replantation failure (2, 6). Jiang et al. suggested that at least two veins had to be anastomosed in order to prevent congestion (2). Herrera et al. reported that the greatest effect on scalp survival is the venous outflow and that the use of single or multiple arterial anastomoses, because of their good network of collaterals between major vessels (9), has little effect (8). Kaplan et al. stated that at least four to nine veins should be anastomosed for better venous drainage (4, 9). However, Demir et al. showed that if a vein with a large diameter is used—in their case, the retromandibular vein—that one vein is enough for successful replantation (2). Most commonly congestion and later necrosis appears in the occipital area (6), as also occurred in our case. Some say the problem is in the small diameter of the occipital vessels, and consequently difficulty in finding and using them in the anastomosis (6). Others claim that the occipital area is most likely to be devoid of usable vessels because of the crush injuries that are usually located there (6).

The anastomosis can also be performed using a vein graft (2, 4). Many authors agree that vein grafts are necessary for better mobilization of venous anastomosis within the zone of injury or if there is multifragmented scalp avulsion with torn vessels (6, 8, 11). Others insist on using them to allow strict debridement (4). Sabapathy et al. stated that adequate mobilization is urgent to provide tension-free anastomosis, in which using a vein grafts should be a rule in scalp avulsion (13). If no viable vessels are available, arterial-venous anastomosis can also be performed (6).

As stated previously, venous congestion is the primary reason for scalp replantation failure (2, 6). In our case, because we only made one arterial and venous anastomosis, we tried to prevent this with subcutaneous injections of heparin at the site of venous anastomosis. Yin et al. suggest using medical or chemical leeches to reduce congestion

(12, 15). In their study of digit amputations, Han et al. discovered that use of topical heparin with a combination of systemic anticoagulation prevented venous congestion of the replanted digits without any major bleeding problems (15). Hudson et al. used an in situ venous catheter in an attempt to deliver high doses of heparin to prevent thrombosis and venous congestion while maintaining low systemic levels of heparin. It showed zero re-explorations or flap failures in comparison to 12% re-explorations without heparin usage (16).

Despite not finding any information in the literature about the use of in situ heparin injections for preventing venous congestion in scalp replantations, our case report shows it can be beneficial.

To predict replant survival, Huang et al. intravenously injected indocyanine green (ICG) during the procedure and used ICG angiography to visualize soft-tissue vascularity and perfusion (10). Their study showed that ICG angiography mapping is more sensitive for detecting tissue perfusion and provides more accurate prediction of replant survival in comparison to conventional clinical assessment (10). This method is very simple and reproducible, but it remains rather seldomly used.

In our case, no nerve anastomosis was performed. Kim et al. recommend against nerve repair with nerve anastomosis in some cases in order to reduce the operation time (7). There is reasonable sensory and motor recovery of the scalp and frontalis muscle even without nerve repair reported (7, 11). At every follow-up we observed better sensory and motor function in our patient. Only mild ptosis on her right side due to eyelid laceration was seen, with which the patient had no problems.

Conclusion

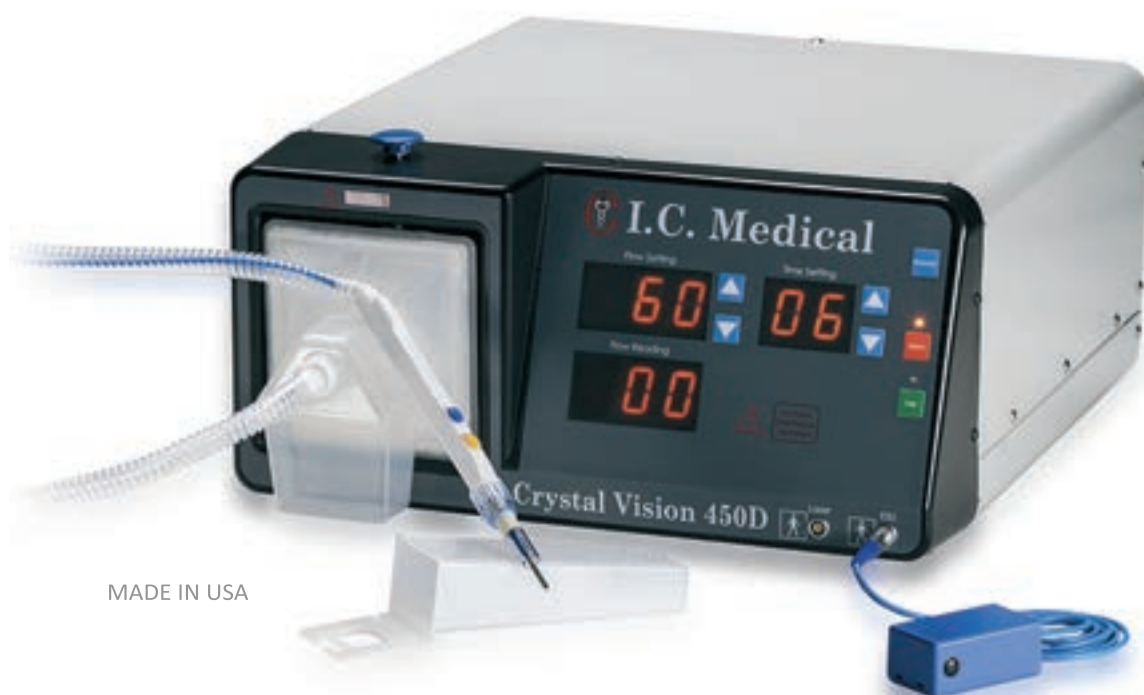This is the first case report of scalp replantation in our country. Microsurgical replantation is the first choice of treatment in scalp avulsions, even if the time of warm ischemia exceeds 5 to 6 hours. One artery is adequate for perfusion of the entire scalp, and one venous anastomosis may be enough, but it is better to have as many as possible to reduce venous congestion, which leads to scalp necrosis. If venous congestion becomes a problem, in situ heparin injections or medical leeches may be used. Reasonable sensory and motor recovery can be obtained without nerve repair. The development of new diagnostic techniques, such as ICG angiography, could help in predicting replant survival. A literature review shows that there is no standard protocol for scalp replantation. From our case report and other literature, we can conclude that the best success is achieved by following microsurgery protocols.

References

1. Jiang Z, Li S, Cao W. Emergency management of traumatic total scalp avulsion with surgical replantation. *Ulus Travma Acil Cerr Derg.* 2014;20(1):66–70.
2. Demir CI, Yasar EK, Davun KE, et al. Successful total scalp replantation using the retromandibular vein as a recipient vessel. *Turk J Plast Surg.* 2020;28:74–6.
3. Xu H, Zhang Y, He J, et al. Ectopic implantation of an avulsed scalp with tissue expander on a forearm for combined total scalp avulsion and spine injuries: a case report. *Microsurgery.* 2016;37(7):819–23.
4. Kim EK, Kim SC. Total scalp replantation salvaged by changing the recipient vein. *J Craniofac Surg.* 2012;23:1428–9.
5. Zhang YM, Li JM, Jiang X. Successful salvage in a scalp avulsion through unilateral microvascular anastomosis. *Chin Med J.* 2013;126(7):1386–7.
6. Plant MA, Fialkov J. Total scalp avulsion with microvascular reanastomosis: a case report and literature review. *Can J Plast Surg.* 2010;18(3):112–5.
7. Kim JT, Kim YH, Yang EZ, Kim JB. Total scalp replantation—salvage following prolonged ischaemia with poor prognostic factors. *J Plast Recon Aesth Surg.* 2010;63:1917–20.
8. Herrera F, Buntic R, Brooks D, et al. Microvascular approach to scalp replantation and reconstruction: a thirty-six-year experience. 2012;32(8):591–7.
9. Nguyen HH. The microsurgical replantation of seven complete scalp avulsions: is one artery sufficient? *J Plast Recon Aesth Surg.* 2012;65:1639–44.
10. Huang X, Wang Z, Liu C, et al. A case of scalp avulsion with prolonged ischemic time: indocyanine green angiography can aid in predicting replant survival. *Burns Trauma.* 2019;36(7):2–5.
11. Hu W, Henry AS, Lucas C, et al. Microsurgical replantation of a two-segment total scalp avulsion. *J Craniofac Surg.* 2016;27:1068–9.
12. Yin JW, Matsuo JMS, Hsieh CH, et al. Replantation of total avulsed scalp with microsurgery: experience of eight cases and literature review. *J Trauma.* 2008;64:796–802.
13. Sabapathy SR, Venkatramani H, Bharathi RR, D’Silva J. Technical considerations in replantation of total scalp avulsions. *J Plast Recon Aesth Surg.* 2006;59:2–10.
14. Toure G, Meningaud JP, Vacher C. Arterial vascularization of occipital scalp: mapping of vascular cutaneous territories and surgical applications. *Surg Radiol Anat.* 2010;32:739–43.
15. Han SK, Lee BI, Kim WK. Topical and systemic anticoagulation in the treatment of absent or compromised venous outflow in replanted fingertips. *J Hand Surg.* 2000;25(4):659–67.
16. Askari M, Fisher C, Weniger FG, et al. Anticoagulation therapy in microsurgery: a review. *J Hand Surg.* 2006;31(5):836–46.

Crystal Vision 450D

Najbolj napreden prenosni sistem odstranjevanja kirurškega dima pri odprtih in laparoskopskih posegih



MADE IN USA

- Hidrofobni ULPA filter odstrani do 100% kirurškega dima
- Avtomatsko delovanje pri odprtih in laparoskopskih posegih – konstantno merjenje pritiska v trebuhu
- Elektronska kontrola učinkovitosti filtracije – vizualni in zvočni opozorilnik
- Avtomatska prepoznavna vira energije – monopolarna, bipolarna, laser, ultrazvočni skalpel ...
- Moderen brezkrtačni motor poganja črpalko za takojšnji vlek brez zamika

Single-Port Laparoscopic Resection of Intraductal Papillary Neoplasm of the Bile Duct with an Associated Invasive Carcinoma: A Case Report and Literature Review

Gašper Horvat,¹ Rada Đokić,² Mihajlo Đokić¹

¹ Department of Abdominal Surgery, Ljubljana University Medical Center

² Department of Gastroenterology, Celje General Hospital

CORRESPONDENCE

Gašper Horvat, MD
gasper.horvat@kclj.si

KEY WORDS

intraductal papillary neoplasm of the bile duct, IPNB, bile duct tumor, bile duct carcinoma, single-port, laparoscopic resection, sectionectomy, liver resection

CASE REPORT

SURGERY SURG ENDOS 2020; 2(2): 39-44

Abstract

Intraductal papillary neoplasm of the bile duct (IPNB) is a rare type of bile duct tumor that arises both intra- and extrahepatically. It is considered a biliary equivalent of the intraductal papillary mucinous neoplasm of the pancreas. IPNB as a distinct pathological entity was first described in 2001; since 2010, it has been included in the WHO classification of gastrointestinal tumors. At its introduction, IPNB was considered to be a precancerous dysplasia that only spreads superficially through the biliary epithelium. However, it was established that malignant transformation into in situ or invasive carcinoma is common. The exact etiology of the disease still remains to be determined. Infection with Chinese liver fluke (*Clonorchis sinensis*) and hepatitis have been mentioned as possible risk factors that contribute to development of the tumor, or hepatolithiasis. The most common symptoms are transient abdominal pain, obstructive jaundice, and cholangitis; around 30% of the cases are detected incidentally because patients exhibit no symptoms. Computed tomography, magnetic resonance imaging, and liver ultrasound are the most frequently used imaging modalities that secure the diagnosis. The most frequent finding is an intraductal mass combined with cystic bile duct dilatation. All patients are considered eligible for surgical treatment, with hepatectomy followed by bile duct resection being the operations most commonly performed. The authors describe a case report of a patient treated for a potentially malignant biliary duct cyst at the Department of Abdominal Surgery, Ljubljana University Medical Center, who underwent a laparoscopic single-port left sectionectomy. The pathological findings showed an IPNB with high-grade dysplasia and several focal points of invasive adenocarcinoma; R0 resection was achieved. Analysis of the currently available literature showed that laparoscopic

resection of IPNB tumors is extremely rare, and that single-port laparoscopic resection has so far never been reported.

Introduction

Intraductal papillary neoplasm of the bile duct (IPNB) is a rare form of epithelial bile duct tumor whose main characteristic is a distinct papillary or villous growth into the intra- or extrahepatic lumen of bile ducts (1). One-third of patients are also affected by mucin hypersecretion or a cystic dilation of the affected bile ducts. The concept of IPNB as a common name for a broad spectrum of epithelial bile duct tumors was first suggested by Taiwanese pathologists in 2001, and it was included in the WHO classification of gastrointestinal tumors in 2010 (2). The new classification combined biliary papillomatosis (also called papilloma), some forms of intraductal cholangiocarcinoma, papillary carcinoma of the extrahepatic bile duct, and some forms of biliary cistadenoma or cystadenocarcinoma under the joint IPNB entity (1).

Because of the way it grows and its histopathological characteristics, IPNB is considered equivalent to an intraductal papillary mucin-producing neoplasm of the pancreas (IPMN). [2] Further research showed that IPNB is more commonly associated with invasive carcinoma than IPMN of the pancreas and that the tumors differ somewhat with regard to oncogenesis (3).

Even though IPNB was initially mostly considered to be precancerous dysplasia whose spread across the biliary system was supposedly superficial and did not exhibit invasiveness (2), subsequent meta-analyses showed that in 43% of cases the tumor was histopathologically proven to be an invasive carcinoma, in 20% an in situ carcinoma, and in 28% a benign disease. Despite this, most (63%) tumors studied were limited to bile duct walls; transmural invasion was described in 28% of cases, and lymphatic invasion in 9% (3). Metastasized IPNB is extremely rare and has been described in only a small number of case reports.

According to the WHO classification of gastrointestinal tumors, IPNBs are divided into three categories according to the varying degrees of biliary epithelial cell dysplasia: IPNB associated with low- or intermediate-grade intraepithelial dys-

plasia, IPNB associated with high-grade intraepithelial dysplasia, and IPNB associated with an invasive carcinoma (5). The most frequent of the three are those associated with high-grade intraepithelial dysplasia and those associated with an invasive carcinoma. With regard to the dominant type of the epithelium of the intraductal part of the tumor, IPNBs can be divided into four subtypes: pancreatobiliary, intestinal, gastric, and oncocytic. The most common is the pancreatobiliary type, which is also most frequently associated with high-grade intraepithelial dysplasia or an invasive carcinoma. Microscopically, the invasive form is usually either a tubular adenocarcinoma or a mucinous carcinoma (1).

The tumor is most common between the ages of 50 and 70, is slightly more likely to appear in men, and has the highest incidence rate in the countries of the Far East, which is often ascribed to endemic hepatolithiasis and Chinese liver fluke infection (1). Some research has suggested hepatolithiasis, reportedly present in as many as 64 to 100% of patients with histologically proven IPNB, as an important factor in IPNB development. [6] Some studies have also indicated the presence of viral hepatitis at the time of IPNB diagnosis in 2.8 to 24% of patients (3).

Intraductal papillary neoplasm of the bile duct represents approximately 10% of the carcinomas affecting the hilar part of the bile duct and 15% of intrahepatic cholangiocarcinomas (7). Meta-analysis has shown that the tumors are equally likely to appear in intra- or extrahepatic bile ducts. In as many as 74.4% of cases, the intrahepatic tumors affected the left lobe of the liver. The tumor often (in 41% of patients) appears as multicentric (3).

The clinical picture is most often exhibited in the form of prior abdominal pain (42% of patients) and obstructive jaundice (33%) (3). Some patients may develop acute cholangitis. In 5 to 30% of patients, the disease has no clinical signs or symptoms (1, 3). Liver function was mostly retained, although there are some studies that contradict this; in those, alkaline phosphatase was most often elevated. Studies have also dealt with the importance of elevated carcinoembryonic antigen (CEA) and carbohydrate antigen 19-9 (CA 19-9) tumor markers as potential tests to assist diagnosis, but their values varied strongly. It was concluded that the markers are not specific and sensitive enough to be appropriate for use during

IPNB diagnostics. There are also no studies analyzing the usefulness of these markers for evaluating the malignant potential of the tumor or the disease prognosis as of yet (3).

The most common radiological findings are bile duct dilatation (which may present as diffuse, localized, or cystic) and intraductal mass discovery (1). It is possible to see the dilatation or intraductal masses using computed tomography or magnetic resonance imaging and ultrasound examinations of the liver. Endoscopic retrograde cholangiography can prove the presence of mucobilia, present in up to a third of IPNB patients, but the very presence of mucobilia makes the test less appropriate for visualizing the tumor itself (3). Percutaneous transhepatic cholangioscopy or peroral cholangioscopy can also help with the diagnosis because they allow for extracting a biopsy sample and evaluating the superficial spread of the tumor in the biliary system.

All IPNB patients are eligible for operative treatment because even the benign forms of tumor may lead to recurrent cholangitis (in 14% of patients) and obstructive jaundice (in 33%) (3). Due to the poor sensitivity of an endoscopic biopsy that might preoperatively determine the histopathology and invasiveness of the tumor, early surgical resection is indicated in all patients with a clinical picture, and especially in those with diagnostic imaging that shows signs of IPNB, because what has been observed about the biology of IPNB tumors so far leads us to expect that most tumors discovered will eventually progress from earlier benign forms to being invasive. Early and radical surgical resection is thus the key to successfully treating IPNB-suspicious lesions without proven distant metastases (3). Due to the relative rarity of the tumor and its very recent recognition as an independent histopathological form, no major studies have been performed to clearly define treatment guidelines. Doctors usually decide on a treatment plan on the basis of individual case reports, smaller studies, or their experience with other forms of intra- or extrahepatic cholangiocarcinoma. Extensive hepatectomy (with or without extrahepatic bile duct resection) or pancreaticoduodenectomy are usually considered as options. If the preoperative diagnostics are favorable, a less extensive liver resection may be performed (1).

Studies have shown strong variations in patients' prognoses that are dependent on many different

factors, with MUC1 antigen expression, a positive surgical resection margin, lymphovascular invasion, and multifocal tumors all being considered negative prognostic factors (3, 4). A meta-analysis performed in 2016 estimated the absolute 1-year survival rate of all IPNB patients after resection at 96% (95% CI: 93–99%), the 3-year survival rate at 79% (95% CI: 69–88%), and the 5-year survival rate at 65% (95% CI: 46–76%). The authors, however, did draw attention to the poorer value of the 1-, 3- and 5-year survival rate findings because their analyses were based on different ways of defining life expectancy and there were large differences in the values defined (3). In 2019, German authors performed their own meta-analysis, which was predominantly based on more recent retrospective studies that explicitly dealt with patient survival after the surgical resection of IPNB. The data acquired estimate the 3-year survival rate at 64 to 90% and the 5-year survival rate at 38 to 84%. The median life expectancy is 55 to 102 months for benign IPNB and 33 to 52 months for malignant IPNB (4).

Case Report

We present the case of a 71-year-old patient with arterial hypertension that was admitted to the Department of Abdominal Surgery, Ljubljana University Medical Center, in April 2019 for scheduled surgical removal of a cystic liver lesion. The patient had surgery in 2016 for a stage T3N0M0 rectosigmoid adenocarcinoma. A laparoscopically assisted rectosigmoid resection was performed. She received adjuvant chemotherapy after the surgery. A control computed tomography scan as a part of regular follow-ups revealed a hypodense cystic lesion measuring 3.9 × 3.2 cm with wall thickening at the border between the second and third liver segments. The change was also visible on a previous control ultrasound result. The computed tomography scan indicated a regular biliary cyst. Due to the patient's history of cyst growth, radiologists suggested a contrast-enhanced ultrasound of the liver to determine the nature of the lesion. Based on the diagnostic imaging performed, which indicated a macroscopic solid inclusion in the cystic lesion of the liver and exhibited at least partial vascularization, it was suspected that this was a liver lesion of malignant etiology. Hospital records were

presented at a hepatobiliary medical council in March 2019, where surgical removal of the lesion was indicated.

As a part of the preoperative examinations, the patient underwent antigen testing for an echinococcus infection, which refuted the suspicion of echinococcosis.

A single-port laparoscopic left lateral sectionectomy was performed in April 2019. An ultrasound of the cystic lesion was also performed intraoperatively and confirmed the suspicion of a cystadenoma. The sample was then sent for histopathological examination.

After the surgery, the patient initially recovered at the intensive care unit and was later moved to a regular ward, where her recovery proceeded according to expectations and with no complications. She was discharged on the 3rd postoperative day.

The histopathological results of the sample showed that the patient suffered from high-grade intraductal papillary neoplasm of the bile duct with individual focal points of early invasive adenocarcinoma. The liver parenchyma sample showed a round, sharp-edged, and encapsulated cystic lesion that was partially hemorrhagic. At its largest, the tumor measured 38 × 27 × 30 mm. The lesion was situated at least 4 mm from the resection margin. There was no invasion into the surrounding liver parenchyma and no lymphovascular invasion. The tumor stage was defined as pT1N0M0 with a negative resection margin (R0). Periductal fibrosis in the surrounding liver parenchyma indicated that the patient had had cholangitis in the past.

A multidisciplinary hepatobiliary medical council advised follow-up appointments with the surgeon.

Discussion

IPNB is a very rare tumor of the bile duct epithelium that studies have focused on only in the last 20 years. Because of the rarity of the tumor, there has not yet been enough research performed on a sufficient number of patients to definitively clarify the carcinogenesis risk factors for the development of the tumor, a typical clinical picture, and an optimal treatment plan. Any knowl-

edge about the tumor is predominantly based on rare reports and smaller, often retrospective studies (8).

Unlike most published cases, in which most patients displayed abdominal pain or jaundice, we discovered the tumor using diagnostic imaging that was part of a regular follow-up after rectosigmoid adenocarcinoma resection. The solid-inclusion cystic lesion that was discovered in the patient using computed tomography and a contrast-enhanced ultrasound appears in the literature as the most common radiological finding in patients with IPNB (present in 40 to 100% of patients) (3, 8). Contrast-enhanced ultrasound confirming the existence of solid inclusions with at least partial vascularization and thus also definitively confirming the suspicion of a malignant cystic liver lesion is a less often used method of diagnostic imaging outside Slovenia (used in only 10% of cases) (3). There, a computed tomography scan (performed in 63% of cases that were part of the meta-analysis) is most often used to diagnose the tumor. It is very often combined with an endoscopic retrograde cholangiopancreatography (in 62% of cases), despite being a less suitable diagnostic test because the presence of mucobilia in about a third of patients prevents the test from being carried out properly (1). A magnetic resonance imaging scan is apparently more suitable for determining the invasiveness of a tumor than a computed tomography scan. About 40% of patients underwent one as a part of the diagnostic imaging of the lesion. What is interesting is the relatively rare use of ultrasound in diagnosing suspicious changes, despite it having been shown to be equivalent to a magnetic resonance imaging or a computed tomography scan in identifying pathological lesions of the liver (3, 8).

Several studies have suggested hepatolithiasis and the associated inflammation to be an important risk factor for developing IPNB (1, 3, 6). Evidence of hepatolithiasis-related inflammatory events was present in the patient described here because the pathohistological tests showed that she had most likely had cholangitis in the past.

The basic guideline for choosing the most appropriate type of surgery is the location of the tumor. It is equally likely to appear intra- and extrahepatically. The purpose of the surgery is to achieve complete surgical resection (R0). A negative surgical resection margin and a histopathologically

benign tumor are the most relevant independent factors that positively influence patient survival (4, 9). The 5-year survival rate of patients with a positive resection margin is 25%, in contrast to the 75% of those patients in whose cases an R0 resection was achieved (9). This type of resection is successfully performed in 90% of patients (3). The histological subtype and the location of the tumor, as well as the age and sex of the patient, have proven not to be factors determining life expectancy. An invasive type of IPNB, a lymphovascular invasion of the tumor, a positive surgical margin (R1), and a MUC1 expression have been shown to negatively influence patient survival (4).

Hepatectomy is a surgery of choice; it was performed in 69% of patients covered in the 2016 meta-analysis and is usually combined with bile duct resection (hepatectomy with bile duct resection in 6.5% of cases). In 23% of cases, only a bile duct resection was performed. Out of 394 patients included in the study, only one had an endoscopic tumor resection; there were no records of sectionectomy (3). In subsequent single-center research at the Seoul National University College of Medicine and the Beijing Union Medical College Hospital, where 112 and 28 patients were included, respectively, there were no records of laparoscopically assisted liver resection or sectionectomy. At both centers, doctors had to decide between left (33% in Seoul, 55% in Beijing) or right (24% in Seoul, 0% in Beijing) hepatectomy, hilar resection (12.5% vs. 0%) and pancreatoduodenectomy using the Whipple procedure (23% vs. 22%) (8, 9).

A literature review showed that the single-port laparoscopically assisted left lateral sectionectomy of an IPNB tumor performed at the Department of Abdominal Surgery was, on a global scale, an exception. A minor procedure, in terms of a smaller surgical incision of the skin as well as a less extensive liver resection, it allowed the patient a quicker and easier recovery. No complications associated with the surgery were observed, neither postoperatively nor in the follow-up period. Available literature lists bile duct inflammation, fever, vomiting, and developing seroperitoneum as possible complications (8). An R0 resection was achieved in this case with the smallest possible level of surgical invasiveness. Combined with the absence of lymphovascular invasion and an invasion into the liver parenchyma, it indicates a prognostically favorable

factor for the patient. Tumor recurrence was reported in 30% of the patients with a malignant form, as well as in 20% of those with a benign form (4).

Conclusion

Intraductal papillary neoplasm of the bile duct is a very rare tumor of the bile duct epithelium that has been the subject of studies for only the last 20 years. Our knowledge about the pathohistological and clinical characteristics of the tumor is thus predominantly based on rare reports and smaller, often retrospective studies of individual medical centers. Due to a larger incidence in the area, researchers from East Asia are leading the way in studying IPNB. No generally accepted guidelines for tumor treatment exist as of yet. Centers all over the world base their operative treatment choices mostly on their experience with treating other forms of bile duct carcinomas. A literature review has shown that they usually opt for more extensive, open resections of the liver or bile duct. Laparoscopic resections of the liver due to IPNB are extremely rare. A review of the currently available literature has also shown that the case described in this paper is the first reported case of single-port laparoscopic resection of an IPNB tumor.

References

1. Ohtsuka M, Shimizu H, Kato A, et al. Intraductal papillary neoplasms of the bile duct. *Int J Hepatol*. 2014;2014:459091.
2. Nanashima A, Imamura N, Sumida Y, et al. Clinicopathological aspects and diagnostic problems in patients with intraductal papillary neoplasm of the bile duct. *Anticancer Res*. 2018;38(4):2343–52.
3. Gordon-Weeks AN, Jones K, Harris E, et al. Systematic review and meta-analysis of current experience in treating IPNB: clinical and pathological correlates. *Ann Surg*. 2016;263(4):656–63.
4. Hohn P, Braumann C, Munding J, et al. Outcome determining factors of intraductal papillary neoplasm of the biliary tract (IPNB)—a single center survey and analysis of current literature. *J Gastrointest Cancer*. 2019;50(1):160–9.
5. Fléjou JF. [WHO Classification of digestive tumors: the fourth edition]. *Ann Pathol*. 2011;31(5 Suppl):S27–31.
6. Yeh TS, Tseng JH, Chiu CT, et al. Cholangiographic spectrum of intraductal papillary mucinous neoplasm of the bile ducts. *Ann Surg*. 2006;244(2):248–53.
7. Nanashima A, Sumida Y, Tomoshige K, et al. A case of intraductal papillary neoplasm of the bile duct with stromal invasion. *Case Rep Gastroenterol*. 2008;2(3):314–20.
8. Wu X, Li B, Zheng C, et al. Intraductal papillary neoplasm of the bile duct: a single-center retrospective study. *J Int Med Res*. 2018;46(10):4258–68.
9. Kim JR, Lee KB, Kwon W, et al. Comparison of the clinicopathologic characteristics of intraductal papillary neoplasm of the bile duct according to morphological and anatomical classifications. *J Korean Med Sci*. 2018;33(42):e266.

Liver Magnetic Resonance Imaging and the Histological and Clinical Picture of a Neonatal Near-Miss Case of a Term Newborn with Gestational Alloimmune Liver Disease Treated with Extracorporeal Membrane Oxygenation, Plasmapheresis, and Liver Transplantation

Primož Herga,^{1,*} Gorazd Mlakar,^{1,*} Darja Urlep Žužej,² Jernej Breclj,^{2,10} Petja Fister,³ Rafael Ponikvar,^{4,5} Branislava Ranković,⁶ Domen Plut,⁷ Ezio Bonanomi,⁸ Lorenzo D'Antiga,⁹ Štefan Grosek^{1,10,11}

¹ Department of Pediatric Surgery and Intensive Therapy, Ljubljana University Medical Center

² Department of Gastroenterology, Hepatology, and Nutrition, Division of Pediatrics, Ljubljana University Medical Center

³ Department of Neonatology, Division of Pediatrics, Ljubljana University Medical Center

⁴ Department of Nephrology, Division of Internal Medicine, Ljubljana University Medical Center

⁵ University Department of Internal Diseases, Medical Faculty, University of Ljubljana

⁶ Institute of Pathology, Medical Faculty, University of Ljubljana

⁷ Clinical Institute of Radiology, Ljubljana University Medical Center

⁸ Pediatric Intensive Care Unit, Pope John XXIII Hospital, Bergamo, Italy

⁹ Department of Pediatrics, Gastroenterology, Nutrition, and Dietetics, Hepatology, Pope John XXIII Hospital, Bergamo, Italy

¹⁰ Department of Perinatology, Division of Gynecology and Obstetrics, Ljubljana University Medical Center

¹¹ University Department of Pediatrics, Faculty of Medicine, University of Ljubljana

* The authors contributed equally to this work.

CORRESPONDENCE

Prof. Štefan Grosek, MD, PhD
stefan.grosek@kclj.si

KEY WORDS

gestational alloimmune liver disease, GALD, neonatal hemochromatosis, neonatal liver failure, perinatal hypoxia, ECMO, plasmapheresis, liver transplantation

CASE REPORT

SURGERY SURG ENDOS 2020; 2(2):
45-54

Abstract

Gestational alloimmune liver disease (GALD), a severe fetal or neonatal disease with liver failure, is rare but is still the most common reason for liver failure in the neonatal period. We present a term newborn with multiorgan failure: the neonate suffered perinatal hypoxia with meconium aspiration syndrome, which led to acute respiratory distress syndrome, treated with extracorporeal membrane oxygenation. In the first days of life the newborn developed signs of acute kidney injury and GALD, which progressed to liver failure with hypoglycemia, coagulopathy, elevated serum transaminases, hypoalbuminemia, extreme direct hyperbilirubinemia, and ascites. He was treated with plasmapheresis and intravenous immunoglobulins. Laboratory tests showed an increased concentration of serum iron

and hyperferritinemia. Gestational alloimmune liver disease was later confirmed by abdominal magnetic resonance imaging and liver biopsy. At the age of 3 months the infant was transferred to the transplant center in Bergamo, Italy, where he underwent liver transplantation. After the transplantation, bowel perforation occurred, and persistent infection developed. In the end, the liver graft failed, and the infant died of overwhelming sepsis. The magnetic resonance imaging, histological and clinical features, and course of the disease are presented.

Introduction

Originally, neonatal hemochromatosis (NH) was described as one of the most common causes of acute liver failure in the neonatal period (1). The frequency for developed countries was estimated to range from 14 to 60%, or even as high as 90% (2, 3). Nowadays, NH is regarded as a clinical condition that encompasses severe liver disease accompanied by extrahepatic siderosis. Researchers have shown that most cases of NH are caused by complement-mediated hepatocyte injury caused by maternal IgG, and so a new term was coined: gestational alloimmune liver disease (GALD) (4–7). Gestational alloimmune liver disease has been associated with acute, subacute, and chronic fetal and neonatal liver injury. Acute liver failure frequently occurs without extrahepatic siderosis or iron overload. The subacute and chronic liver injuries result in congenital cirrhosis present in nearly all cases of NH. The conditions of GALD and NH often co-occur and have thus become almost synonymous, but lately GALD has been considered the disease and NH its phenotypical expression. In the case of subacute and chronic liver disease, it would seem appropriate to call the disease GALD–NH (3). GALD can present from the 18th week of gestation up to 3 months after birth (5); in the case of the former, the fetus dies during pregnancy. If GALD occurs at the time of birth, a neonatal near-miss case can present. This is the first case described in the literature of a severely affected neonate with GALD and multiorgan failure treated with extracorporeal membrane oxygenation (ECMO) and plasmapheresis that survived past liver transplant.

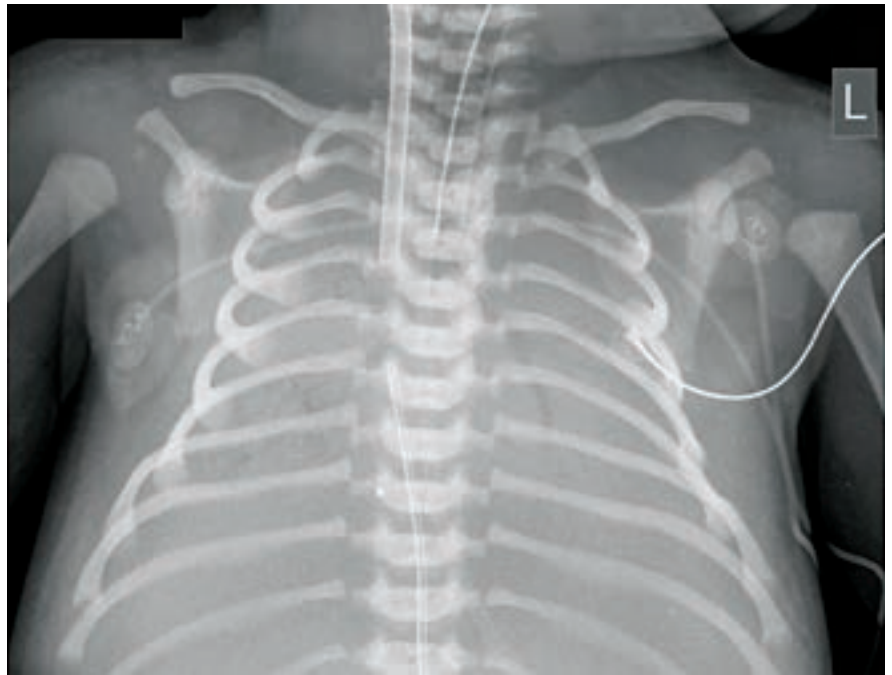
Case Report

A term newborn boy was transferred to our Multi-disciplinary Neonatal and Pediatric Intensive Care Unit (ICU) due to severe birth hypoxia with meconium aspiration syndrome and respiratory failure. It was the mother's first pregnancy and it was uneventful up until birth. Labor started spontaneously after 40 weeks of pregnancy but was completed with a caesarean section because of silent cardiotocography recordings. At birth, the infant was cyanotic, without visible breathing effort, and had no detectable heart rate. Apgar scores after 1, 5, and 10 minutes were 1, 3, and 6, respectively, and birth weight was 3,560 g (50th percentile). Following cardiopulmonary resuscitation, the return of spontaneous circulation appeared after 7 minutes and the first gasps after 15 minutes.

Chest X-ray showed complete white opacities of the lung (Figure 1). High-frequency oscillatory ventilation with inhaled nitrous oxide of 20 parts per million and surfactant application was started immediately because of severe hypoxic respiratory failure (oxygenation index 54.3). There was no improvement during the intensive respiratory treatment, and so treatment with veno-venous ECMO was started. The right jugular vein and left femoral vein were cannulated, 8 Fr and 10 Fr cannulas were used, and the pump was set at 2,676 rounds per minute to achieve a flow of 0.60 l/min. The flow was later adjusted based on blood gas analysis. Echocardiography revealed pulmonary arterial hypertension of 70 mmHg, persistent foramen ovale, and patent ductus arteriosus with dominant right-to-left shunt, a narrow muscular ventricular septal defect, and hypertrophy of the interventricular septum. Brain ultrasound on admission revealed mild brain edema, low systolic blood flow of 11 cm/s, and a resistive index consistent with ECMO. Due to perinatal hypoxia, an active induced hypothermia between 33.0 to 34.0 °C core temperature was started after admission to the ICU. Ultrasound of the visceral organs showed signs of free fluid in the abdominal cavity and almost no peristalsis, but otherwise no major signs of damage to the liver or abnormality of the visceral organs.

Vasoactive support with noradrenalin and dopamine was needed, and later milrinone was added. An ongoing fluid loss to third space was first treated with continuous infusion of furosemide. A thoracic drain had to be inserted into the right

Figure 1. Chest X-ray shows complete white opacities of the lung, with extracorporeal membrane oxygenation cannula, endotracheal tube, and umbilical vein catheter.



pleural cavity. Despite the ECMO and vasoactive support, after 7 days of treatment right-sided heart failure began to develop. A control echocardiography showed worsening of pulmonary arterial hypertension and progression of heart muscle hypertrophy. Additional surfactant application was attempted, but no major improvement in the lungs was found. Acute renal failure progressively developed (urea 15 mmol/l and creatinine 140 μ mol/l).

However, the most striking laboratory values were severely elevated liver enzymes at admission; AST 23.4 μ kat/l (normal value up to 0.58 μ kat/l) and ALT 10.0 μ kat/l (normal value up to 0.74 μ kat/l), but they decreased to slightly above normal values within a week (AST 2–3.5 μ kat/l, ALT 1–2 μ kat/l). However, the total bilirubin values were increasing constantly. On the 11th day after admission, total bilirubin was 758 μ mol/l (normal value up to 17 μ mol/l) and direct bilirubin 576 μ mol/l (normal value up to 5 μ mol/l). At the age of 11 days a series of 14 membrane plasma-exchange (plasmapheresis, PF) procedures were performed within the scope of 16 days: the first eight procedures were performed daily and the last six procedures after 2 days of free interval. Two volumes of plasma were exchanged (300 ml) and fresh frozen plasma was the replacement solution. Heparin was the anticoagulant used (100 IU at the start and 100 IU hourly). The extracorporeal PF circuit was primed with a mixture of packed red cells and saline solu-

tion to achieve hematocrit of 0.30 to 0.35 and connected to an ECMO device. After each procedure, the blood within the plasma-exchange circuit was discarded. All procedures were performed without any medical or technical adverse effects.

Despite continuous 40% glucose infusion (9.3 mg/kg/min), severe hypoglycemia with high values of lactate (up to 15 mmol/l) persisted for the first few days.

Following admission to the ICU, several meetings of various specialists were held to identify the origin of this severe clinical condition. Pediatric gastroenterologists, hematologist-oncologists, and neonatology specialists as well as dialysis specialist and occasionally other specialists were included in the diagnostic and therapeutic process. Differential diagnosis of acute liver failure in a neonate was discussed, and one of the most probable was GALD. During the treatment, other possible causes were excluded step by step: perinatal and neonatal infections, galactosemia and other metabolic disorders (lactate and pyruvate were within the normal range, analysis of amino acids in plasma and organic acids in urine, acylcarnitines, and succinylacetones were consistent with non-specific liver damage with no evidence of specific metabolic deficit), and hemolysis (Coombs test was negative). Iron overload due to frequent transfusions of erythrocytes was searched for because 36 transfusions of red blood cells were giv-

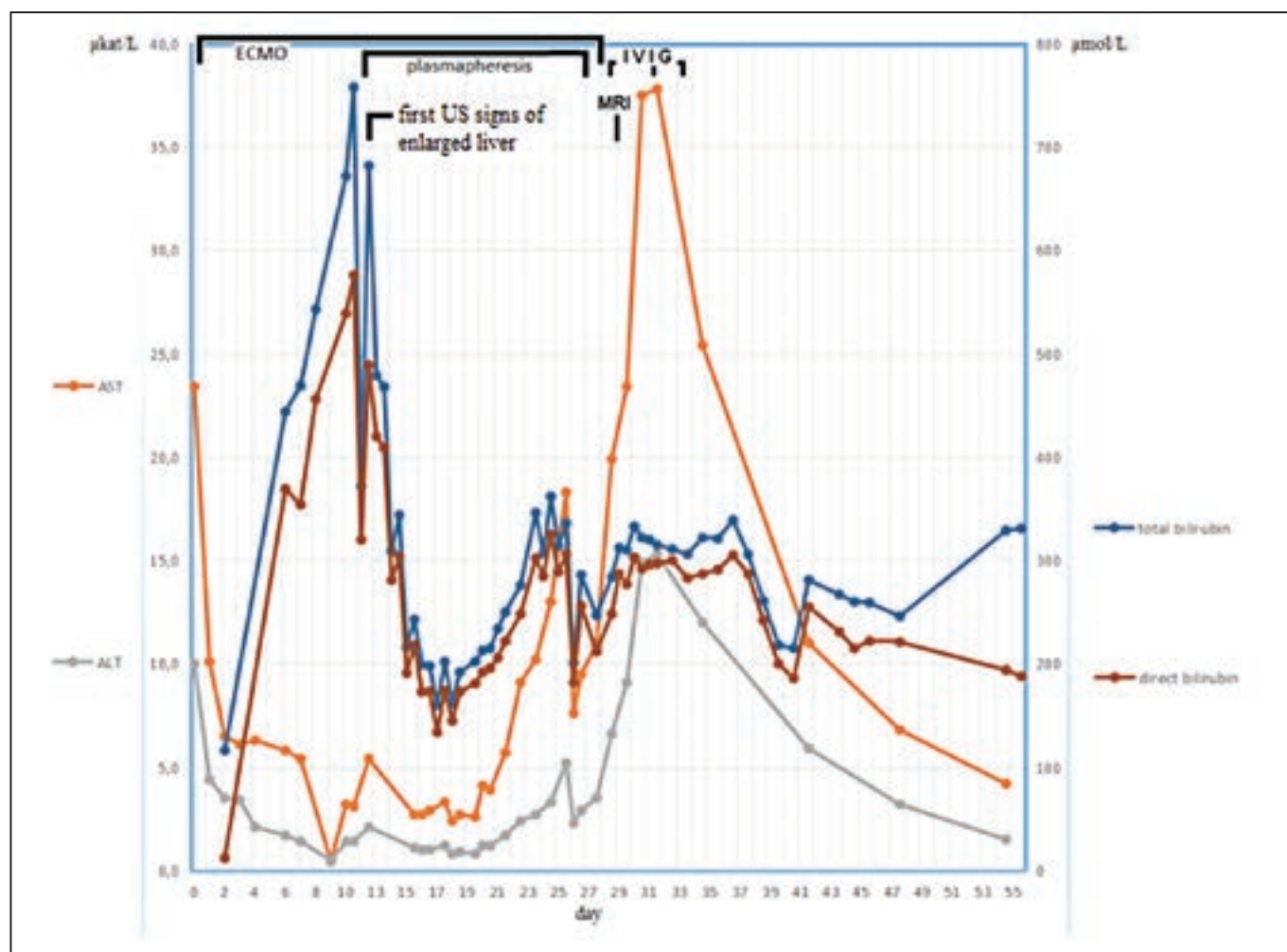


Figure 2. Values of AST, ALT, and total and direct bilirubin for the first 55 days of hospitalization. The duration of extracorporeal membrane oxygenation and plasmapheresis, as well as the date of magnetic resonance imaging, intravenous immunoglobulin applications, and first ultrasound with liver enlargement are also shown in the graph. ECMO = extracorporeal membrane oxygenation, MRI = magnetic resonance imaging, IVIG = intravenous immunoglobulins, US = ultrasound.

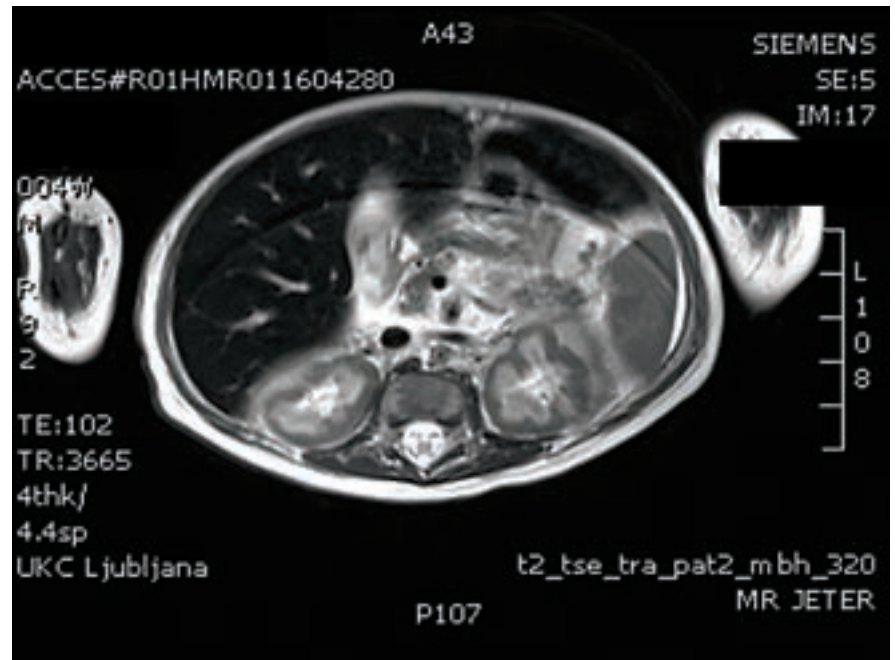
en to the patient during ECMO (an additional 14 transfusions were also given to the child later on). Magnetic resonance imaging showed no signs of iron depositions in the spleen. Tests of iron metabolism showed iron overload and normal concentration and saturation of available transferrin: Fe(III) $41.8 \mu\text{mol/l}$ (normal range $12.9\text{--}36.6 \mu\text{mol/l}$), total iron-binding capacity (TIBC) $47.3 \mu\text{mol/l}$ (normal range $27.7\text{--}59.1 \mu\text{mol/l}$), unsaturated iron-binding capacity (UIBC) $5.5 \mu\text{mol/l}$, transferrin 1.6 g/l (normal range $0.70\text{--}2.39 \text{ g/l}$), and haptoglobin $< 0.07 \text{ g/l}$ (normal values $0.41\text{--}1.65 \text{ g/l}$). The ferritin concentration was elevated: $7,263 \mu\text{g/l}$ (normal range $40\text{--}775 \mu\text{g/l}$); alpha fetoprotein ($5,651 \text{ kU/l}$) and C5b-9 lytic complex in plasma (247 ng/ml ; normal value $127\text{--}303 \text{ ng/ml}$)

were within normal limits for the patient's age. To determine whether iron overload was due to frequent blood transfusions or any other cause (i.e., GALD), a different set of investigations was performed when possible due to long-lasting ECMO treatment.

Only after 28 days could the infant finally be weaned from ECMO. Vasoactive support with noradrenalin in a low dose was continued, and inhaled nitric oxide and milrinone were gradually stopped and replaced by sildenafil. Weaning from respiratory support progressed slowly.

After weaning from ECMO, the first investigation performed to prove GALD was a magnetic resonance imaging of the abdomen (Figure 3). The in-

Figure 3. Magnetic resonance imaging showed reduced signal intensity in the liver on T2-weighted images and T2*-weighted images, indicating liver iron overload. Quantitative assessment using the method described by Gandon et al. (8) was also employed and confirmed liver iron overload. Magnetic resonance imaging did not show signs of iron accumulation in the spleen, pancreas, or myocardium.



creased signal intensity of the liver on T2-weighted magnetic resonance images was fairly suggestive of iron depositions in the liver parenchyma, whereas the signal of the spleen and pancreas was less intense. A decision to start treatment with intravenous immunoglobulins (IVIG) was made; the infant received three applications of 1g/kg of body mass. At the time, liver biopsy was still considered too risky because of severe bleeding disorder.

After plasmapheresis was stopped, bilirubin was still elevated (total bilirubin 200–350 $\mu\text{mol/l}$, direct bilirubin 150–300 $\mu\text{mol/l}$). Other signs of liver failure were present as well: low albumin ($\sim 25 \text{ g/l}$) and prolonged prothrombin time (0.3–0.5).

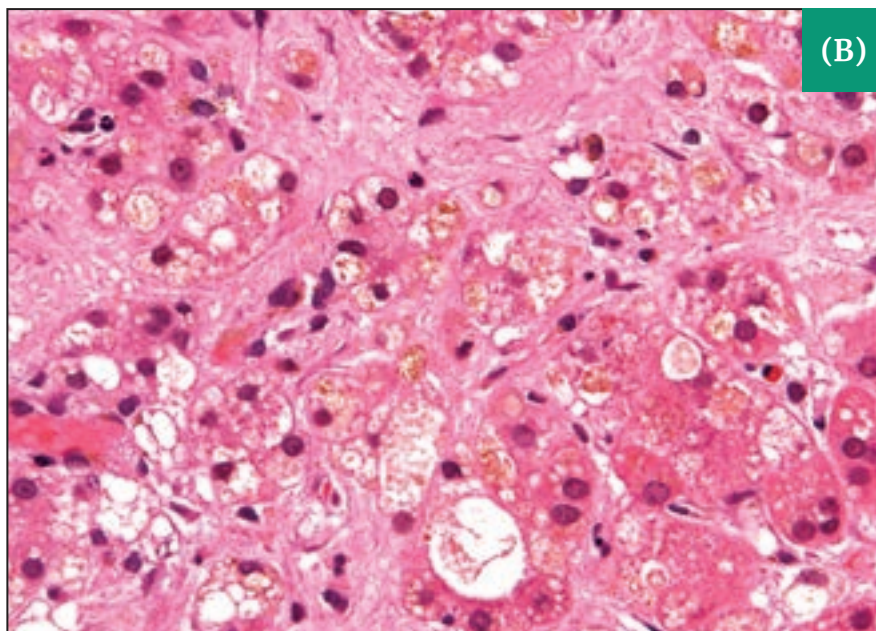
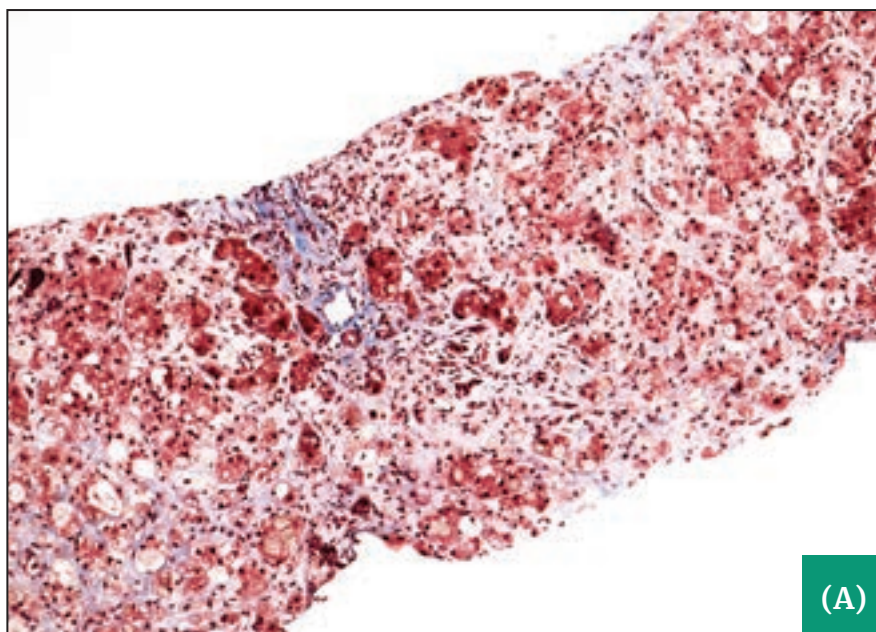
After 5 weeks of hospitalization, the infant's condition started to deteriorate again. He stopped tolerating feedings via a nasogastric tube, laboratory signs of liver failure were more pronounced, and portal hypertension and ascites started to develop. Within a week, the abdominal pressure measured through a urinary bladder-inserted catheter (AbViser™ AutoValve™ IAP Monitoring Device) increased to 25 mmHg despite intensive diuretic therapy, and renal failure progressed. After applications of coagulation factor VIIa, human fibrinogen, and human prothrombin complex, a pig-tail catheter was inserted into the peritoneal cavity for ascites drainage and peritoneal dialysis. Due to bleeding disorder, the infant regularly received plasma transfusions and vitamin K.

After 10 weeks of hospitalization, the decision was made to perform an ultrasound-guided needle liver biopsy; during the same procedure, the peritoneal catheter was also changed because of malfunction. Despite preoperative preparation with vitamin K, coagulation factor VIIa, tranexamic acid, fresh frozen plasma, and platelet transfusion, life-threatening hemorrhage occurred. The infant received additional doses of coagulation factor VIIa, human fibrinogen, and human prothrombin complex and several blood transfusions, but he nonetheless had to be taken to the operating theatre for surgical intervention. Ligation of an injured branch of the mesenteric artery, which was damaged during replacement of the peritoneal catheter, was performed.

The microscopic histology examination of the liver specimen showed poorly preserved orthotopic structure of the liver. Advanced fibrosis, ductular reaction, giant cells, and pseudoacinar hepatocyte changes were appreciated. Hepatocytes were pleomorphic with abundant vacuolated cytoplasm and coarse granular hemosiderin pigment deposits. Inflammation was minimal, but immunohistochemical staining for C5b9 showed a positive reaction in hepatocytes, suggesting complement-mediated hepatocyte injury (Figure 4).

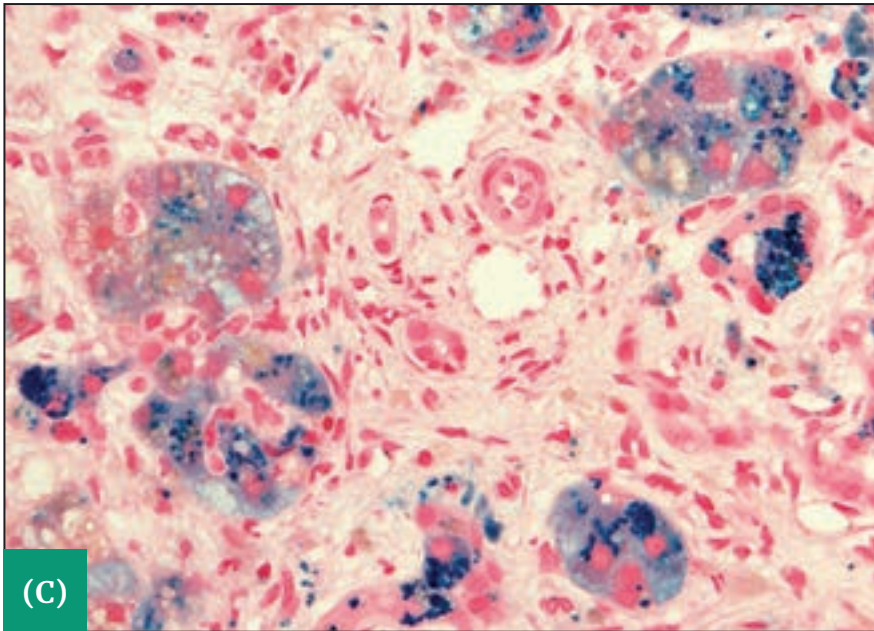
After contacting a specialized center for liver transplantation in Bergamo, Italy, their first ad-

Figure 4. (A) Masson's trichrome special stain showing moderate panlobular fibrosis (original magnification 10×), (B) Pleomorphic hepatocytes exhibiting giant-cell and pseudoacinar transformation as well as intracytoplasmic accumulation of coarse granular brown pigment (routine HE staining; original magnification 20×), (C) Perls Prussian blue special stain showing the presence of iron in hepatocytes (original magnification 40×), (D) Immunohistochemical staining for C5b9 demonstrated a positive reaction in hepatocytes (original magnification 40×).

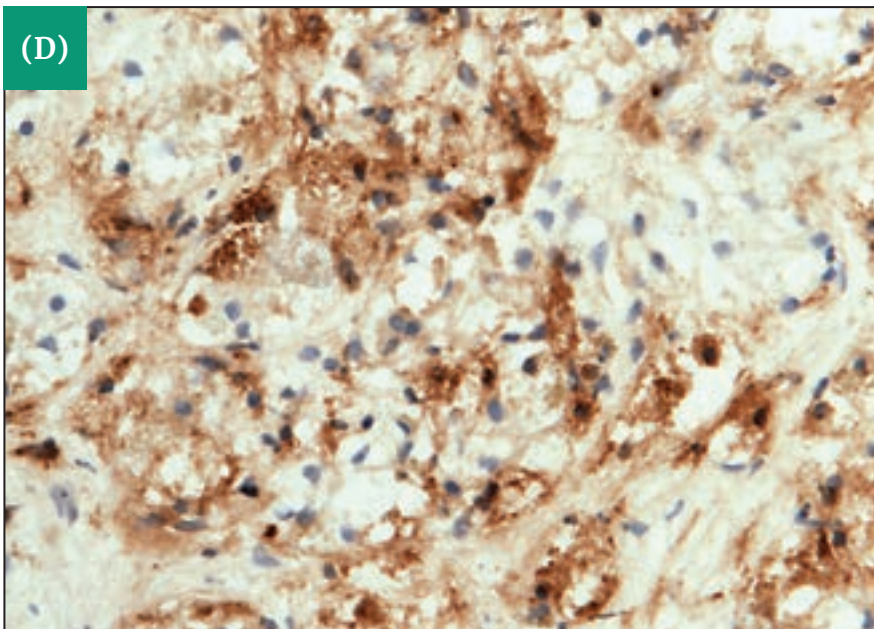


vice was to wait because even a severely damaged liver can show some signs of repair. Moreover, mortality after liver transplantation in infants with GALD is still high. The infant remained in our ICU and, 3 months after admission, was successfully extubated on the second attempt. Afterward he still needed noninvasive respiratory support with nasal bilevel positive-pressure ventilation and FiO_2 of 0.25 to 0.30. After this the infant's condition again slowly deteriorated: bilirubin was rising, prothrombin time was prolonged despite regular plasma transfusions, and he still did not tolerate feeding by nasogastric tube. We

started to make arrangements for transport to the transplant center in Bergamo, Italy. Several neurological assessments were made during ICU treatment, which showed a slightly abnormal neurological condition. After cardiopulmonary resuscitation and treatment on ECMO, the infant suffered a minor cerebrovascular insult in the right anterior region of basal ganglia, as well as several small punctiform hemorrhages and ischemic strokes in the cerebellum. Electroencephalography showed no epileptic activity, and no signs of major neurological dysfunction were seen on clinical examination.



(C)



(D)

After 112 days of treatment in the ICU, the infant was transferred to Bergamo, Italy, for the planned liver transplantation. On arrival at the hospital in Bergamo, Italy, he was first stationed in the pediatric ICU and then, after a week and a half, moved to the gastroenterology department after moderate clinical improvement. While on a priority waiting list for transplantation, his clinical condition deteriorated due to sepsis (*Klebsiella oxytoca* and *Staphylococcus epidermidis* were isolated from blood cultures) and worsening of liver function. He was treated with meropenem, vancomycin, and gentamycin and was

transferred back to the pediatric ICU. Noninvasive respiratory support and total parenteral nutrition had to be reintroduced. After 9 days he was transferred back to the gastroenterology department until liver transplantation (a split segment II/III transplantation from an O+ donor was performed; there was profound bleeding during the operation). Antibiotic coverage with piperacillin/tazobactam and fluconazole was continued after transplantation. The infant was extubated on the 4th day after surgery and needed respiratory support afterwards. An abdominal drain was inserted due to ascites on the 7th day after trans-

plantation. The next day a biopsy of the liver was performed due to an increase in bilirubin level: infective-type granulocyte cholangitis was seen, and antibiotic therapy with vancomycin and meropenem was started. After 5 days of treatment, moderate improvement was seen, and antibiotics were stopped after another 6 days. After 2 days, perforation of the bowel occurred and a direct suture of the punctiform defect on the terminal ileal loop was performed, and vasoactive support with adrenalin and noradrenalin also had to be introduced. After 10 days (during this time, several diagnostic tests were performed to elucidate this clinical condition) septic shock and multiorgan failure developed. Exploratory laparotomy, debridement, and sutures of the dehiscence on the previous bowel sutures were performed, and treatment with a Bogota bag and vacuum-assisted closure (VAC) was also started. A liver biopsy, taken at that time, showed signs of ischemic liver damage (nonmechanical cholestasis, decreased bile ductuli count with thrombi inside, with no signs of infection). After 4 days, additional signs of shock presented, and an increase in vasopressor infusion was needed, as well as transfusion of blood products. In addition, ST elevation and a raise in troponin also occurred. An additional computed tomography scan was performed, which showed increased permeability of the liver vessels, a 5 mm arteriovenous fistula, several ischemic areas in the liver, and a 2 × 10 cm hematoma. On the same day surgical revision was performed, the Bogota bag was removed and the abdominal cavity closed. The poor clinical state persisted; the infant was anuric, anasarca developed, and intrabdominal pressure rose to 20 mmHg. Continuous veno-venous hemodialysis was started. Despite everything, multiorgan failure progressed, and the infant did not respond to large transfusions of blood products or increase of vasopressors. Another laparotomy and exploration of the abdomen was performed, but no additional perforation was found; perfusion of the bowel was poor, but the bowel was still vital. Later, shock progressed and the liver completely failed, and severe lactacidosis, hyperammonemia, coagulopathy, and hypoglycemia (when glucose infusion was even briefly stopped) developed. The infant died in progressive shock at the age of 7 months and 14 days.

Discussion

The near-miss case of a term newborn with multiorgan failure described here—severe macrophage activation syndrome, acute kidney injury, acute GALD treated with ECMO, PF, and liver transplantation—is one of the rare cases of GALD that presented associated with severe acute respiratory distress syndrome. Because no signs of congenital cirrhosis and no abdominal extrahepatic siderosis was found, we believe our patient suffered a case of acute GALD that had evolved at the end of the second or in the third trimester of gestation. We searched the literature for similar cases but found that cases died in early or late pregnancy or shortly after birth, whereas less severe cases were born uneventfully, and NH developed only later after birth. Clinical cases of GALD may present from almost no visible signs of the disease (7) to multiorgan failure together with fulminant liver failure. What is peculiar in our neonatal near-miss case is that his condition suddenly deteriorated during delivery, which presented with fetal distress, passing the meconium and its aspiration to the lungs, which led to cardiac arrest, acute respiratory distress syndrome, and perinatal hypoxia with highly elevated liver enzymes, which we could only later link to acute GALD. No other perinatal cause could explain the sudden life-threatening condition at delivery, which necessitated an urgent caesarean section. Ischemia can cause liver failure (9, 10), and our erroneous first belief was that the highly elevated liver enzymes were related to liver hypoxia, but the clinical condition and clinical deterioration suggested that something else was the reason for acute liver failure. The liver is normally very resistant to hypoxia, and it is unlikely that the neonate's brain would escape injury while the liver would sustain such severe damage (11). With hypoxia so severe to cause such liver damage, we would also expect profound hypoxic-ischemic injury to the brain, but there was none to be seen on subsequent brain magnetic resonance imaging. We assume that the neonate was so severely affected by acute GALD and he passed meconium because of intrauterine distress. Moreover, the severely affected lungs were not typical even for a severe case of meconium aspiration, and our suspicion is that the lungs were also affected by iron deposits. We could find only one case report that found iron deposits in the lung parenchyma (12), and a lung biopsy, if it had been performed

in our infant, would have confirmed or excluded iron deposits.

Birth asphyxia was the main cause for the ICU admission, and evident signs of liver failure only developed after a few days. After the initial decrease in liver enzymes, a secondary increase with high elevations of bilirubin followed without an increase of aminotransferase levels, implying previously damaged liver parenchyma with reduced hepatocyte mass. As a possible cause of neonatal liver failure, metabolic disorders were excluded by laboratory testing. To confirm the diagnosis of GALD, a number of different diagnostic tests can be performed (alpha fetoprotein level, tests of iron metabolism, oral mucosa biopsy, magnetic resonance imaging of the liver and other parenchymal organs, and liver biopsy) (5, 7, 13, 14). The alpha fetoprotein levels were normal in our case. The tests for iron metabolism showed iron overload and hyperferritinemia, which are characteristic but non-specific for GALD, but normal concentration and saturation of available transferrin. At the time of presentation, more invasive investigations were not easily obtainable due to prolonged ECMO treatment and bleeding disorder. Later on, magnetic resonance imaging was performed, and it showed iron accumulation in the liver, but not in the spleen, pancreas, or myocardium. Magnetic resonance imaging findings of iron accumulation in the liver with sparing of iron accumulation in other organs of the reticuloendothelial system are a hallmark of hemochromatosis and exclude multiple blood transfusions as the cause for the iron overload (15).

The alloimmune process in GALD injures the hepatocytes so that they produce less angiotensinogen, which is necessary for proper renal development, which leads to dysgenesis of proximal tubules and acute kidney injury (16). Neonates with GALD often present with renal hypoplasia and paucity of peripheral glomeruli. The kidney injury was present in our case because the neonate had elevated urea and creatinine levels from birth and later needed peritoneal dialysis. According to the histopathology findings, the arrest in renal development dates back to around the 24th week of gestation, and therefore the liver failure occurred in the late second or early third trimester, leading to acute GALD at the time of birth, elevated liver enzymes, and no signs of cirrhosis or extrahepatic siderosis due to the relatively short duration of the disease.

With high suspicion of GALD and to avoid bilirubin toxicity and further injury to the liver, PF was performed and IVIG infusion was given to the infant (6, 17). Exchange transfusion for treatment of GALD (5, 17) and high-volume hemofiltration for liver failure (18) has been reported in the literature, but not PF as we performed it. Due to cardiocirculatory instability and prolonged ECMO treatment, exchange transfusion was not possible, and so we decided on PF, which has not yet been described in the literature for the treatment of acute GALD. When ECMO was stopped, IVIG therapy was started and PF was no longer performed. At this point, abdominal magnetic resonance imaging was also performed, which was strongly suggestive of acute GALD with iron overload in the liver parenchyma without extrahepatic siderosis, but the final diagnosis was later confirmed by liver biopsy (13). The magnetic resonance imaging of the abdomen was suggestive of iron deposits in the liver (7, 13). Because we have not proven any extrahepatic siderosis, which is the hallmark of subacute or chronic GALD with NH, we refer to our case as an acute form of GALD (3).

When GALD is considered in the differential diagnosis, the recommendation is to start IVIG immediately (5) and wait for the effects. Despite the IVIG application, the infant's condition did not improve and so, despite our initial reluctance, knowing that overall survival of infants undergoing liver transplantation for the indication of GALD is ~35% (16, 17), plans for transplantation were made.

Conclusion

Gestational alloimmune liver disease is a severe and often fatal liver disease that can present in utero or several weeks after birth. Because it is rather rare, it is often misdiagnosed. It should always be considered with stillborns and neonates with acute, subacute, or chronic liver failure with hypoglycemia, coagulopathy, elevated serum transaminases, hypoalbuminemia, extreme direct hyperbilirubinemia, and ascites. In a near-miss case of a term newborn with highly elevated liver enzymes and bilirubin levels, diagnosis of GALD should be highly suspicious. The usual treatment of GALD with exchange transfusion and application of IVIG is safe and should be started after the

first suspicion of the disease. We have shown that treatment with PF in cases when ECMO treatment is in effect can also be performed safely and effectively. Care should be taken to properly follow up and potentially treat future pregnancies of previously affected mothers (19).

References

1. Sheflin-Findling S, Annunziato RA, Chu J, et al. Liver transplantation for neonatal hemochromatosis: analysis of the UNOS database. *Pediatr Transplant*. 2015;19(2):164–9.
2. Squires RH, Rand EB, Hoppin AG. Acute liver failure in children: etiology and evaluation. UpToDate [internet]. Available from: <http://www.uptodate.com/contents/acute-liver-failure-in-children-etiology-and-evaluation>
3. Taylor SA, Whittington PF. Neonatal acute liver failure. *Liver Transpl*. 2016;22(5):677–85.
4. Pan X, Kelly S, Melin-Aldana H, et al. Novel mechanism of fetal hepatocyte injury in congenital alloimmune hepatitis involves the terminal complement cascade. *Hepatology*. 2010;51(6):2061–8.
5. Feldman AG, Whittington PF. Neonatal hemochromatosis. *J Clin Exp Hepatol*. 2013;3:313–20.
6. Whittington PF. Fetal and infantile hemochromatosis. *Hepatology*. 2006;43(4):654–60.
7. Lopriore E, Mearin ML, Oepkes D, et al. Neonatal hemochromatosis: management, outcome, and prevention. *Prenat Diagn*. 2013;33(13):1221–5.
8. Gandon Y, Olivie D, Guyader D, et al. Noninvasive assessment of hepatic iron stores by MRI. *Lancet*. 2004;363:357–62.
9. Zozaya Nieto C, Fernández Caamaño B, Muñoz Bartolo G, et al. Presenting features and prognosis of ischemic and nonischemic neonatal liver failure. *J Pediatr Gastroenterol Nutr*. 2017;64:754–9.
10. Bitar R, Thwaites R, Davison S, et al. Liver failure in early infancy: aetiology, presentation, and outcome. *J Pediatr Gastroenterol Nutr*. 2017;64:70–5.
11. Martín-Ancel A, García-Alix A, Fernando Cabañas FG, et al. Multiple organ involvement in perinatal asphyxia. *J Pediatr*. 1995;127(5):786–93.
12. Mariano da Rocha CR, Rostiola Guedes R, Kieling CO, et al. Neonatal liver failure and congenital cirrhosis due to gestational alloimmune liver disease: a case report and literature review. *Case Rep Pediatr*. 2017;2017:7432859.
13. Deugnier Y, Turlin B. Pathology of hepatic iron overload. *Semin Liver Dis*. 2011;31(3):260–71.
14. Knisely AS, O’Shea PA, Stocks JF, et al. Oropharyngeal and upper respiratory tract mucosal-gland siderosis in neonatal hemochromatosis: an approach to biopsy diagnosis. *J Pediatr*. 1988;113(5):871–4.
15. Hernando D, Levin YS, Sirlin CB, et al. Quantification of liver iron with MRI: state of the art and remaining challenges. *J Magn Reson Imaging*. 2014;40(5):1003–21.
16. Whittington PF. Gestational alloimmune liver disease and neonatal hemochromatosis. *Semin Liver Dis*. 2012;32(4):325–32.
17. Rand EB, Karpen SJ, Kelly S, et al. Treatment of neonatal hemochromatosis with exchange transfusion and intravenous immunoglobulin. *J Pediatr*. 2009;155(4):566–71.
18. Chevret L, Durand P, Lambert J, et al. High-volume hemofiltration in children with acute liver failure. *Pediatr Crit Care Med*. 2014;15(7):e300–5.
19. Whittington PF, Kelly S. Outcome of pregnancies at risk for neonatal hemochromatosis is improved by treatment with high-dose intravenous immunoglobulin. *Pediatrics*. 2008;121(6):e1615–21.

Laparoscopically Assisted Foreign Body Removal from the Cecum: A Case Report

Aleksander Göntér, Primož Sever

Department of Abdominal Surgery, Ljubljana University Medical Center

CORRESPONDENCE

Aleksander Göntér, MD
aleksander.gonter@kclj.si

KEY WORDS

foreign body in cecum,
laparoscopy, laparoscopic removal,
case report

CASE REPORT

SURGERY SURG ENDOS 2020; 2(2):
55-59

Abstract

Ingested foreign bodies (FBs) are commonly seen occurrences in emergencies. They are associated with various degrees of trauma and may lead to serious complications such as perforation or penetration of the gastrointestinal tract. The risk of complications depends on the size, shape, sharpness, and material of the FB, and may be greater in patients with preexisting conditions such as Crohn's disease, intestinal stenosis, ulcerative colitis, or adhesions due to prior abdominal surgeries. The management of FB ingestions depends on their location in the digestive tract and the clinical condition of the patient. Eighty percent of ingested FBs that reach the stomach will pass uneventfully through the gastrointestinal tract, and only one percent of them will eventually need surgery. In the past, exploratory laparotomy has been the procedure of choice for management of complicated FB impactions, but with the development and advancement of new surgical techniques surgeons are increasingly tempted to use them in emergency settings. This case report presents a successful laparoscopically assisted extraction of an ingested toothpick that penetrated the cecum. We demonstrate the feasibility and advantages of laparoscopically assisted FB extraction from the large intestine in selected cases, offering the patient faster recovery, less morbidity, less pain, and smaller scars.

Introduction

Foreign bodies (FB) in the gastrointestinal (GI) tract are commonly seen occurrences in the emergency room. They may occur deliberately or accidentally. The FBs may be food-related such as fish bones, food boluses, or crab shells, or may include a great variety of other objects, including toothpicks, dentures, needles, stones, fishhooks, broken plastic items, batteries, and so on (1–3). The majority of non-food FB ingestions occur in the pediatric population, with a peak incidence between ages 6 months and 6 years. Food-related FB ingestions are more common in adults, and in adults non-food FB

ingestions are mostly associated with psychiatric disorders, impairment caused by other substances (alcohol or other drugs), mental retardation, or those seeking some secondary gain (e.g., prisoners) (4).

The risk for a patient that has ingested a FB depends upon the type and nature of the object, its location, and the patient population. Objects with pointed tips and sharp edges have the highest risk of complications, which may be as high as 35%. Toothpicks and chicken bones cause the most intestinal perforations (5–7). Foreign bodies most commonly lodge in areas of the GI tract where the lumen is physiologically or pathologically narrowed. The two main locations are the esophagus and the rectum, but they can be found throughout the entire GI tract. Fortunately, 80 to 93% of all swallowed FBs that reach the stomach will uneventfully pass through the GI tract; only 10 to 20% require endoscopic removal, and 1% surgery (1, 7).

The clinical manifestation of ingested FBs has a very wide array of signs and symptoms. Depending on the location, patient population, and form of the object, it can be asymptomatic or present with dysphagia, odynophagia, chest discomfort, hypersalivation, respiratory symptoms, abdominal pain, localized or generalized peritonitis, abdominal wall abscess, bleeding, pruritus, or intestinal obstruction (1, 2, 4).

A minority of patients will develop complications, which include impaction, obstruction, laceration, perforation with abscess formation, hemorrhage, fistula formation, and mucosal ulceration (3, 6, 7).

The establishment of the diagnosis depends on the condition of the patient upon admission. It is necessary to obtain the complete medical history, perform a physical examination, and receive a radiographic evaluation (6). The goal is to determine the location and type of the object, presence of complications, and any underlying conditions or comorbidities (1). The patient may be fully conscious and communicative, and may be able to fully identify the material swallowed and point to the area of discomfort. Demented, mentally impaired, psychiatrically deranged, young children, and other uncooperative patients may not provide a historical basis for suspected FBs. Often they are presented to the emergency department only when symptoms or signs of complications occur (4, 5). A physical examination is impor-

tant in determining the patient's general health status and signs of FB complications. In terms of GI-tract FBs, the abdomen should be examined for evidence of bowel obstruction or peritonitis. Findings can be often normal, but they may rapidly evolve into serious complications (1, 4, 6). Radiological imaging is very helpful and thus strongly recommended to determine the location of the FB. Depending on their radiolucency, FBs can be identified on a plain X-ray image, computed tomography (CT) scan, ultrasound, magnetic resonance imaging, or flexible endoscopy, which can also provide immediate therapy (1, 3, 8, 9).

The management of ingested FBs requires careful planning for an optimal outcome. Most FBs pass through the GI tract uneventfully. However, when complication occur, they pose a difficult management dilemma for a physician (1, 4, 6). The therapy must be individualized and based on the patient's health status, the type of FB, its location, and the perceived risk of complications. We need to ensure that all necessary therapy, equipment, and accessories are ready and available. If feasible, endoscopic procedures are the first-choice therapy, and surgical management is indicated when endoscopic retrieval has failed, or when a complication has occurred (2).

Several possible surgical techniques can be performed. These include open procedures or minimally invasive surgery. Although laparotomy still remains the gold standard for surgical management in complicated cases, there are increasingly more cases of successful management of complicated FB ingestions with minimally invasive laparoscopic procedures. Several studies have reported the benefits of a laparoscopic approach. They include reduced pain and postoperative ileus, better cosmetic results with smaller incisions, earlier mobilization, a shorter hospital stay, and decreased incidence of postoperative hernias (4, 10, 11).

To our knowledge, this is one of the first reported cases of laparoscopically assisted removal of an ingested sharp object that became stuck and penetrated the colon. This case report shows that the laparoscopic approach is feasible and safe, and that it should be considered in selected cases of FB ingestions with complications.

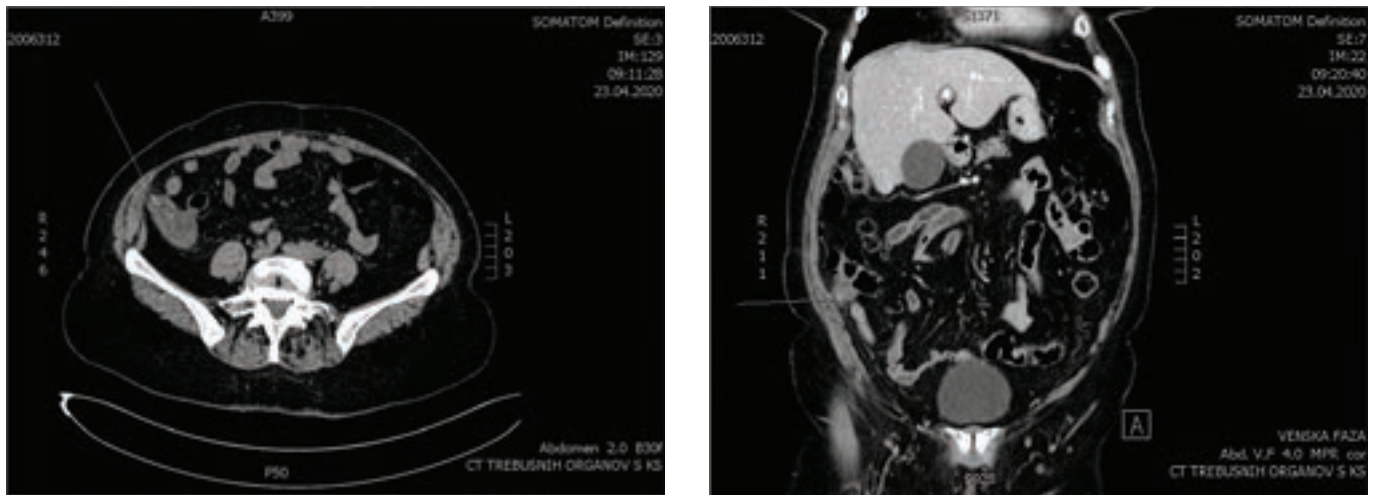


Figure 1. Abdominal computer tomography scan showing an ingested foreign body: axial and coronal plain.

Case Report

A 79-year-old woman with hypertension, hypercholesterolemia, and hypothyroidism presented to the emergency department because of abdominal pain and fever that had begun on the same day. She denied any FB ingestion in her medical history or any other symptoms. She had no prior abdominal surgeries.

On examination, the patient's temperature was 37.0 °C, heart rate 98 beats per minute, blood pressure 145/78 mmHg, and oxygen saturation 95% while breathing ambient air. Mild abdominal tenderness in the right lower abdominal quadrant was present. The remainder of the physical examination was normal. The laboratory data on admission were as follows: white blood count: $15.2 \times 10^9/l$ and C-reactive protein level 16 mg/l; other blood parameters and urine values were in normal range. An abdominal ultrasound was obtained, which showed gallstones without any other pathological presence. However, because of the pain and slightly elevated inflammatory markers, the patient was admitted to the Department of Abdominal Surgery. Analgesics and empiric antimicrobial therapy were added to her therapy.

The following day the patient's clinical condition worsened. The inflammatory markers were further elevated and the pain was still persisting. A CT scan of the abdomen showed an impacted thin

linear hyperdense 5 cm long FB in the cecum with signs of local irritation. There was no evidence of free air or abscess formation, but perforation could not be excluded (Figure 1). The patient again did not recall any history of ingesting a FB.

Based on the CT findings and her health condition, urgent surgery was initiated. A laparoscopic approach was chosen. The patient was placed in a supine position. The surgeon and the assistant stood on the left side of the patient. The abdomen was insufflated and three trocars were placed: one supraumbilically (11 mm), one in the left lower abdominal quadrant (5 mm), and one suprapubically (12 mm). An exploration showed a FB penetrating the cecum (Figure 2).

The FB was identified as a toothpick. It was safely extracted with a grasper (Figures 3, 4). The hole in the penetrated cecum was excised with an endoscopic linear cutter stapler. In addition, an appendectomy and cholecystectomy were performed. Two drains were placed. The entire procedure was well tolerated by the patient with no intraoperative complications.

Clear fluid was drained, and the drains were removed on the 2nd postoperative day. Antibiotics were continued until the normalization of inflammatory markers. No major analgesic intake was necessary. The patient recovered without complications and was discharged on the 5th postoperative day. No further complications were noticed.

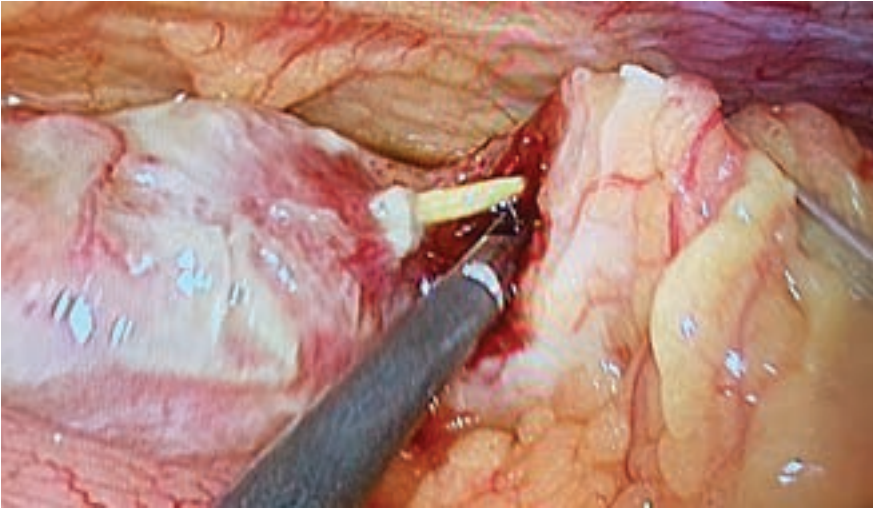


Figure 2. Toothpick penetrating the cecum.

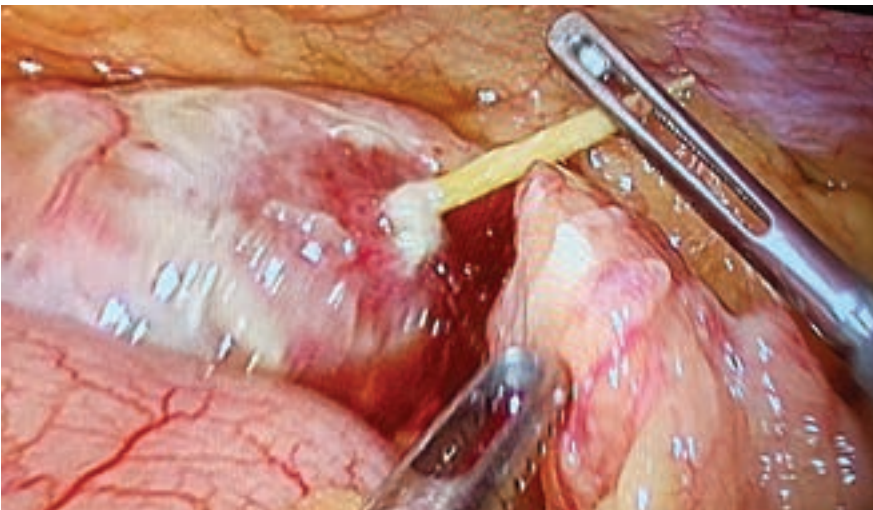


Figure 3. Extraction of the toothpick.

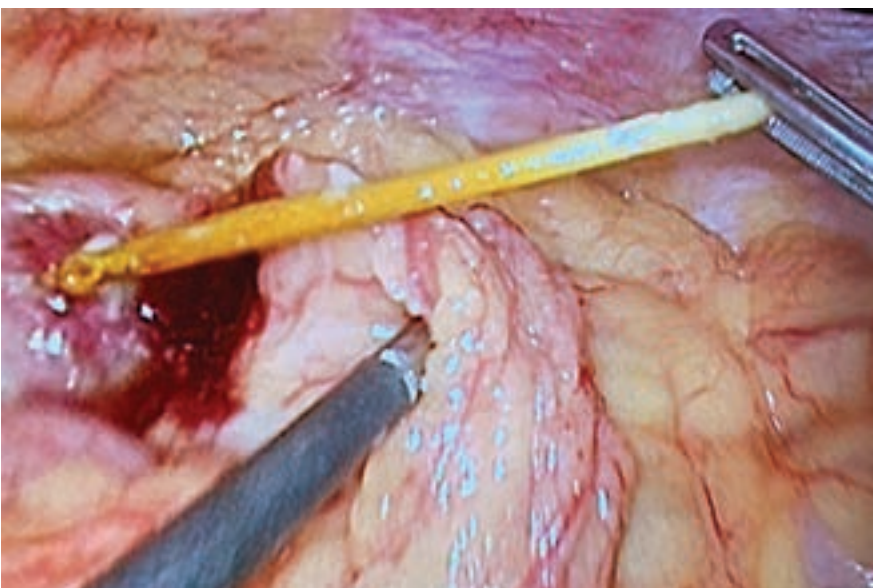


Figure 4. Extracted toothpick.




Conclusion

Foreign body ingestion is a commonly seen occurrence in emergencies. In most cases, the FB passes the GI tract uneventfully, but sometimes it can cause serious complications. Management can pose dilemmas for surgeons when deciding what method is appropriate for treatment. Depending on the location, material, size, shape, and complication, several operative methods can be performed.

We searched PubMed for English literature reporting toothpicks penetrating the colon using the terms *colon* and *toothpick*. The vast majority of the cases were managed with a laparotomy. This case shows that in selected cases the laparoscopic approach is a feasible, safe, and good method for extracting a penetrating FB from the cecum. The recovery is quick and the cosmetic result is better. However, more studies are needed to verify the advantage of this technique.

References

1. Smith MT, Wong RKH. Foreign bodies. *Gastrointest Endosc Clin N Am*. 2007;17(2):361–82.
2. Birk M, Bauerfeind P, Deprez PH, et al. Removal of foreign bodies in the upper gastrointestinal tract in adults: European Society of Gastrointestinal Endoscopy (ESGE) Clinical Guideline. *Endoscopy*. 2016;48(5):489–96.
3. Zegos P, Oikonomou A, Souftas V, et al. Endoscopic removal of a toothpick perforating the sigmoid colon and causing chronic abdominal pain: a case report. *Cases J*. 2009;2(8):3–7.
4. Eisen GM, Baron TH, Dominitz JA, et al. Guideline for the management of ingested foreign bodies. *Gastrointest Endosc*. 2002;55(7):802–6.
5. Selivanov V, Sheldon GF, Cello JP, et al. Management of foreign body ingestion. *Ann Surg*. 1984;199(2):187–91.
6. Frossard JL, De Peyer R. An unusual digestive foreign body. *Case Rep Gastroenterol*. 2011;5(1):201–5.
7. Henderson CT, Engel J, Schlesinger P. Foreign body ingestion: review and suggested guidelines for management. *Endoscopy*. 1987;19(2):68–71.
8. Müller KE, Arató A, Lakatos PL, et al. Foreign body impaction in the sigmoid colon: a twenty euro bet. *World J Gastroenterol*. 2013;19(24):3892–4.
9. Mima K, Sugihara H, Kato R, et al. Laparoscopic removal of an ingested fish bone that penetrated the stomach and was embedded in the pancreas: a case report. *Surg Case Reports*. 2018;4(1):3–6.
10. Zhu R, Jian Z, Yu H. Transumbilical single-incision laparoscopic-assisted technique for removal of ileocecal foreign body. *Wideochirurgia I Inne Tech Maloinwazyjne*. 2018;13(2):266–9.
11. Chia DKA, Wijaya R, Wong A, et al. Laparoscopic management of complicated foreign body ingestion: a case series. *Int Surg*. 2015;100(5):849–53.



Secure, Intuitive, Anywhere

Procedure Recording and Medical Content Management



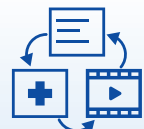Procedure
Recording



Medical Content
Management



Video
Editing



HIS, VNA and
PACS Integration

For more information please visit

www.olympus.eu/contentmanagement

How I Do It: Right Colectomy with the Da Vinci Xi Robotic Platform

Jan Grosek

*Department of Abdominal Surgery, Ljubljana University Medical Center
Medical Faculty, University of Ljubljana*

CORRESPONDENCE

Asst. Prof. **Jan Grosek**, MD, PhD
jan.grosek@kclj.si

KEY WORDS

da Vinci Xi system, right colectomy, indocyanine green fluorescence

How I Do It

SURGERY SURG ENDOS 2020; 2(2):
61-68

Abstract

Radical surgery is the mainstay for treating colon cancer. A minimally invasive approach is the gold standard for many surgical procedures. Robotic colectomy addresses the limitations of straight laparoscopic colon resections. However, there are some key differences in setup and positioning that may affect anesthetic protocols. Hence, anesthesiologists should be involved in the planning process. This article reports a technique for single-docking totally robotic right colectomy for cecal adenocarcinoma using the da Vinci Xi Surgical System (Intuitive Surgical, USA). To date, the technique reported here has proven to be very successful.

Introduction

The robotic platform offers many advantages over standard laparoscopy, including better visualization (a stable 3D view and magnification), precise dissection and tissue manipulation, and improved ergonomics, potentially reducing fatigue of the operating surgeon (1).

The da Vinci Xi robotic platform allows a surgeon to perform single-docking multi-quadrant surgery and, through the integrated Firefly system, makes possible near-infrared indocyanine green (ICG) fluorescence, which can be a very valuable tool for intraoperative decision-making in minimally invasive surgery (2). Intraoperative fluorescence angiography delivers very important visual cues regarding bowel perfusion, thus helping the surgeon determine where to transect the bowel wall (3–5). The author's team routinely uses this technology to assess bowel perfusion in all robotic colorectal resections.

Preoperative Preparation

Patients undergo standard preoperative workup and preparation, which is the same as for conventional laparoscopic or even open colectomy, in line with institutional practice at the department. This includes full colonoscopy (partial in the case of obstructive carcinoma) and contrast-enhanced computed tomography (CT) of the chest and abdomen. Every patient is discussed at the multi-disciplinary tumor team board. The bowel is prepared with a single enema, and tumor marking is performed with India ink under colonoscopic vision > 48 hours before surgery.

Positioning of Patients and Ports

Efficiency of all robotic resections relies on correct patient setup and positioning, coupled with proper port setup. The patient is secured on special non-slip foam, with arms tucked at the side, legs extended, and secured by wrapping circumferentially with a roller bandage. It is of outmost importance to prevent any unwanted patient movement.

A nasogastric tube is placed for gastric decompression and a Foley catheter for urinary bladder decompression. The robotic cart is docked at the right side of the patient, who is positioned in a left side tilt and slight Trendelenburg position. Four 8

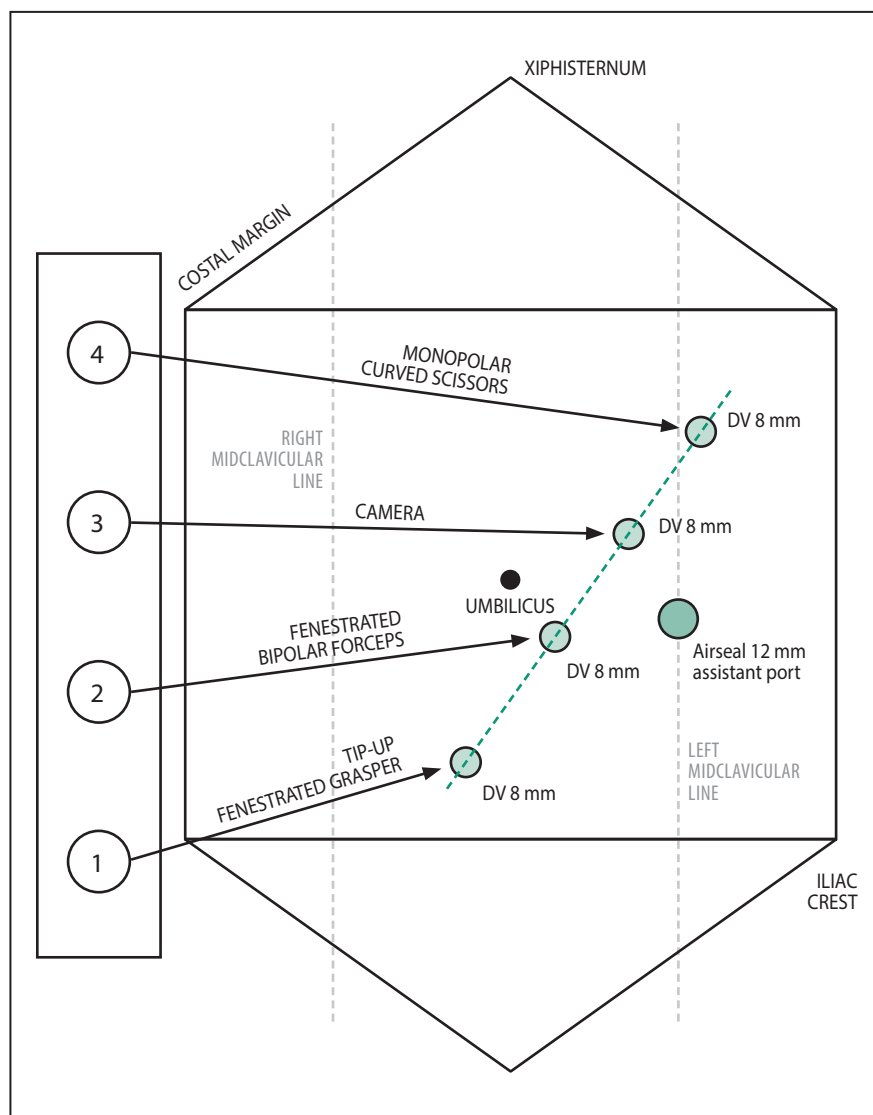


Figure 1. Docking and port configuration, and type of robotic instruments used for the procedure.

mm robotic ports (DV 8 mm) are placed diagonally, preferably all of them lying along an imaginary linear line. We employ configuration of two-left handed instruments and one right-handed instrument; the endoscope (30-degree optics) is placed in robotic port number two. An Airseal^R (Applied Medical, USA) 12 mm port is inserted in the left upper quadrant; its valveless trocar design provides for high-flow insufflation and facilitates smoke evacuation. Moreover, it allows the assistant unimpeded introduction of laparoscopic instruments for grasping, suction, and introduction and removal of clips, needles, sutures, or endoscopic staplers (Figure 1).

Operative Steps

Preoperative antibiotics are given to cover the intestinal flora and the abdomen is prepped in a standard sterile fashion. A Verres needle is typically used for the insufflation. Laparoscopy is performed first, sweeping the small intestine away from the target anatomy and placing the omentum above the transverse colon. This is facilitated by tilting the operating table. The tumor is localized under standard white light. Once the duodenum and ileocolic pedicle are properly exposed (Figure 2), the robot is docked, and all the instruments are inserted.

A medial to lateral approach is utilized, and the embryological fusion plane between the right colonic mesentery and retroperitoneum is en-

tered. The dissection is blunt, done with vertical (up-down) sweeping movements, facilitated by pneumoperitoneum. The duodenum must be recognized at all times and swept posteriorly. Thereafter the ileocolic pedicle is transected between clips (Figure 3). The medial to lateral dissection is continued toward the hepatic flexure between Toldt's fascia and Gerota's fascia. The right branch of the middle colic artery is transected just above the pancreatic head (Figures 4a, 4b). The omentum is grasped and divided, and dissection is preferably initiated at the location at which the falciform ligament crosses the transverse colon. The gastrocolic ligament is divided as well as the ileal mesentery (Figure 5) and mesocolon of the transverse colon (Figure 6) using Vessel Sealer. Prior to bowel transection, 5 ml of ICG (25 mg / 10 ml) is administered intravenously, and using the integrated Firefly system bowel perfusion is assessed by near-infrared fluorescence (Figures 7, 8). Thereafter, the ileum and transverse colon are transected by a 60 mm blue cartridge linear stapler and the resection part of the operation is continued by dissection toward the hepatic flexure, dividing the remaining hepato-colic attachments (Figure 9) and completely mobilizing the right colon and coecum laterally. The specimen is temporarily displaced cranially on top of the liver. A side-to-side isoperistaltic ileocolic anastomosis is performed intracorporeally by a 60 mm linear stapler blue cartridge (Figure 10) and the enterotomy is closed with a double-layer 4.0 monofilament absorbable suture, the first layer being running and the second interrupted (Figure 11). A second injection of ICG (5 ml, 25 mg / 10 ml) is

Figure 2. Exposition of the ileocolic pedicle.

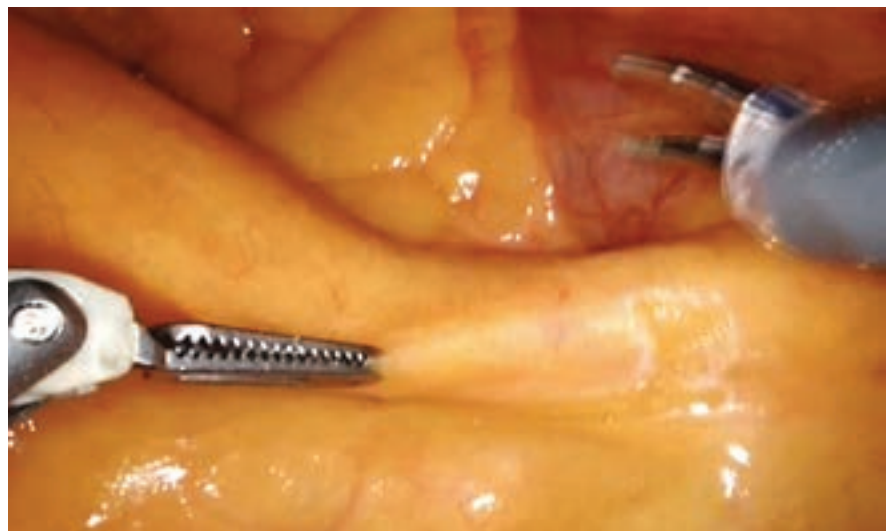

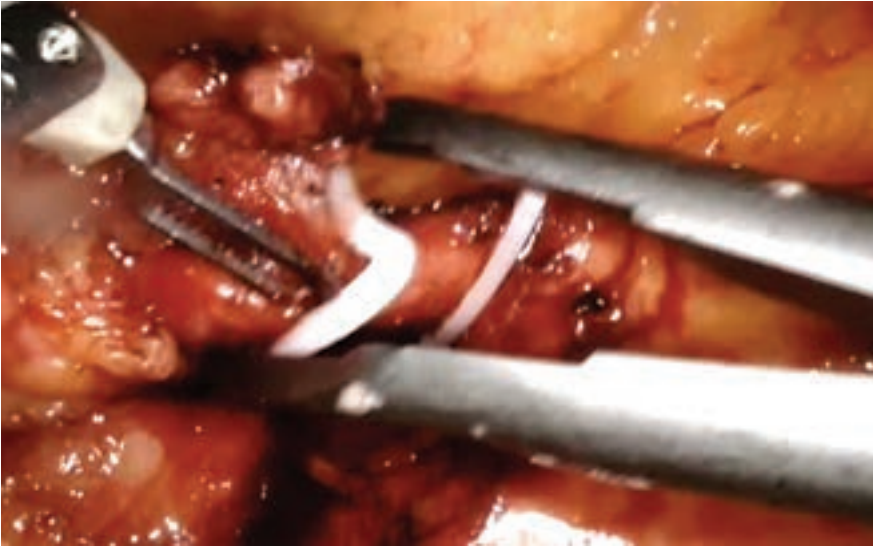


Figure 3. High vascular ligation.

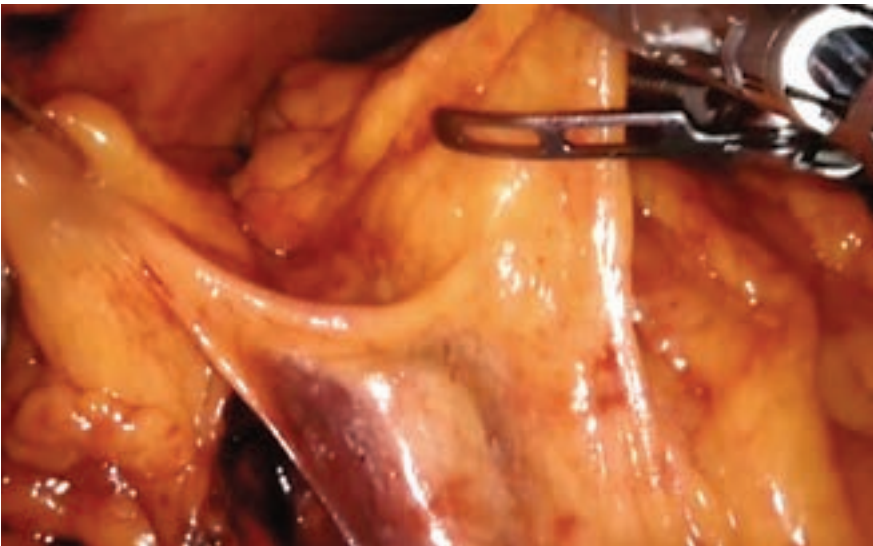


Figure 4a, 4b. Dissection of the right branch of the middle colic artery.

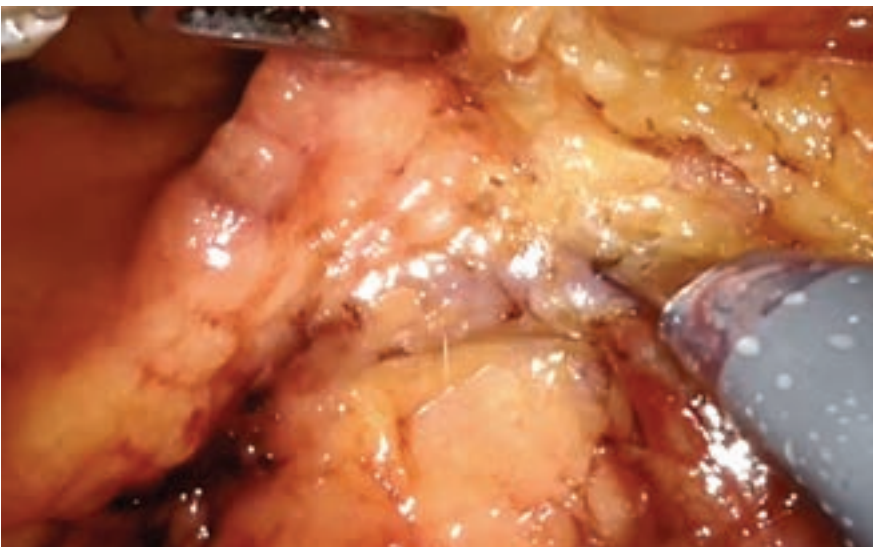


Figure 5. Transecting the ileal mesentery.

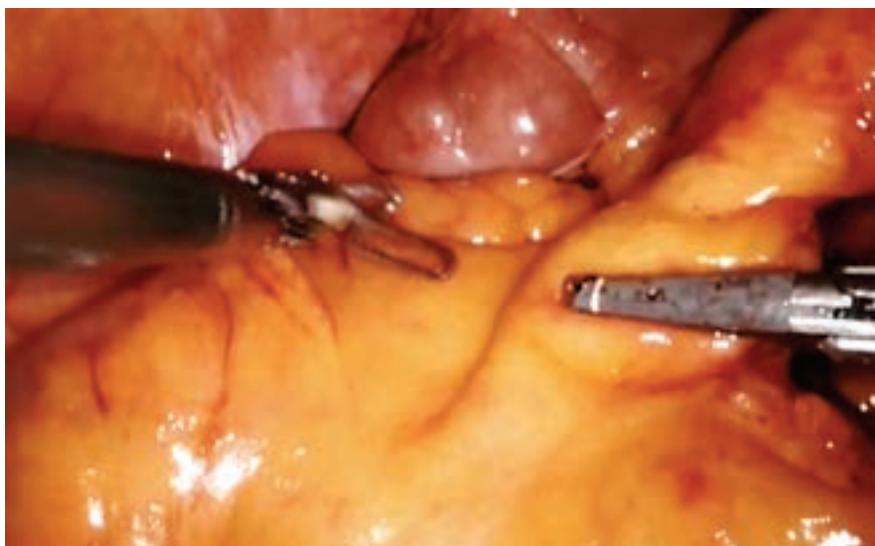

Figure 6. Transecting the transverse mesocolon.

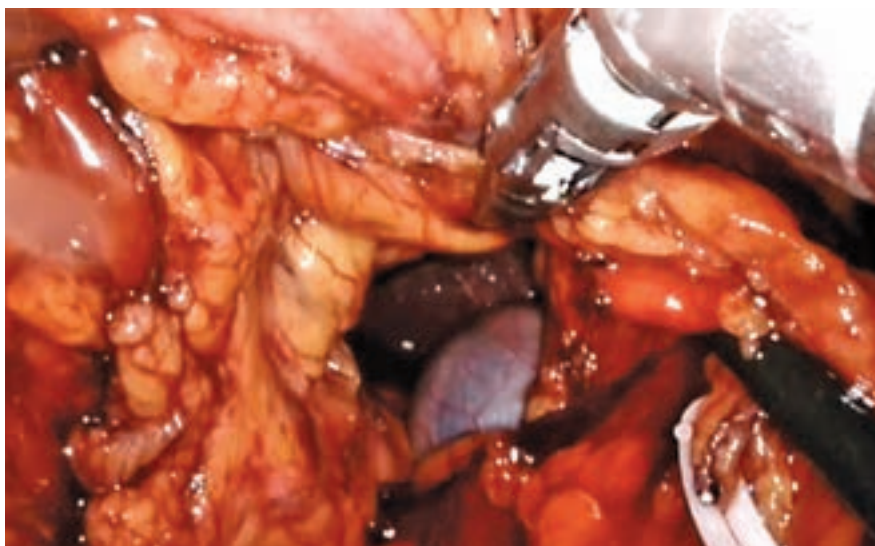
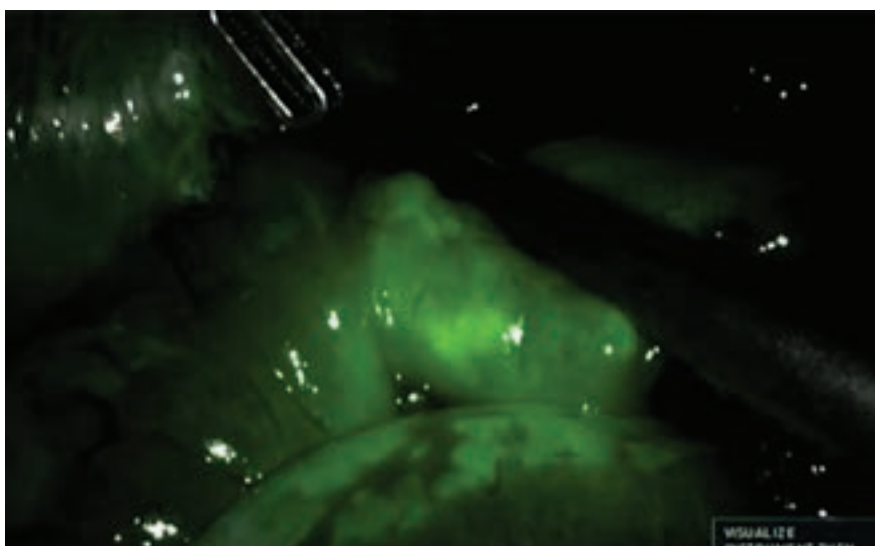


Figure 7. Indocyanine green angiography of the ileum.



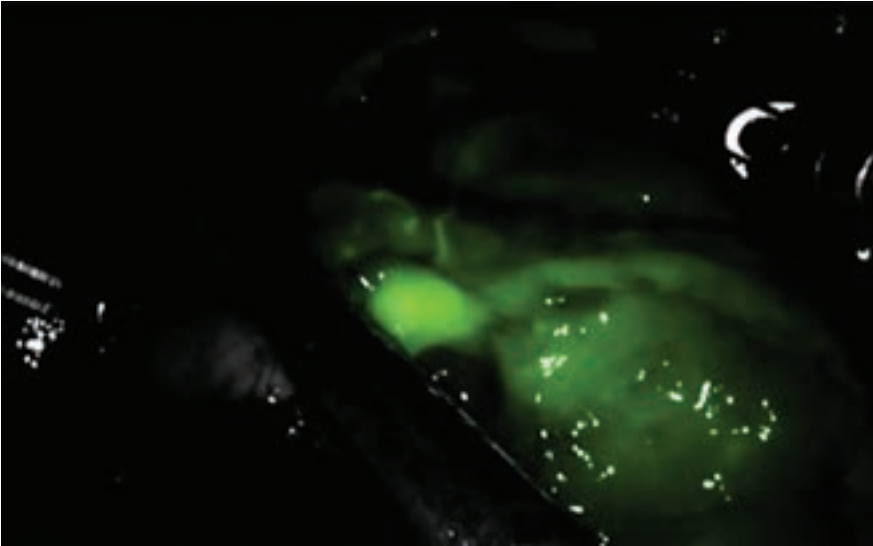


Figure 8. Indocyanine green angiography of the transverse colon.

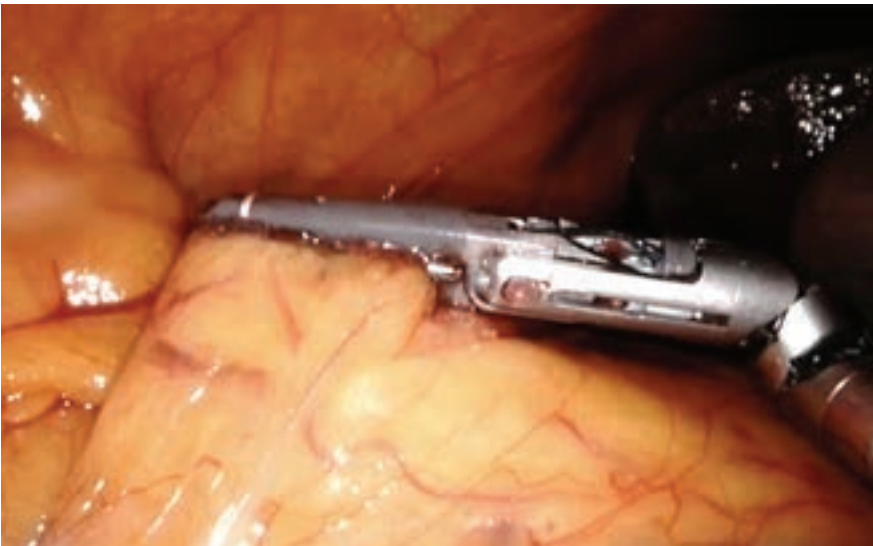

Figure 9. Hepatic flexure take-down.

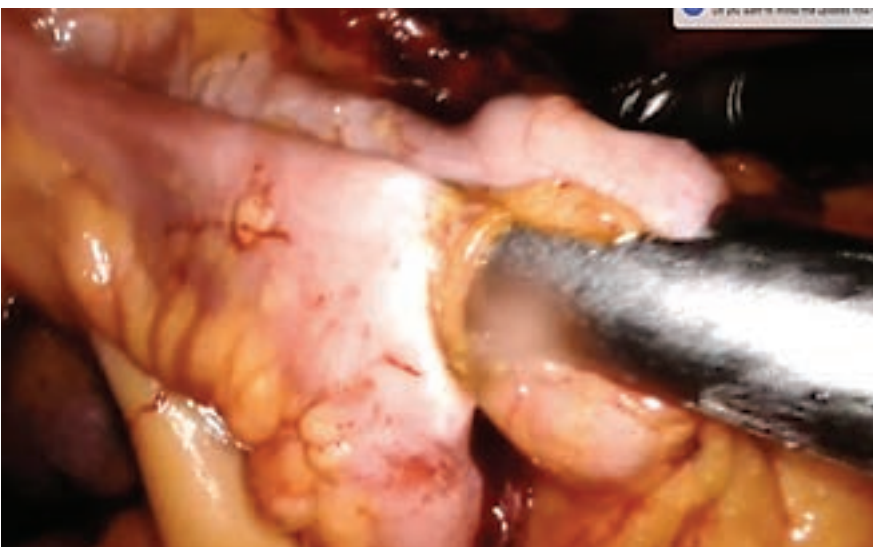

Figure 10. Side-to-side anastomosis.

Figure 11. Suturing the enterotomy in two layers.

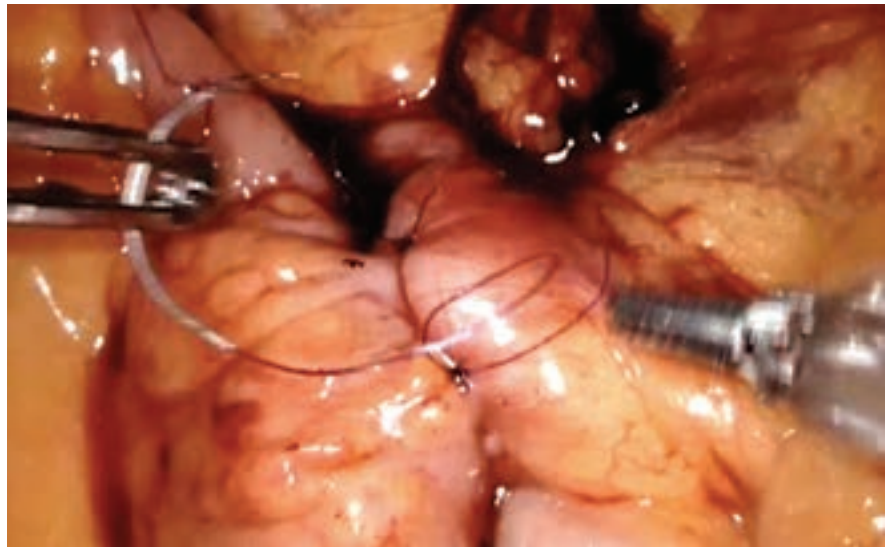

Figure 12. Insertion of wound-protector.

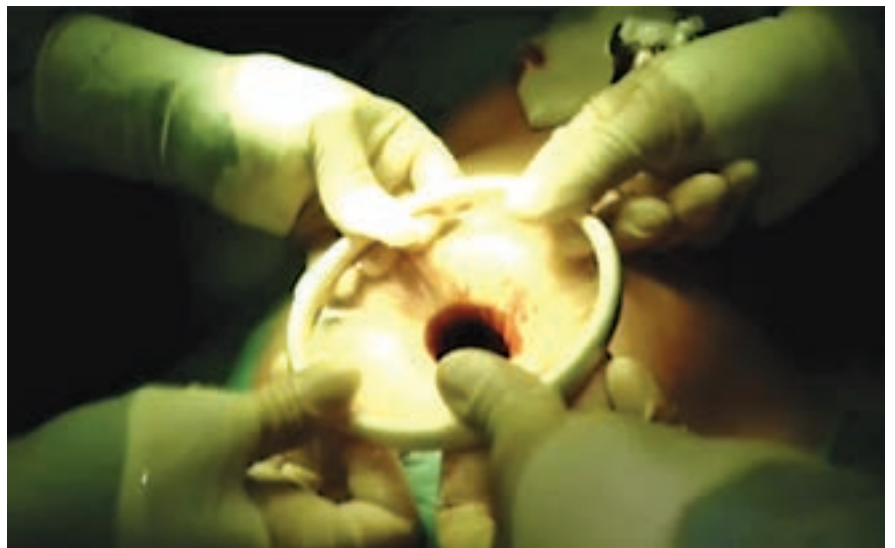
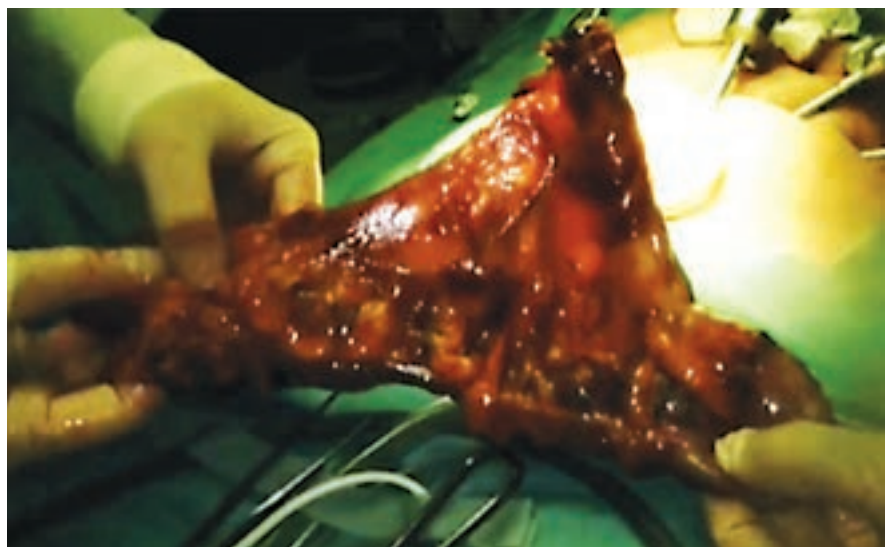
Figure 13. The specimen extracted.



administered intravenously to confirm the anastomotic perfusion. The gap in the mesentery is closed with a running absorbable 3.0 barbed suture. A small Pfannenstiel incision is made, incorporating incision of robotic port (DV) number one, and a wound-protector is inserted (Figure 12). This allows for safe extraction of the colonic specimen (Figure 13). Subsequently, laparoscopy is performed, confirming hemostasis and proper positioning of the drainage tube.

Postoperative Care

Early and frequent mobility is encouraged, and venous thromboembolism prophylaxis is started approximately 12 hours after the operation. The nasogastric tube is removed prior to the end of the operation, and the drainage tube and Foley catheter are removed on postoperative day 1. Patients are offered clear liquids in the evening on the day of the operation. In the absence of nausea, vomiting, or abdominal discomfort, they are quickly advanced from a liquid diet to a regular diet. In general, patients are discharged on postoperative day 5 or 6.

Conclusions

Our team started using the da Vinci Xi robotic platform in January 2020. Since then, we have performed 40 colorectal resections, 22 of which were right colectomies. To date, the technique reported here has proved to be very successful. There have been no major complications or arm collisions related to this technique and also no non-recoverable faults with this technique of docking, port positioning, or instrument placement. Moreover, there has been no postoperative morbidity requiring reoperations (anastomotic leakage, hemorrhage, etc.). All resections have been curative (R0), with an average length of stay of 5 to 6 days. So far there have been no conversions to open procedure. Adherence to key technical principles (medial to lateral mobilization, respecting the embryological planes, and high vascular ligation) are critical for a successful operation. Robotic technology is complex, and all the operating room personnel should be well trained. Anesthesia personnel should be involved in the planning process, and considera-

tion should be given to preparing for the possibility of conversion to an open approach from a robotic approach.

References

1. Wee IJY, Kuo LJ, Ngu JCY. A systematic review of the true benefits of robotic surgery: ergonomics. *Int J Med Robotics Comput Assist Surg.* 2020;16(4):e2113.
2. Grosek J, Tomažič A. Key clinical applications for indocyanine green fluorescence imaging in minimally invasive colorectal surgery. *J Min Access Surg.* 2019;16(4):308–14.
3. Anuradha R, Bhama MD, Robert K, et al. Set up and positioning in robotic colorectal surgery. *Semin Colon Rectal Surg.* 2016;27(3):130–3.
4. Waters JA, Francone TD. Robotic approach to colon resection. *Semin Colon Rectal Surg.* 2016;27(3):136–43.
5. Addison P, Agnew JL, Martz J. Robotic colorectal surgery. *Surg Clin N Am.* 2020;100(2):337–60.

3DMAX™ Light Mesh



Unique:

- 3D shape developed by a laparoscopic surgeon.
- Designed to conform to the inguinal anatomy.
- Contour minimizes buckling that may be seen with flat mesh.
- Design may reduce the need for fixation.

Precise:

- Sealed edge and medial orientation marker facilitate accurate placement and positioning.
- Built-in memory maintains shape.

Lighter Weight:

- Lighter-weight monofilament polypropylene mesh.
- Large pore knit provides excellent visibility.
- Animal study data demonstrated the formation of a flexible and compliant abdominal wall.¹

¹ Data on file. Results may not correlate to performance in humans.

See laparoscopic inguinal hernia repair in a whole new light.

The unique shape of 3DMAX™ Light Mesh was developed by a laparoscopic surgeon to conform to the inguinal anatomy and meet the specific challenges of laparoscopic hernia repair. The three-dimensional shape, sealed edge and medial orientation marker allow for easier positioning than conventional flat mesh and also enhance the speed and simplicity of placement. This lighter-weight version of our popular 3DMAX™ Mesh features a large pore knit. It is easy to deploy and provides excellent visibility. Animal study data demonstrated the formation of a flexible and compliant abdominal wall.¹



3DMAX™ Light Mesh is designed to conform to the inguinal anatomy and retain its shape following laparoscopic introduction.

BAIRD
DAVOL INC.

TECHNOLOGY
TECHNIQUE
TRAINING
TRUST

Instructions for Authors

Surgery and Surgical Endoscopy is the official journal of the Slovenian Society of Endoscopic Surgery. It is a multidisciplinary journal devoted to publishing original and high-quality scientific papers, pertinent to surgery, surgical oncology as well as surgical endoscopy.

The Editorial Board requires that the paper has not been published or submitted for publication elsewhere. The authors are responsible for all statements in their papers. Accepted articles become the property of the journal and, therefore, should not be published elsewhere without the written permission of the editors.

1. SUBMISSION OF THE MANUSCRIPT

The journal accepts *review articles, research articles, case reports, letters to the editors, study protocols* and “*How I do it*” submissions.

The manuscript written in English should be submitted to Editors-in-Chief, Tomaž Jagrič or Jan Grosek (tomaz.jagric@gmail.com; jangrosek@gmail.com).

All articles are subjected to the editorial review. The editorial board reserves the right to ask authors to make appropriate changes of the contents as well as grammatical and stylistic corrections when necessary.

Articles are published printed and on-line as the open access (www.zeks.si/journal). There is no publication fee.

When manuscripts are submitted under multiple authorship, it is the corresponding author who has the authority to act on behalf of all the authors in all matters pertaining to publication. Submitted manuscripts are reviewed by the editorial board on the assumption that all listed authors concur in the submission and are responsible for its content.

2. PREPARATION OF MANUSCRIPTS

The manuscript should be submitted as .doc or .docx file. It should be written in grammatically and stylistically correct language. Abbreviations should be avoided. If their use is necessary, they should be explained when first mentioned in the text. The chapter headings should not contain abbreviations. The technical data should conform to the SI system. Each section should be started on a new page, and each page should be numbered consecutively with Arabic numerals.

The Title page should include a concise and informative title, followed by the full name(s) of the author(s); the institutional affiliation of each author; the name and address of the corresponding author (including telephone, fax and E-mail). Authors should be qualified for authorship. They should contribute to the conception, design, analysis and interpretation of data, and they should approve the final version of the contribution.

This should be followed by the abstract page, summarizing in less than 250 words the reasons for the study, experimental approach, the major findings (with specific data if possible), and the principal conclusions. Three to six key words should

be provided for indexing purposes. Structured abstracts are required for research articles only.

Review Articles

The Editorial Board encourages submission of review articles on topics of current interest. The manuscript should be restricted to 5000 words and up to 50 references. An abstract of no more than 250 words and up to six key words should be provided.

Research Articles

The abstract of the research article should be structured (Background, Methods, Results, Conclusions) and of no more than 250 words (Slovenian language abstracts are limited to 400 words).

Research article should be structured as well, divided into sections: Introduction, Methods, Results and Discussion. Manuscript should be restricted to 4000 words.

Introduction should summarize the rationale for the study or observation, citing only the essential references and stating the aim of the study.

Materials and methods should provide enough information to enable experiments to be repeated. New methods should be described in detail.

Results should be presented clearly and concisely without repeating the data in the figures and tables. Emphasis should be on clear and precise presentation of results and their significance in relation to the aim of the investigation.

Discussion should explain the results rather than simply repeating them as well as interpret their significance and draw conclusions. It should discuss the results of the study in the light of previously published work.

Case Reports

This section presents reports on rare or otherwise interesting case report or case series. Articles must be authentic, ethical, educational and clinically interesting to an international audience of surgeons, trainees and researchers in all surgical subspecialties, as well as clinicians in related fields.

The manuscript should be in the format:

- Introduction
- Case report/case presentation
- Discussion

Submissions to this section should carry no more than 2500 words, two figures and 20 references. An unstructured abstract of up to 200 words and six key words should be provided.

Letters to the Editor

Comment on papers recently published in the Journal. The letters should be restricted to up to 500 words and three references and should not carry any figures.

Study Protocol

Study protocol articles can be for proposed or ongoing prospective clinical research, and should provide a detailed account of the hypothesis, rationale and methodology of the study. Study protocols for pilot or feasibility studies will be treated on a case by case basis. Study protocols without ethics approval will generally not be considered. The manuscript should be structured the same way as a research article.

How I Do It?

Submissions to this section should provide description of a well-established procedure focussing on its technical aspects. The manuscript should be in the format:

- Introduction
- Preoperative preparation
- Operative steps
- Postoperative care

The operative steps should be illustrated with high-quality figures. The manuscript should be restricted to 1500 words, a 150-word abstract, six key words and may carry up to 10 figures and 10 references.

3. DECLARATIONS

All manuscripts must contain the following sections under the heading "Declarations".

- Ethics approval and consent to participate
- Consent for publication
- Competing interests
- Authors contributions
- Funding
- Acknowledgements

If any of the sections are not relevant to your manuscript, please include the heading and write "Not applicable" for that section.

a) Ethics approval and consent to participate

Manuscripts reporting studies involving human participants, human data or human tissue must:

- include a statement on ethics approval and consent (even where the need for approval was waived), and
- include the name of the ethics committee that approved the study and the committee's reference number if appropriate.

Studies involving animals must include a statement on ethics approval. If your manuscript does not report on or involve the use of any animal or human data or tissue, please state "Not applicable" in this section.

b) Consent for publication

If your manuscript contains any individual person's data in any form (including any individual details, images or videos), consent for publication must be obtained from that person, or in the case of children, their parent or legal guardian. All presentations of case reports must have consent for publication. You should not send the form to us on submission, but we may request to see a copy at any stage (including after publication). If your manuscript does not contain data from any individual person, please state "Not applicable" in this section.

4. REFERENCES

References must be numbered in the order in which they appear in the text and their corresponding numbers quoted in the text. Authors are responsible for the accuracy of their references. References to the Abstracts and Letters to the Editor must be identified as such. Citation of papers in preparation or submitted for publication, unpublished observations, and personal communications should not be included in the reference list. If essential, such material may be incorporated in the appropriate place in the text. References follow the style of Index Medicus, DOI number (if exists) should be included. All authors should be listed when their number does not exceed six; when there are seven or more authors, the first six listed are followed by "et al.". The following are some examples of references from articles, books and book chapters:

1. Dent RAG, Cole P. In vitro maturation of monocytes in squamous carcinoma of the lung. *Br J Cancer* 1981; 43: 486–95. doi:10.1038/bjc.1981.71
2. Chapman S, Nakielny R. A guide to radiological procedures. London: Bailliere Tindall; 1986.
3. Evans R, Alexander P. Mechanisms of extracellular killing of nucleated mammalian cells by macrophages. In: Nelson DS, editor. *Immunobiology of macrophage*. New York: Academic Press; 1976. p. 45–74.

5. CHARTS, ILLUSTRATIONS, IMAGES AND TABLES

Charts, Illustrations, Images and Tables must be numbered and referred to in the text, with the appropriate location indicated. Each of them should contain a title and an explanation of all the abbreviations and non-standard units used. Charts, Illustrations and Images, provided electronically, should be of appropriate quality for good reproduction and should be submitted as separate files. Illustrations and charts must be vector image, created in CMYK colour space, preferred font "Century Gothic", and saved as .AI, .EPS or .PDF format. Colour charts, illustrations and Images are encouraged, and are published without additional charge. Image size must be 2.000 pixels on the longer side and saved as .JPG (maximum quality) format. In Images, the identities of the patients should be masked. Tables should be typed double-spaced. The files with the figures and tables can be uploaded as separate files.

6. PAGE PROOFS

Page proofs will be sent by E-mail to the corresponding author. It is their responsibility to check the proofs carefully and return a list of essential corrections to the editorial office within three days of receipt. Only grammatical corrections are acceptable at that time.

7. OPEN ACCESS

Papers are published electronically as open access on www.zeks.si/journal.

